

INVISALIGN GALLERY
&
UNIVERSITY CHALLENGE

2014

INVISALIGN GALLERY & UNIVERSITY CHALLENGE 2014



ALIGN TECHNOLOGY, INC.
2560 ORCHARD PARKWAY, SAN JOSE, CA 95131
WWW.INVISALIGN.COM



2014 INVISALIGN GALLERY

Library of Congress Cataloging-in-Publication Data

Invisalign® Gallery & University Challenge 2014/Edited by Dr. Eric Kuo

p. cm.
Includes index.

ISBN-10: 0692585184

ISBN-13: 978-0-692-58518-4

1. Orthodontics, Corrective 2. Orthodontic Appliances

I. Align Technology, Inc.

©2014 Align Technology, Inc. All rights reserved.

Published by Align Technology Inc., San Jose, CA

This book contains material protected under International and Federal Copyright Laws and Treaties. Any unauthorized reprint or use of this material is prohibited. No part of this book may be reproduced or transmitted in any form or by any means, electronic or mechanical, including photocopying, recording, or by any information storage and retrieval system without express written permission from the publisher. Requests to the Publisher for permission should be addressed to Align Technology, Inc., RE: Invisalign Gallery, 2560 Orchard Parkway, San Jose, CA 95131 or via email to: InvisalignGallery@aligntech.com.

All trademarks and registered trademarks are the property of their respective owners.

The views and opinions of the contributors to the University Challenge do not necessarily state or reflect those of their respective universities, nor do they constitute endorsement by the universities of the information, products, or services contained herein.

Limit of Liability/Disclaimer of Warranty. While the publisher and editor have used their best efforts in preparing this book, they make no representations or warranties with respect to the accuracy or completeness of the contents of this book and specifically disclaim any implied warranties, appropriateness, or fitness for a particular purpose. The strategies contained herein may not be suitable for your situation and should not be construed as medical advice. The publisher is not engaged in the business of rendering dental treatment, so a dental professional should always be consulted where appropriate. Neither the publisher nor the editor shall be liable for any loss of profit or other damages, including but not limited to special, incidental, consequential, or other damages.

Printed in the United States of America

TABLE OF CONTENTS

INTRODUCTION.....	vii
CLINICAL CONTRIBUTORS	viii
CLASS I TREATMENTS	
Dr. Gary Brigham	2
Dr. Charles Brodsky	4
Dr. Doug Crosby.....	6
Dr. James Crouse.....	8
Dr. Mark Garlington	10
Drs. Stanley and Scott Gersch	12
Dr. William Grieve	14
Dr. William Heintz	16
Dr. William Heintz	18
Dr. Sean Holliday.....	20
Dr. Lindsay Jackfert	22
Dr. Paul Kasrovi.....	24
Dr. Steven Luccarelli	26
Dr. Michelle Fogg Neal.....	28
Dr. Jonathan Nicozisis	30
Dr. Jonathan Nicozisis	32
Dr. Bradley Nirenblatt.....	34
Drs. Robert and James Passamano	36
Dr. Luis Piedade	38
Dr. Kurt Silberstein	40
Dr. Kurt Silberstein	42
Dr. Manuel Sousa	44
Dr. John Sparaga.....	46
Dr. John Sparaga.....	48
Dr. Jason Tam	50
Dr. Samie Thabet	52
CLASS II TREATMENTS	
Dr. Nahal Ashouri.....	56
Dr. Patricia Bendick	58
Dr. Bartley Benson.....	60
Dr. Sujata Bhatia	62
Dr. Sujata Bhatia	64
Dr. Charles Brodsky	66

TABLE OF CONTENTS

CLASS II TREATMENTS CONTINUED

Dr. Joseph Ciccio..... 68

Dr. Dustin Coles..... 70

Dr. Dustin Coles..... 72

Dr. Linda Crawford 74

Dr. Linda Crawford 76

Dr. James Crouse..... 78

Dr. Chunni Duan 80

Dr. Tarek El-Bialy 82

Dr. Robert Elliott..... 84

Dr. Donna Galante..... 86

Dr. Jose Luis Garcia..... 88

Dr. Bella Shen Garnett..... 90

Dr. Bella Shen Garnett..... 92

Dr. Barry Glaser..... 94

Dr. Barry Glaser..... 96

Dr. Ira Goldberg..... 98

Dr. Jasmine Gorton 100

Dr. Sean Holliday..... 102

Dr. Sean Holliday..... 104

Dr. Kraig Kottemann 106

Dr. Edwin Lee 108

Dr. Mark Lowe 110

Dr. Ramtin Nassiri 112

Dr. Michelle Fogg Neal..... 114

Dr. Bradley Nirenblatt..... 116

Dr. Bradley Nirenblatt..... 118

Drs. Robert and James Passamano 120

Drs. Robert and James Passamano 122

Dr. Luis Piedade..... 124

Dr. Gregory Ross 126

Dr. Vishal Sharma 128

Dr. Kurt Silberstein 130

Dr. John Sparaga..... 132

Dr. John Sparaga..... 134

Dr. Sandra Tai..... 136

Dr. Samie Thabet..... 138

Dr. Maureen Valley 140

Dr. Jenny Zhu 142

Dr. Ray Zoka..... 144

TABLE OF CONTENTS

CLASS III TREATMENTS

Dr. Nahal Ashouri..... 148

Dr. Vijay Bhagia..... 150

Dr. Gary Brigham 152

Dr. Terry Carlyle 154

Dr. Chunni Duan 156

Dr. Donna Galante..... 158

Dr. Bella Shen Garnett..... 160

Dr. Barry Glaser..... 162

Dr. Jasmine Gorton 164

Dr. Dudley Hodgkins 166

Dr. Laura Low 168

Dr. Tom Lowder 170

Dr. Luis Piedade..... 172

Dr. Kenyu Takamoto..... 174

ALPHABETICAL INDEX..... 176

TEEN TREATMENT INDEX 177

TREATMENT PLAN INDEX..... 178

VISUAL INDEX 180

2014 CLINICAL REVIEW COMMITTEE 186

2014 AWARD RECIPIENTS 187

METHODOLOGY 188

2014 UNIVERSITY CHALLENGE 191

2014 INVISALIGN GALLERY & UNIVERSITY CHALLENGE TEAM 254

INTRODUCTION

The Invisalign® Gallery was first published in 2010 to celebrate the success of North American clinicians who used Invisalign aligners across a broad range of orthodontic problems. From 2010 to 2014, a total of 435 treatments from 174 different doctors have been showcased in this publication. This year’s edition also includes a University Challenge competition section consisting of 24 entries from 15 orthodontic residency programs in North America.

The Invisalign Gallery cases are just a small fraction of the more than 3 million patients treated with Invisalign to date, but the entire collection effectively demonstrates the growing scope of what is clinically possible. As the innovation built into Invisalign treatment continues to expand, successful treatments of Class II and Class III malocclusions, moderate to severe crowding and spacing, and open bites and deep bites are becoming more and more common in both teens and adults. Doctors are also effectively using multiple extractions, orthodontic auxiliaries such as elastics and TADs, orthognathic surgery, and complex restorative plans to achieve their desired outcomes with Invisalign, and the momentum is expected to continue as patient demand continues to grow.

All of this suggests that for many doctors, Invisalign aligners are no longer the novel, aesthetic orthodontic appliance for minor tooth movement they were once thought to be, but a viable option for even some of the most complicated malocclusions. So, to everyone who has shared their clinical experiences and expertise in the Invisalign Gallery these past five years, thank you for your

insights and for moving Invisalign treatment forward. Not only have your patients benefited from your efforts, you have inspired and challenged countless others with your success, and orthodontics as a whole has advanced significantly because of your work.

I am also very pleased to announce that Dr. Mitra Derakhshan has been selected as the new editor of the Invisalign Gallery publication. Dr. Derakhshan has successfully managed the International Invisalign Gallery since its inception, and she also practices orthodontics part-time, so clinical efficacy and treatment efficiency are both very important to her. She envisions a worldwide initiative and global digital gallery, where doctors across the entire globe can learn from each other and excel even higher. We look forward to her leadership in the next chapter of the Invisalign Gallery program.



Dr. Eric Kuo
Editor, Invisalign Gallery 2014

CLINICAL CONTRIBUTORS

Dr. Nahal Ashouri
Nahal Ashouri, DDS, MS
Mountain View, CA
www.DrAshouri.com

Dr. Patricia Bendick
Fairfield Orthodontic Associates
Fairfield, CT
www.fairfieldorthodonticassociates.com

Dr. Bartley Benson
Benson Orthodontics
Mount Juliet, TN
www.bensonorthodontics.com

Dr. Vijay Bhagia
Space Center Orthodontics
Houston, TX
www.spacecenterortho.com

Dr. Sujata Bhatia
Kihei Orthodontics
Kihei, HI
www.kiheiorthodonticsmaui.com

Dr. Gary Brigham
Brigham Orthodontics
Scottsdale, AZ
www.drgbrigham.com

Dr. Charles Brodsky
Brodsky Orthodontics
Lakewood, CA
www.drbrodskysmile.com

Dr. Terry Carlyle
Strathcona Orthodontics
Edmonton, AB, Canada
www.str8teeth.com

Dr. Joseph Ciccio
Ciccio and Demarest Orthodontics
Bronxville, NY
www.nyorthodocs.com

Dr. Dustin Coles
Premier Orthodontics
Chandler, AZ
www.premierorthoaz.com

Dr. Linda Crawford
Beaux Sourires, PLLC
Dallas, TX
www.drlindacrawford.com

Dr. Doug Crosby
Douglas R. Crosby, DDS, MS
Richardson, TX
www.drdougrosby.com

Dr. James Crouse
James M. Crouse, DDS
Salisbury, MD
www.drcrousesbraceplace.com

Dr. Chunni Duan
Duan Orthodontics
Seattle, WA
www.duanorthodontics.com

Dr. Tarek El-Bialy
Sphinx Orthodontics
Edmonton, AB, Canada
www.sphinxorthodontics.com

Dr. Robert Elliott
Lo Elliott Orthodontics, Inc.
Prince George, BC, Canada
www.perfectsmile.ca

CLINICAL CONTRIBUTORS

Dr. Donna Galante
Cater Galante Orthodontics
Rocklin, CA
www.luvmysmile.com

Dr. Jose Luis Garcia
Braces By Garcia
Temecula, CA
www.bracesbygarcia.com

Dr. Mark Garlington
Mark A. Garlington, DDS
Long Beach, CA
www.drg4smiles.com

Dr. Bella Shen Garnett
Bella Smile
San Francisco, CA
www.bellasmile.com

Drs. Stanley and Scott Gersch
Gersch Orthodontics
Westfield, NJ
www.GerschOrtho.com

Dr. Barry Glaser
Glaser Orthodontics
Cortlandt Manor, NY
www.glaserorthodontics.com

Dr. Ira Goldberg
Goldberg Orthodontics
Roslyn, NY
www.goldbergortho.com

Dr. Jasmine Gorton
Gorton & Schmohl Orthodontics
Larkspur, CA
www.asmileisforever.net

Dr. William Grieve
Dr. W. Gray Grieve Orthodontics
Eugene, OR
www.coolorthodontist.com

Dr. William Heintz
Heintz Orthodontics
Alton, IL
www.drheintzorthodontics.com

Dr. Dudley M. Hodgkins
Hodgkins Orthodontics
Cedar Park, TX
www.10grin.com

Dr. Sean Holliday
Holliday Orthodontics
Pearl City, HI
www.dochollidaybraces.com

Dr. Lindsay Jackfert
Panucci and Jackfert Orthodontics
South Charleston, WV
www.panuccismiles.com

Dr. Paul Kasrovi
Berkeley Orthodontics
Berkeley, CA
www.berkeleyorthodontics.com

Dr. Kraig Kottemann
Kottemann Orthodontics
Maple Grove, MN
www.kottemannortho.com

Dr. Edwin Lee
Berman and Lee Orthodontics
Falls Church, VA
www.bermanandlee.com

CLINICAL CONTRIBUTORS

Dr. Laura Low
Clear Choice Orthodontics
Omaha, NE
www.yourstraightsmile.com

Dr. Tom Lowder
Lowder Orthodontics
Springdale, AR
www.lowderorthodontics.com

Dr. Mark Lowe
Mark Lowe, DDS
Fresno, CA
www.drloeweortho.com

Dr. Steven Luccarelli
Williston Orthodontics
Mineola, NY
www.longislandorthodontics.com

Dr. Ramtin Nassiri
Solano Smile Dental Specialty Group
Albany, CA
www.solanosmile.com

Dr. Michelle Fogg Neal
Michelle Fogg Neal, DDS
Kirkland, WA
www.nealsmiles.com

Dr. Jonathan Nicozisis
Princeton Orthodontics
Princeton, NJ
www.princetonorthodontics.net

Dr. Bradley Nirenblatt
Nirenblatt Orthodontics
Charleston, SC
www.drnnirenblatt.com

Drs. Robert and James Passamano
Passamano Orthodontics
Irvine, CA
www.youbraces.com

Dr. Luis Piedade
Ritebite Orthodontics
Waterloo, ON, Canada
www.ritebite.ca

Dr. Gregory Ross
Ross Orthodontics, Ltd.
Forest Lake, MN
www.rossodontics.com

Dr. Vishal Sharma
Aura Orthodontics
Surrey, BC, Canada
www.auraortho.com

Dr. Kurt Silberstein
Silberstein Orthodontics
Highland Park, IL
www.silbortho.com

Dr. Manuel Sousa
Salem Centre for Orthodontix
Salem, NH
www.smilenh.com

Dr. John Sparaga
Clear Smiles Alaska
Anchorage, AK
www.clearsmilesalaska.com

Dr. Sandra Tai
Dr. Sandra Tai, Inc.
Richmond, BC, Canada
www.drtai.com

CLINICAL CONTRIBUTORS

Dr. Kenyu Takamoto
Kenyu Takamoto, DDS, MSD
Bellevue, WA
www.drtakamoto.com

Dr. Jason Tam
MCO Orthodontics
Markham, ON, Canada
www.mcosmiles.com

Dr. Samie Thabet
Thabet Orthodontics
Germantown, MD
www.thabetorthodontics.com

Dr. Maureen Valley
Valley Orthodontics
San Rafael, CA
www.valleyorthodontics.net

Dr. Jenny Zhu
Manhattan Bridge Orthodontics
New York, NY
www.manhattanbridgeortho.com


Dr. Ray Zoka
Zoka Orthodontics
Camarillo, CA
www.drzoka.com

SPECIAL THANKS:

Dr. Clark Colville*
Orthodontic Specialists of Seguin
Seguin, TX
www.drcolville4braces.com

*Provided sample treatments to display
on www.SmileScore.com.

CLASS I TREATMENTS





Dr. Gary Brigham
Brigham Orthodontics
Scottsdale, AZ

www.drgbrigham.com

TREATMENT SUMMARY

PATIENT 12-year-old female

CHIEF CONCERN "The appearance of my teeth, because my teeth eye-teeth stick out."

DIAGNOSIS Right: Class I
Left: Class I

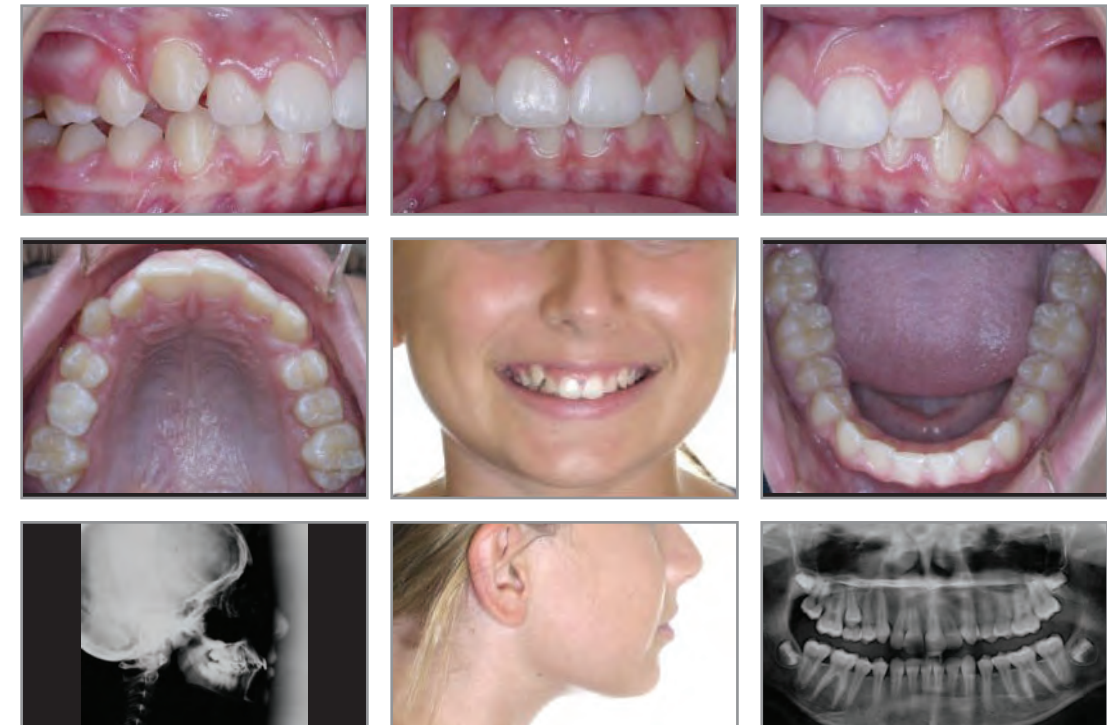Class I molars with Class II canines. Maxillary constriction, 60% overbite (deep bite), 1-2 mm overjet, and maxillary canines in supraocclusion, with steep interincisal angle.

LENGTH OF TREATMENT 28 months

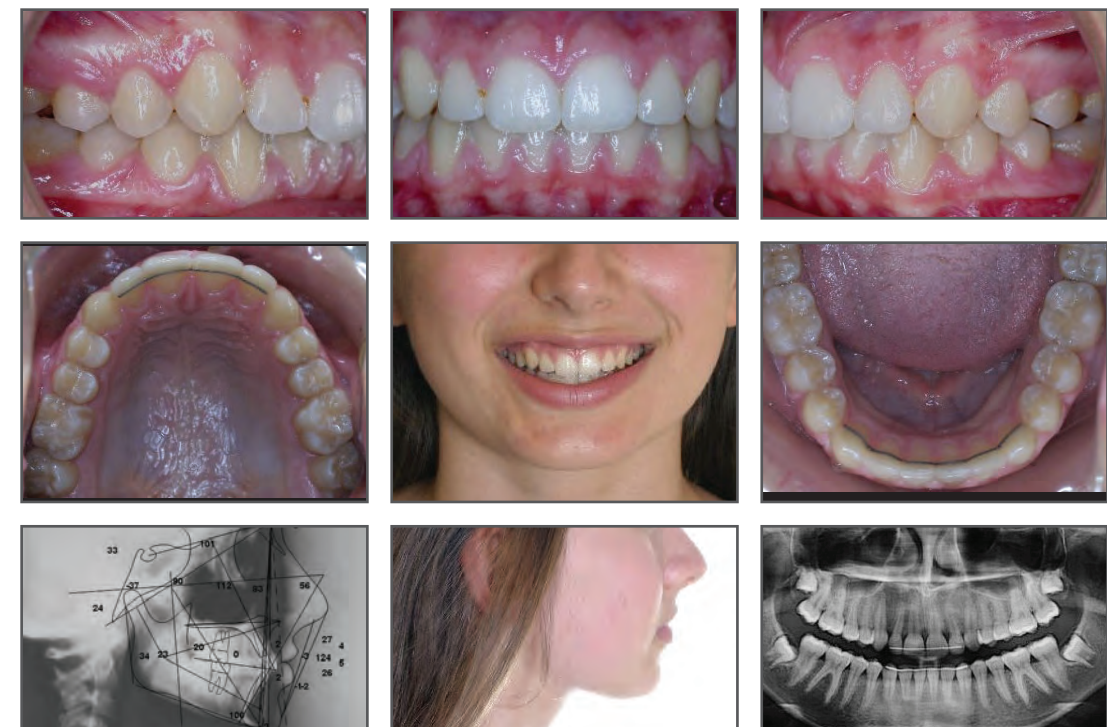
OF ALIGNERS USED Upper: 23 + 16
Lower: 16 + 9

ADDITIONAL TREATMENT Class II elastics (3/16" 4 oz.) were used for 16 months, with buttons from the upper canines to the mandibular first molars.

RETENTION Upper: Bonded lingual
Lower: Bonded lingual



BEFORE



AFTER



Dr. Charles Brodsky
Brodsky Orthodontics
Lakewood, CA

www.drbrodskysmile.com

TREATMENT SUMMARY

PATIENT 24-year-old male

CHIEF CONCERN The patient did not like how his teeth were protruded forward and quite crowded.

DIAGNOSIS
Right: Class I
Left: Class I

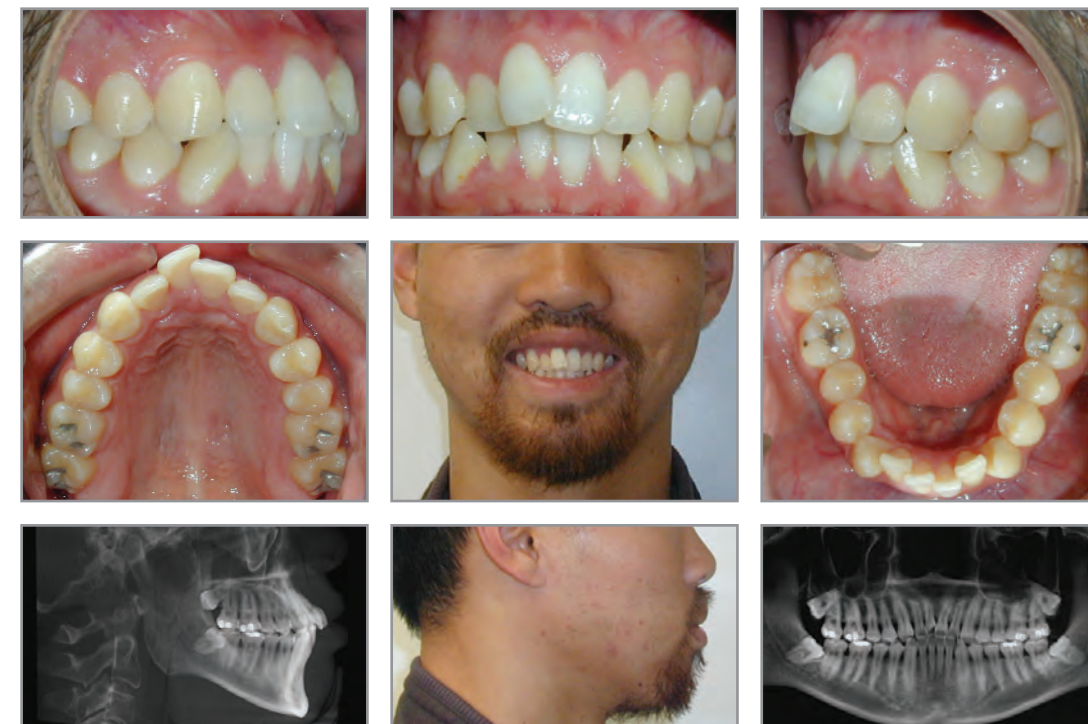Triangular-shaped arches, severe curve of Spee, with intruded maxillary incisors.
Moderate to severe crowding in both arches.

LENGTH OF TREATMENT 25 months

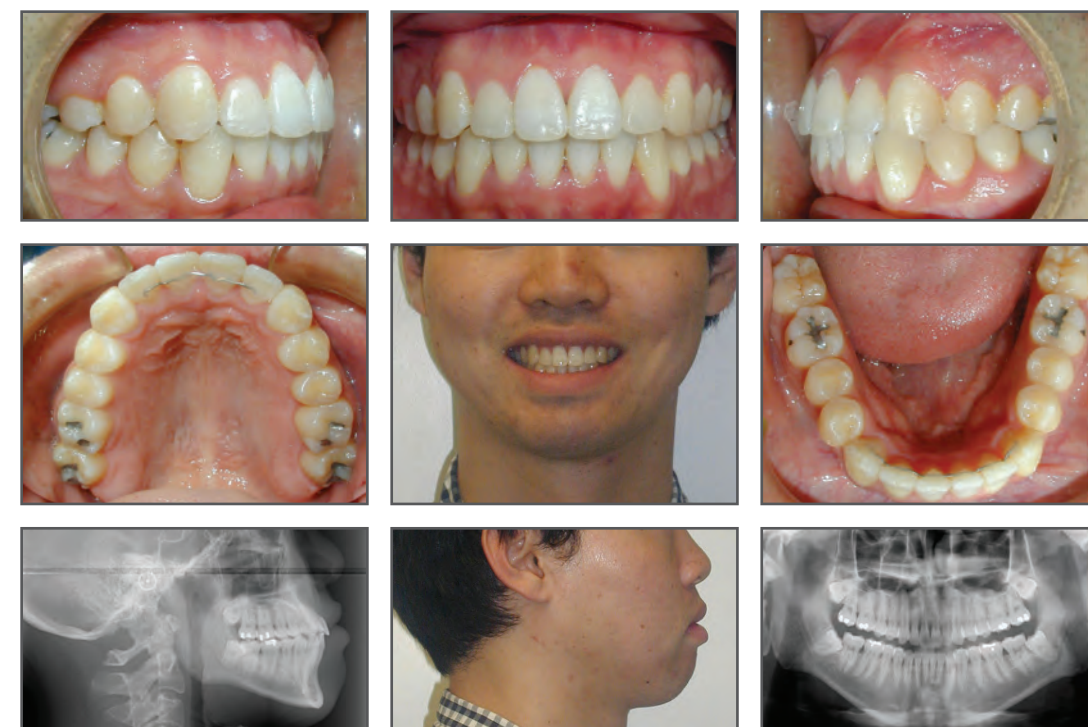
OF ALIGNERS USED
Upper: 23 + 14 + 13
Lower: 23 + 14 + 13

ADDITIONAL TREATMENT None

RETENTION
Upper: Essix® over bonded lingual
Lower: Essix® over bonded lingual



BEFORE



AFTER

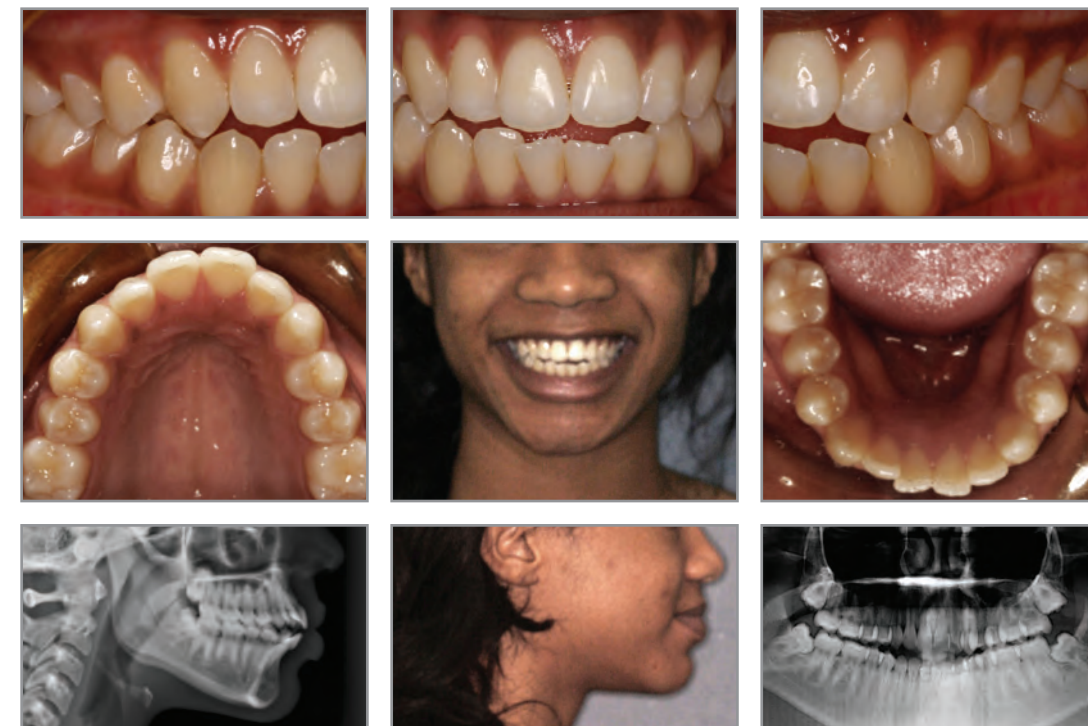


Dr. Doug Crosby
Douglas R. Crosby, DDS, MS
Richardson, TX

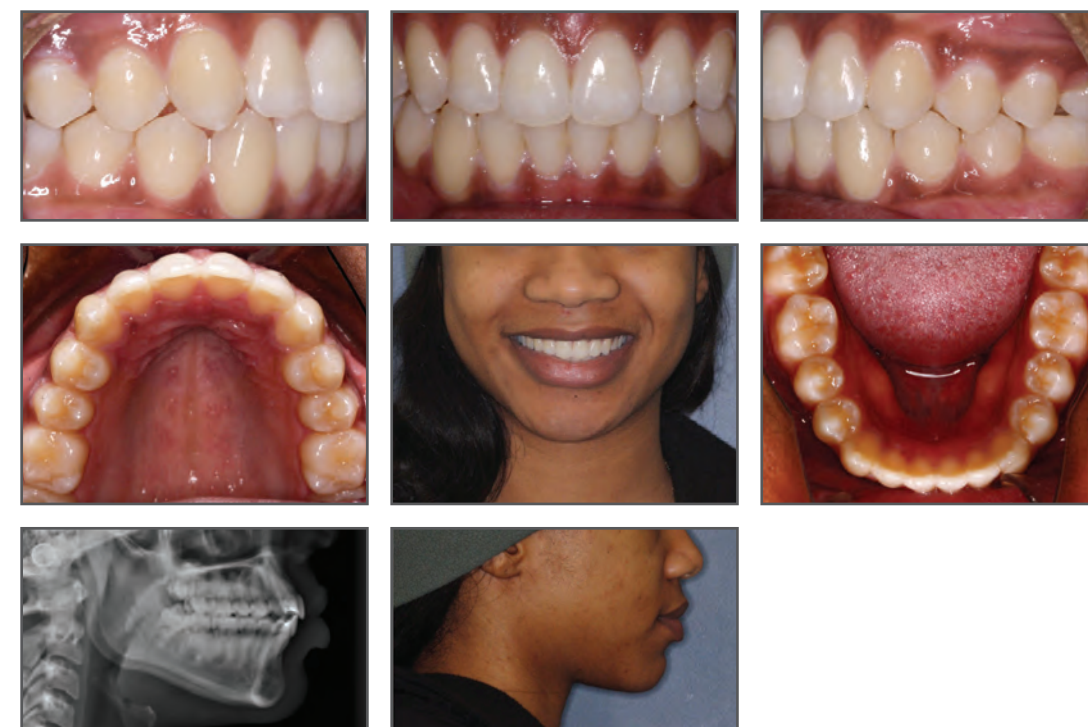
www.drDougCrosby.com

TREATMENT SUMMARY

PATIENT	20-year-old female
CHIEF CONCERN	"I can't bite on my front teeth."
DIAGNOSIS	Right: Class I Left: Class I Bimaxillary protrusion, anterior crowding, and anterior open bite.
LENGTH OF TREATMENT	12 months
# OF ALIGNERS USED	Upper: 18 + 10 Lower: 18 + 10
ADDITIONAL TREATMENT	None
RETENTION	Upper: Bonded lingual Lower: Bonded lingual



BEFORE



AFTER

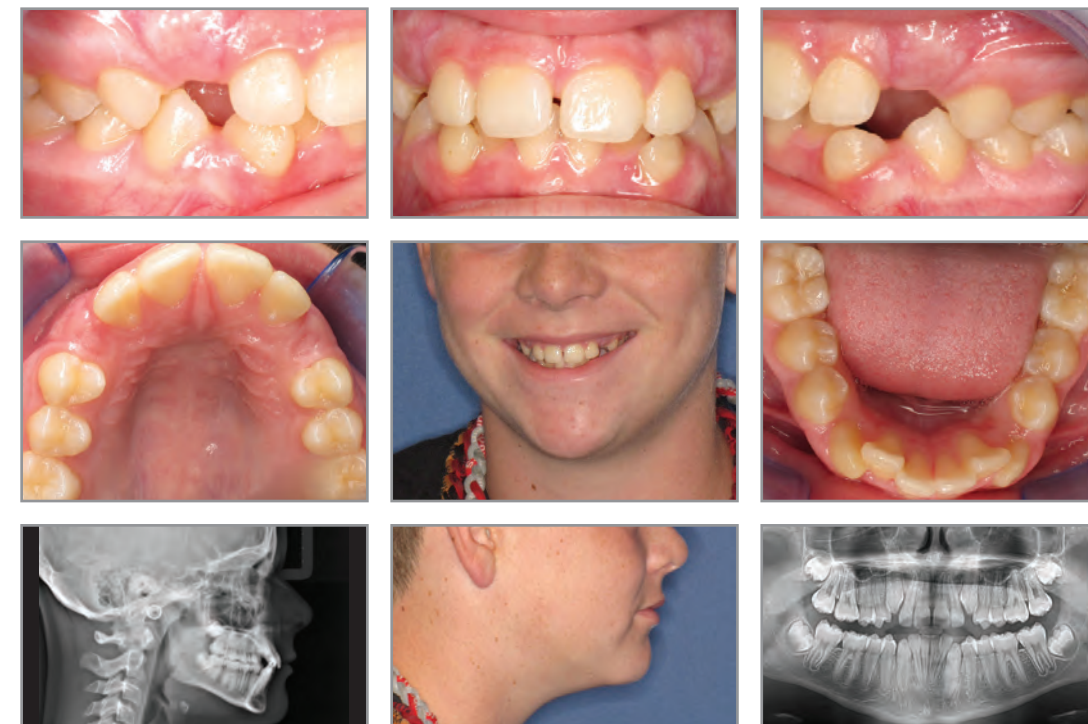


Dr. James Crouse
James M. Crouse, DDS
Salisbury, MD

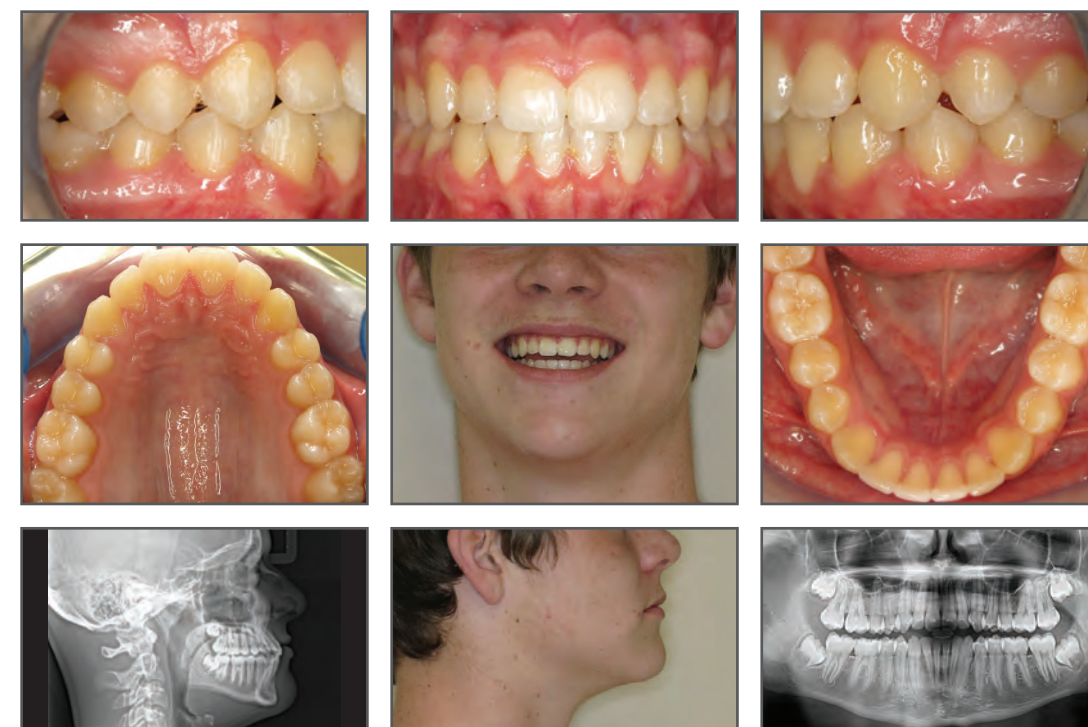
www.drcrousesbraceplace.com

TREATMENT SUMMARY

PATIENT	12-year-old male
CHIEF CONCERN	The patient wanted straight teeth.
DIAGNOSIS	Right: Class I Left: Class I Unerupted upper cuspids. 4 mm mandibular crowding and 2 mm maxillary crowding, 4 mm overbite and 3 mm overjet. Excessive lip curl.
LENGTH OF TREATMENT	18 months
# OF ALIGNERS USED	Upper: 40 + 30 Lower: 40 + 30
ADDITIONAL TREATMENT	None
RETENTION	Upper: Other clear Lower: Bonded lingual



BEFORE



AFTER

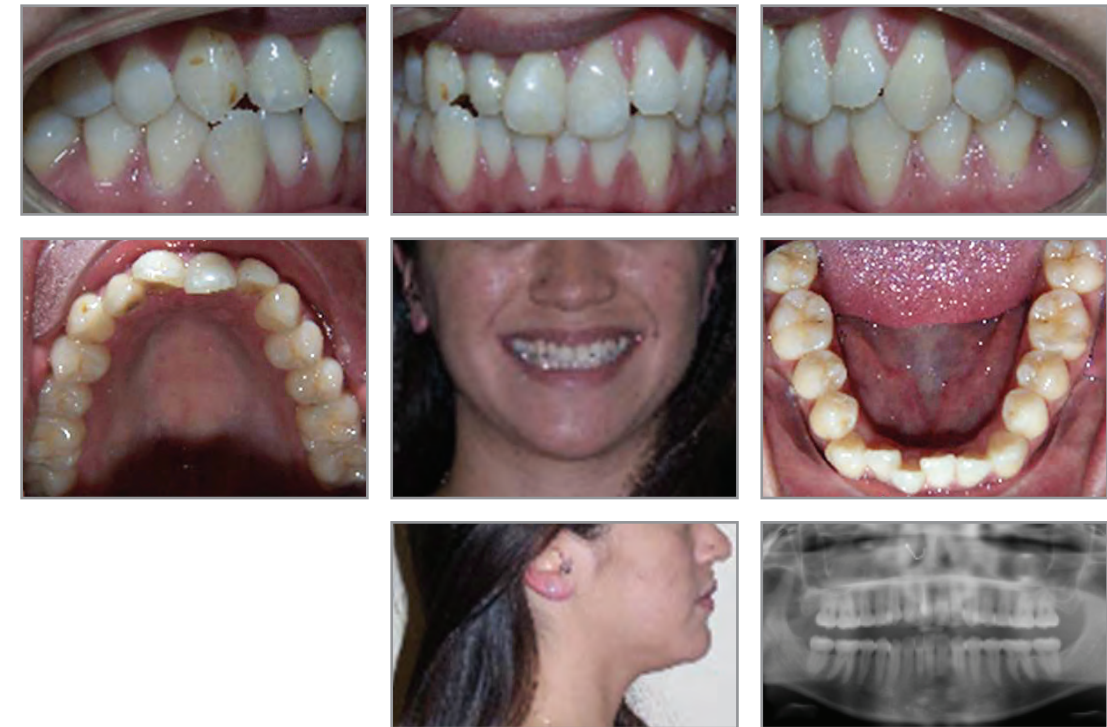


Dr. Mark Garlington
Mark A. Garlington, DDS
Long Beach, CA

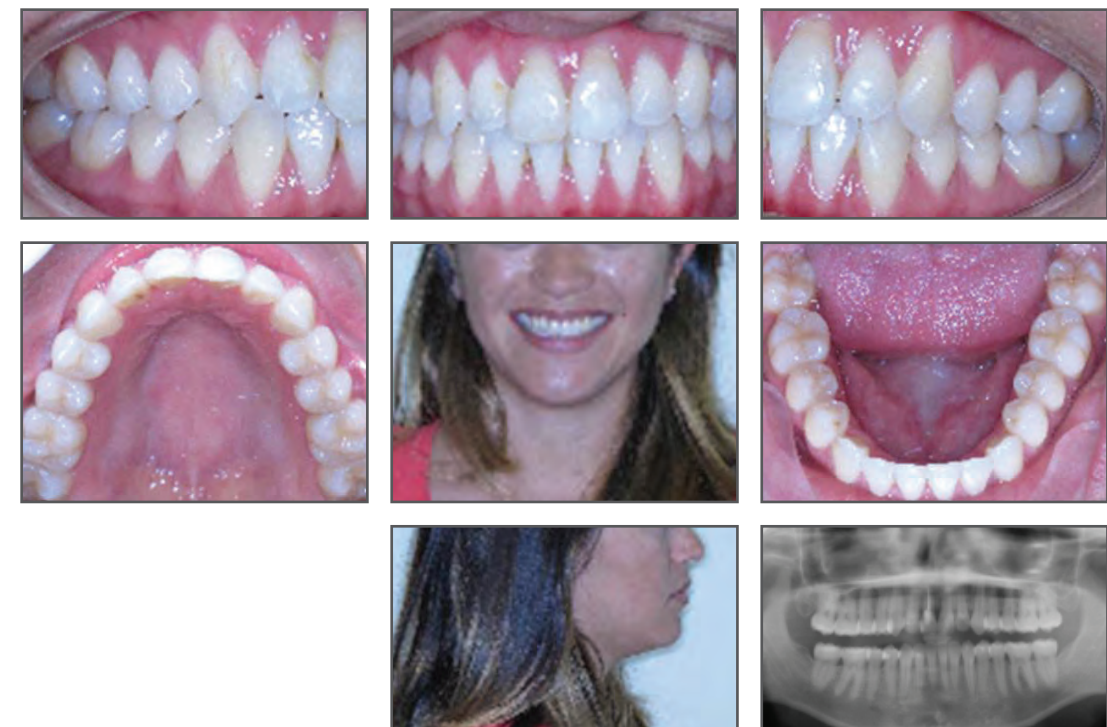
www.drg4smiles.com

TREATMENT SUMMARY

PATIENT	27-year-old female
CHIEF CONCERN	The patient did not like the way her front teeth looked.
DIAGNOSIS	Right: Class I Left: Class I Class I malocclusion with upper and lower crowding, anterior open bite, and upper right lateral and lower right cuspid in crossbite.
LENGTH OF TREATMENT	25 months
# OF ALIGNERS USED	Upper: 16 + 13 + 15 Lower: 16 + 13 + 15
ADDITIONAL TREATMENT	None
RETENTION	Upper: Vivera® Lower: Vivera®



BEFORE



AFTER

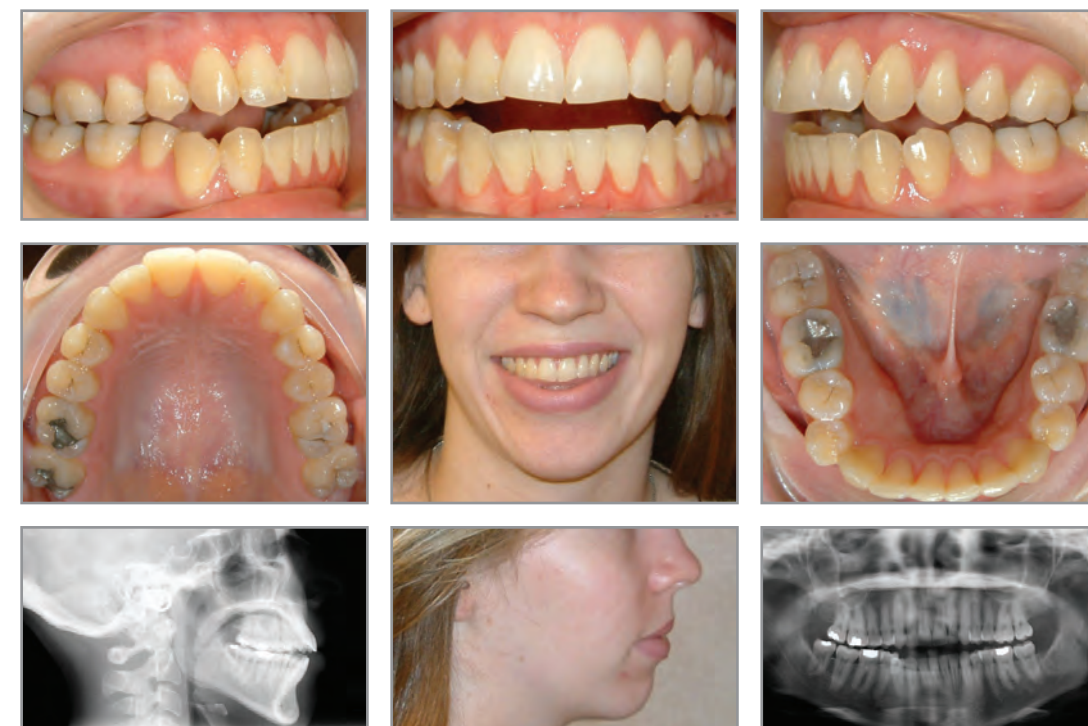


Drs. Stanley and Scott Gersch
Gersch Orthodontics
Westfield, NJ

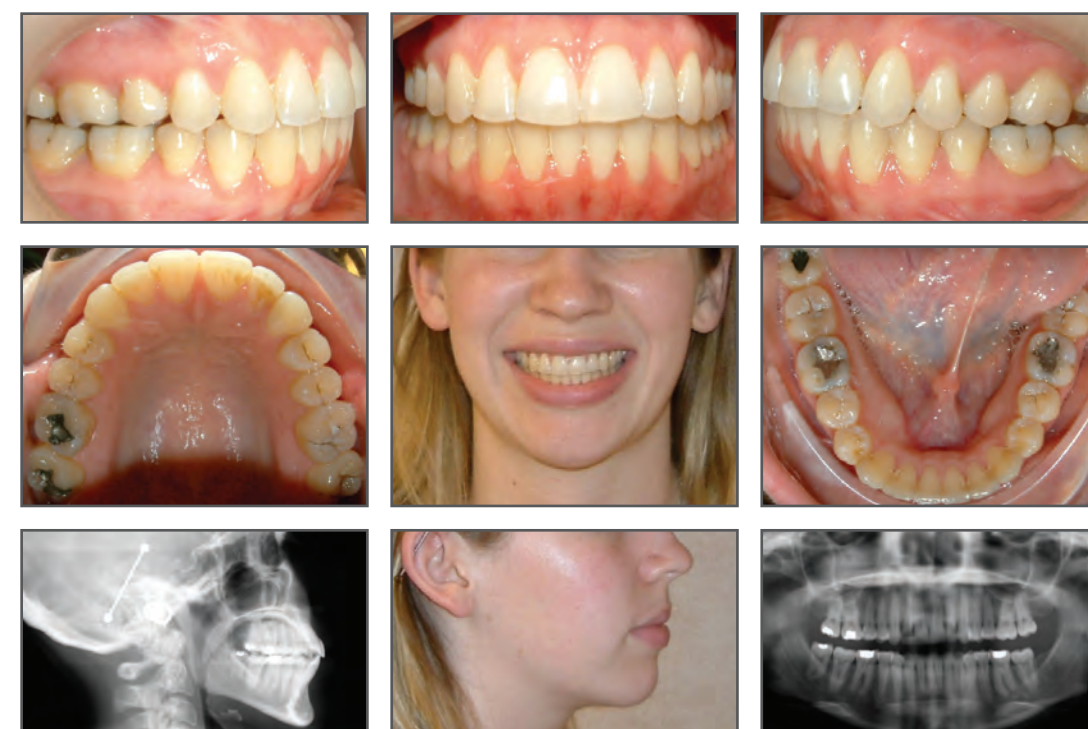
www.GerschOrtho.com

TREATMENT SUMMARY

PATIENT	23-year-old female
CHIEF CONCERN	"My bite is open."
DIAGNOSIS	Right: Class I Left: Class I Super Class I/Class III tendency cuspid with Class III molar relationship on the right side.
LENGTH OF TREATMENT	17 months
# OF ALIGNERS USED	Upper: 20 Lower: 20
ADDITIONAL TREATMENT	Posterior buccal and palatal TADs bilaterally, with 1/4" extra-heavy sling elastics worn for 7 months to aid in posterior intrusion.
RETENTION	Upper: Essix® Lower: Essix®



BEFORE



AFTER



Dr. William Grieve
Dr. W. Gray Grieve Orthodontics
Eugene, OR

www.coolorthodontist.com

TREATMENT SUMMARY

PATIENT 16-year-old male

CHIEF CONCERN Alignment of the teeth. "[My] teeth may need to be pulled?"

DIAGNOSIS
Right: Class I
Left: Class I

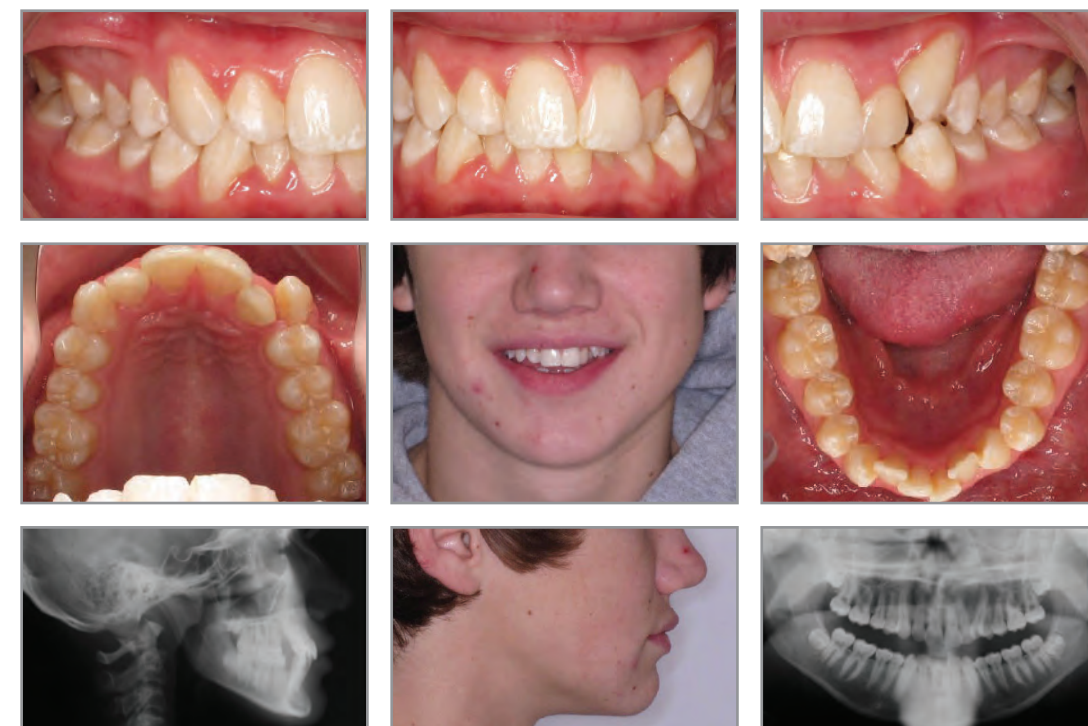
Balanced profile, with normal vertical dimension. Good smile line, with lips relaxed at closure. Anterior crossbite #10, upper midline shifted to the left by 2 mm. Mild fluorosis present on several teeth.

LENGTH OF TREATMENT 21 months

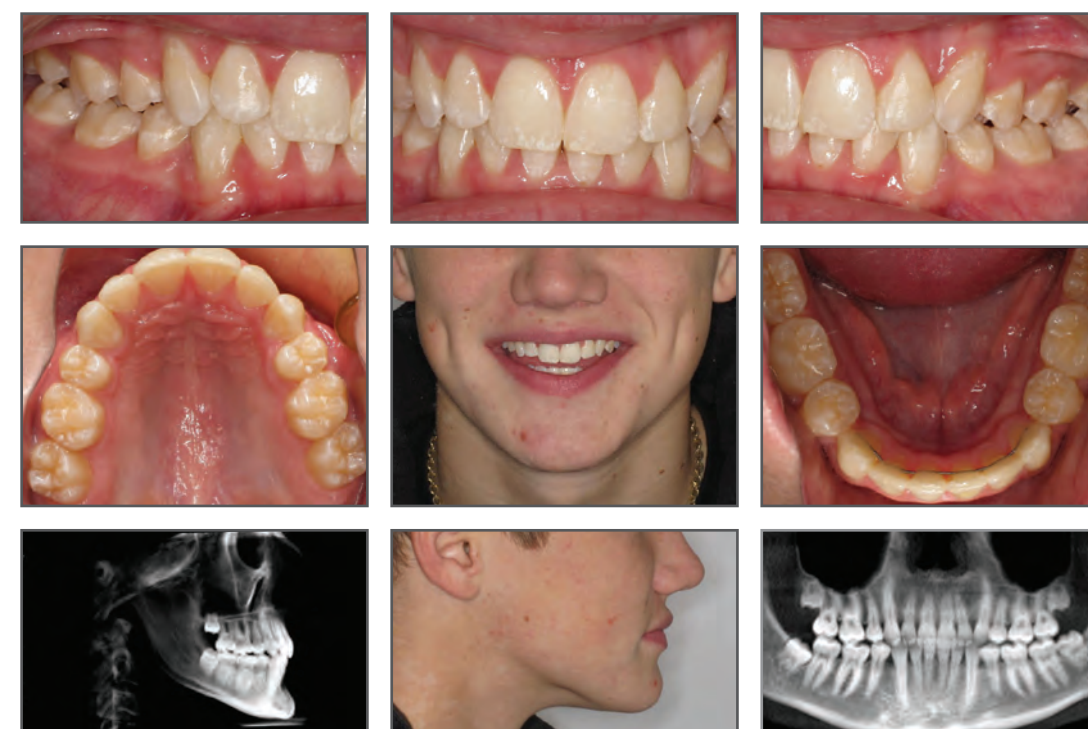
OF ALIGNERS USED
Upper: 45
Lower: 45

ADDITIONAL TREATMENT Tooth numbers 5, 12, 21, and 28 were extracted.

RETENTION
Upper: Essix®
Lower: Essix® over bonded lingual



BEFORE



AFTER

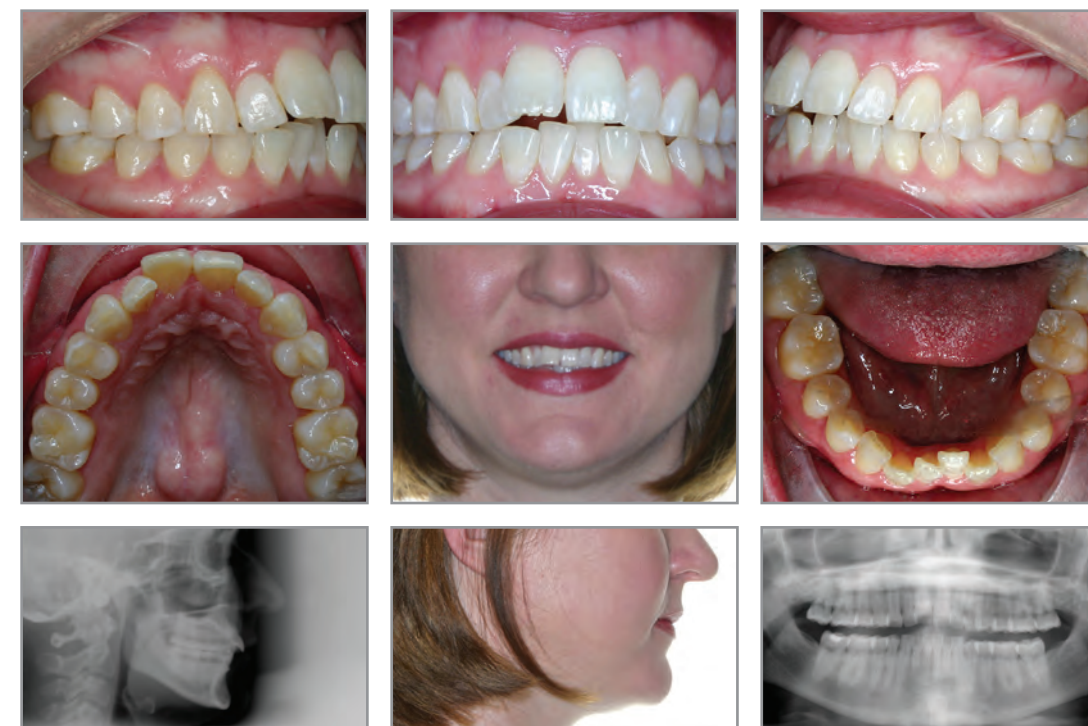

Dr. William Heintz
Heintz Orthodontics
Alton, IL

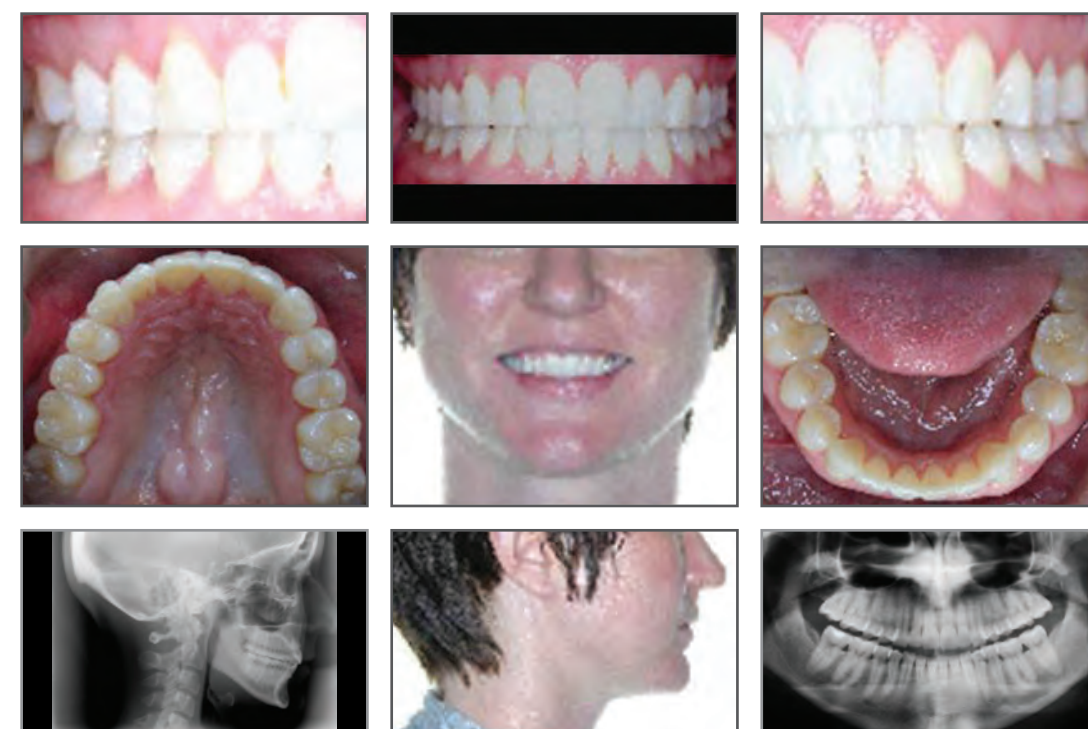www.drheintzorthodontics.com

TREATMENT SUMMARY

PATIENT	31-year-old female
CHIEF CONCERN	"My teeth are very crowded. I don't like my overbite. I have trouble biting things with my front teeth."
DIAGNOSIS	Right: Class I Left: Class I Open bite, crowding, and excessive overjet.
LENGTH OF TREATMENT	18 months
# OF ALIGNERS USED	Upper: 29 + 13 Lower: 29 + 13
ADDITIONAL TREATMENT	Class II elastics worn for 8 months (aligners #8-26) to reduce overjet and back up power ridges while establishing anterior torque, with elastic hooks near the upper cuspids and lower molars.
RETENTION	Upper: Bonded lingual Lower: Essix® over bonded lingual



BEFORE



AFTER

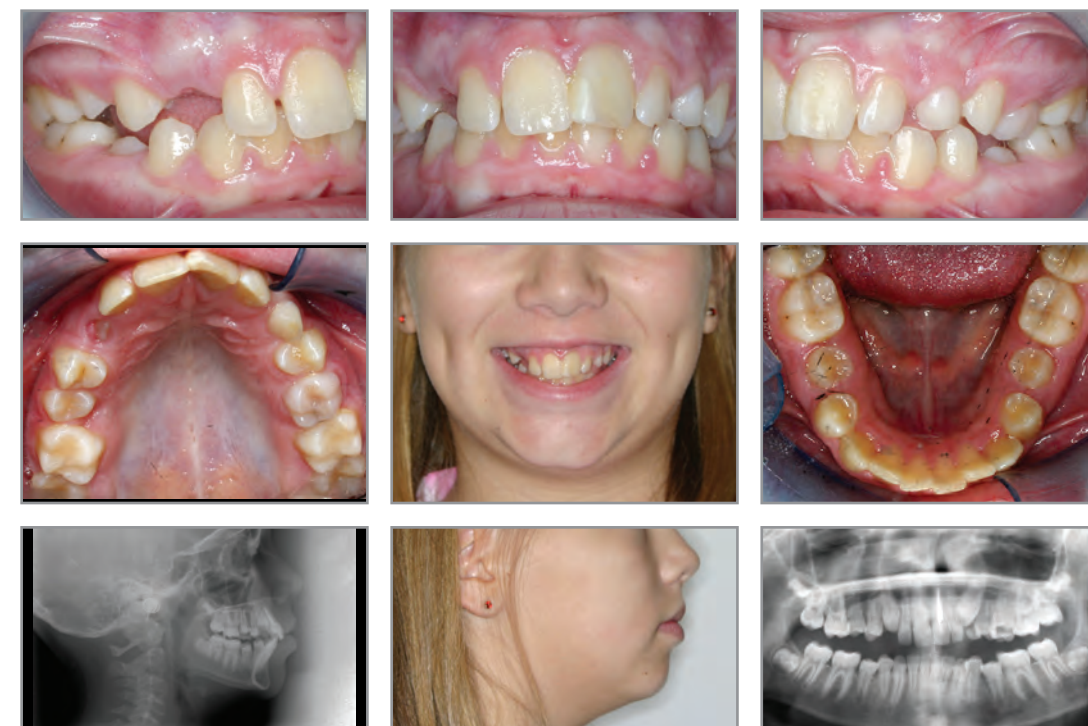


Dr. William Heintz
Heintz Orthodontics
Alton, IL

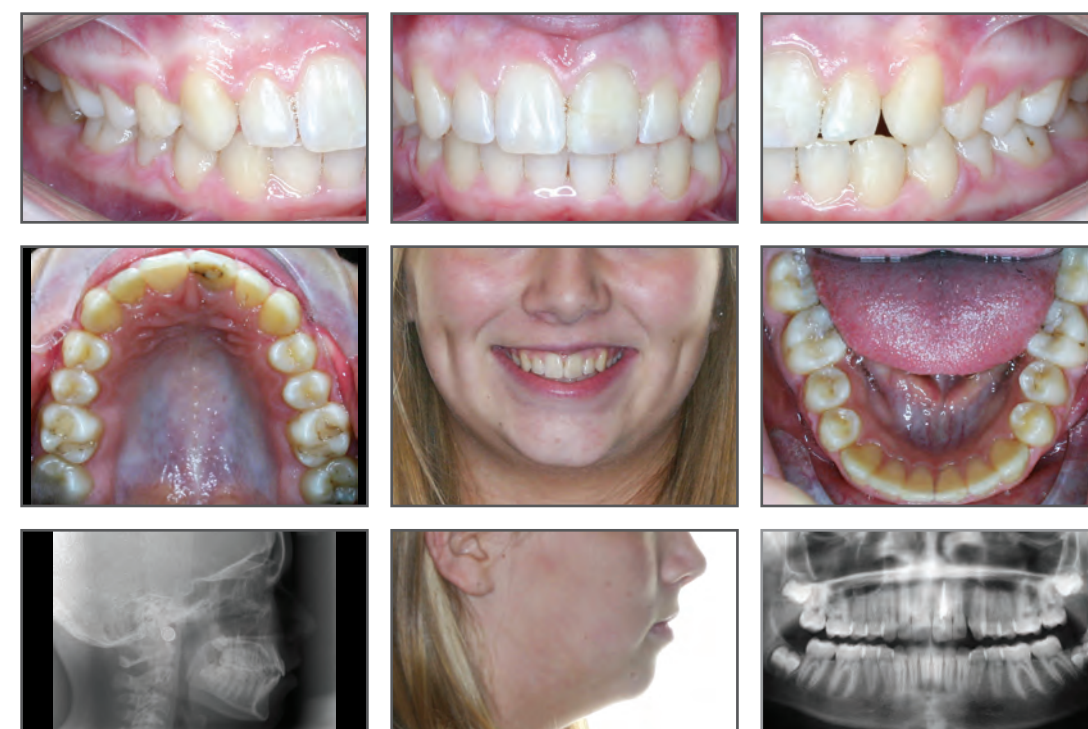www.drheintzorthodontics.com

TREATMENT SUMMARY

PATIENT	11-year-old female
CHIEF CONCERN	"My teeth are crooked and I have buck teeth."
DIAGNOSIS	Right: Class I Left: Class I Class I dental, Class II skeletal. Deep bite, excessive overjet, and crowding. Impacted maxillary left permanent canine.
LENGTH OF TREATMENT	34 months
# OF ALIGNERS USED	Upper: 21 + 21 + 14 Lower: 21 + 21 + 14
ADDITIONAL TREATMENT	Sling elastics connected to a button on the maxillary left permanent canine were used for eight months to bring in UL3. Class II elastics were used for six months. Seating elastics were used for two months to seat buccal segment occlusion.
RETENTION	Upper: Vivera® Lower: Vivera®



BEFORE



AFTER



Dr. Sean Holliday
Holliday Orthodontics
Pearl City, HI

www.dochollidaybraces.com

TREATMENT SUMMARY

PATIENT 13-year-old female

CHIEF CONCERN The patient had missing teeth and spaces.

DIAGNOSIS Right: Class I
Left: Class I

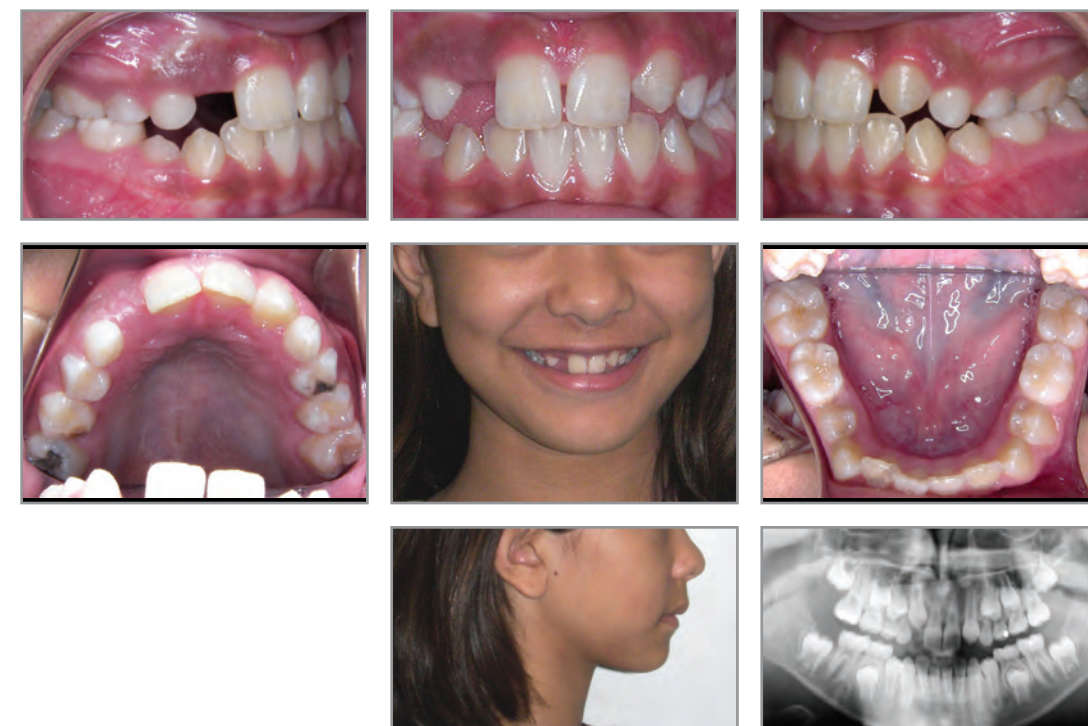
Missing maxillary lateral incisors. Upper anterior spaces and lower anterior crowding present. Minimal overjet and shallow overbite. Midline deviation.

LENGTH OF TREATMENT 27 months

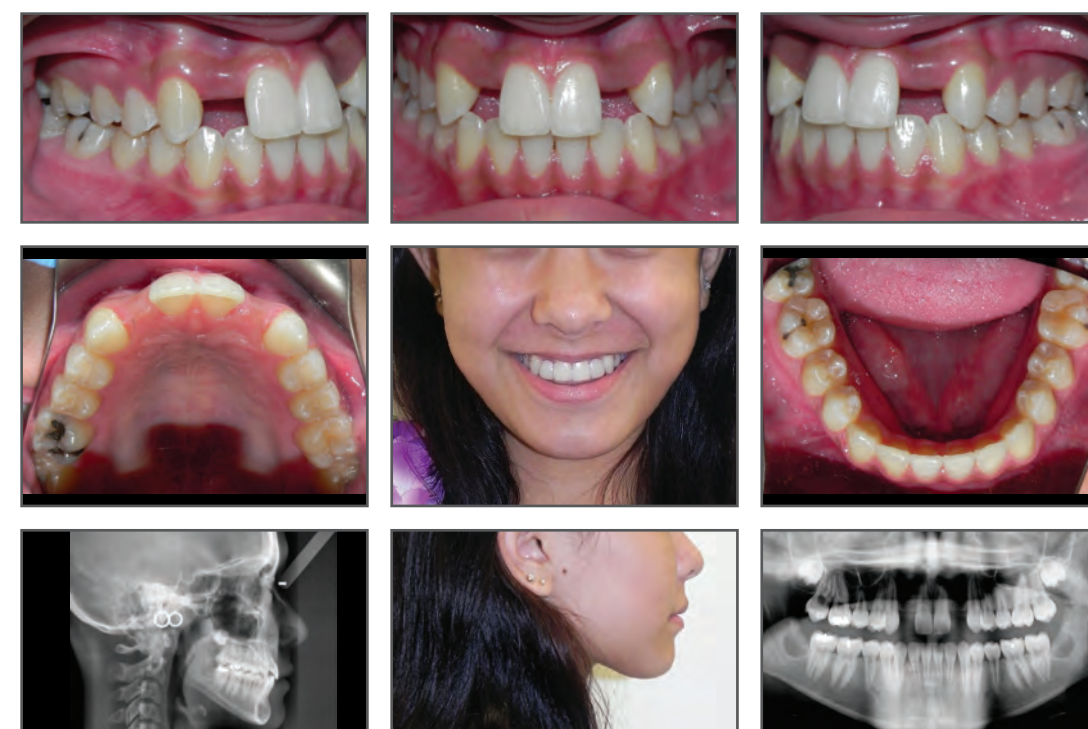OF ALIGNERS USED Upper: 38 + 24
Lower: 38 + 24

ADDITIONAL TREATMENT Class III elastics were used for 10 months during refinement, with hooks cut into the aligners near the upper first molars and lower first bicuspids. Retainers with 7.5 mm lateral incisor pontics were used to preserve space until dental implants/crowns could be placed.

RETENTION Upper: Vivera® with pontics
Lower: Vivera®



BEFORE



AFTER



Dr. Lindsay Jackfert
Panucci and Jackfert Orthodontics
South Charleston, WV

www.panuccismiles.com

TREATMENT SUMMARY

PATIENT 67-year-old female

CHIEF CONCERN The patient was concerned that her teeth were shifting.

DIAGNOSIS
Right: Class I
Left: Class I

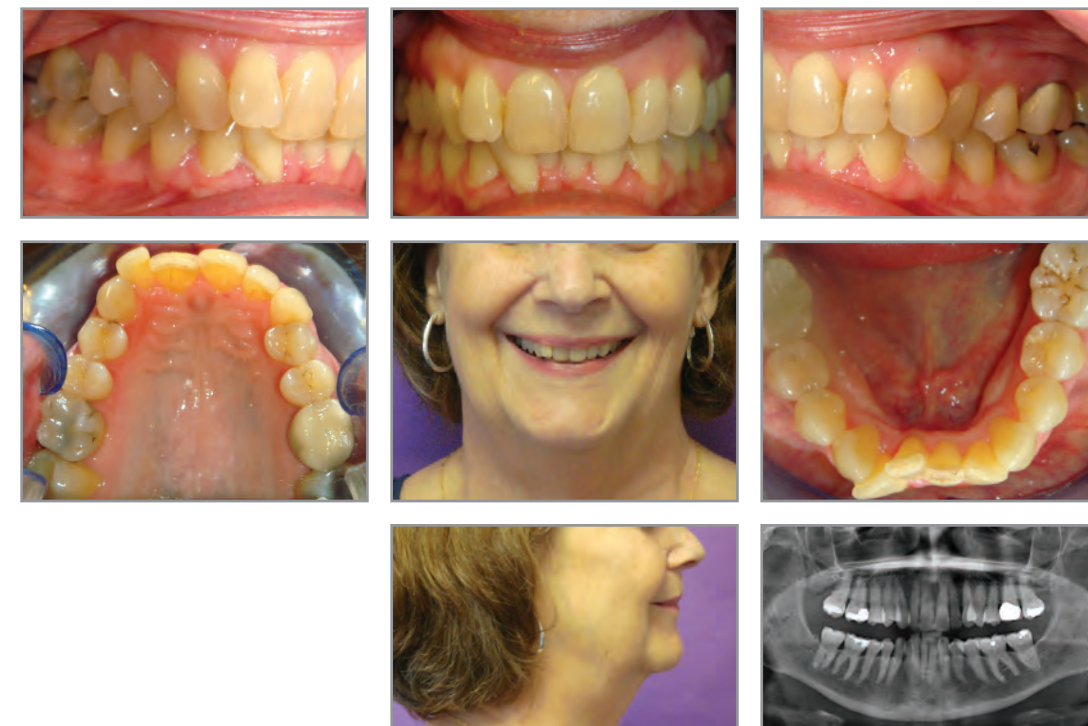Moderate upper crowding with severe lower crowding. Lingual inclination of the upper central incisors. Retrognathic mandible. Recession of the mandibular anterior teeth. Incisal wear of the anterior teeth. Moderate maxillary bone loss.

LENGTH OF TREATMENT 17 months

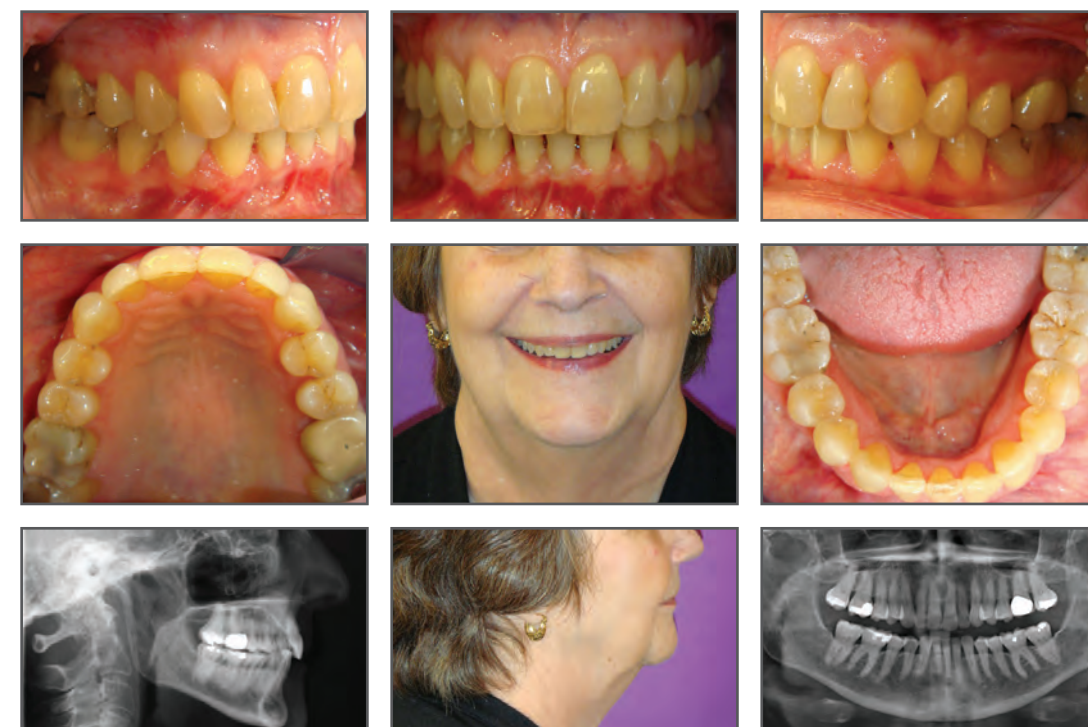OF ALIGNERS USED
Upper: 18
Lower: 33

ADDITIONAL TREATMENT Extracted LR2 due to the severity of crowding. Used lingual bite ramps in the upper aligners to help with overbite correction and power ridges for torque control.

RETENTION
Upper: Other clear
Lower: Other clear



BEFORE



AFTER



Dr. Paul Kasrovi
Berkeley Orthodontics
Berkeley, CA

www.berkeleyorthodontics.com

TREATMENT SUMMARY

PATIENT 26-year-old male

CHIEF CONCERN "My teeth are crooked and they don't touch."

DIAGNOSIS
Right: Class I
Left: Class I

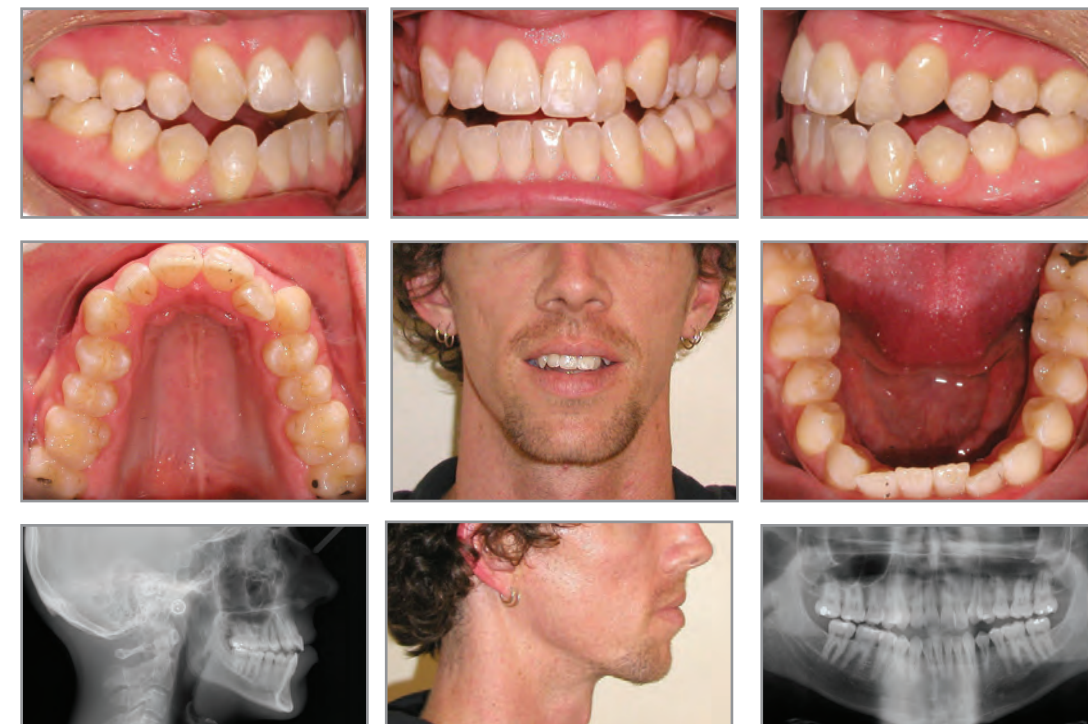Open bite from 5-5 (2-3 mm in the anterior), crossbite UL2, excessive overjet, midlines off by 2-3 mm, and upper and lower crowding. Narrow, omega-shaped upper arch. 80% upper incisor show on smiling.

LENGTH OF TREATMENT 42 months

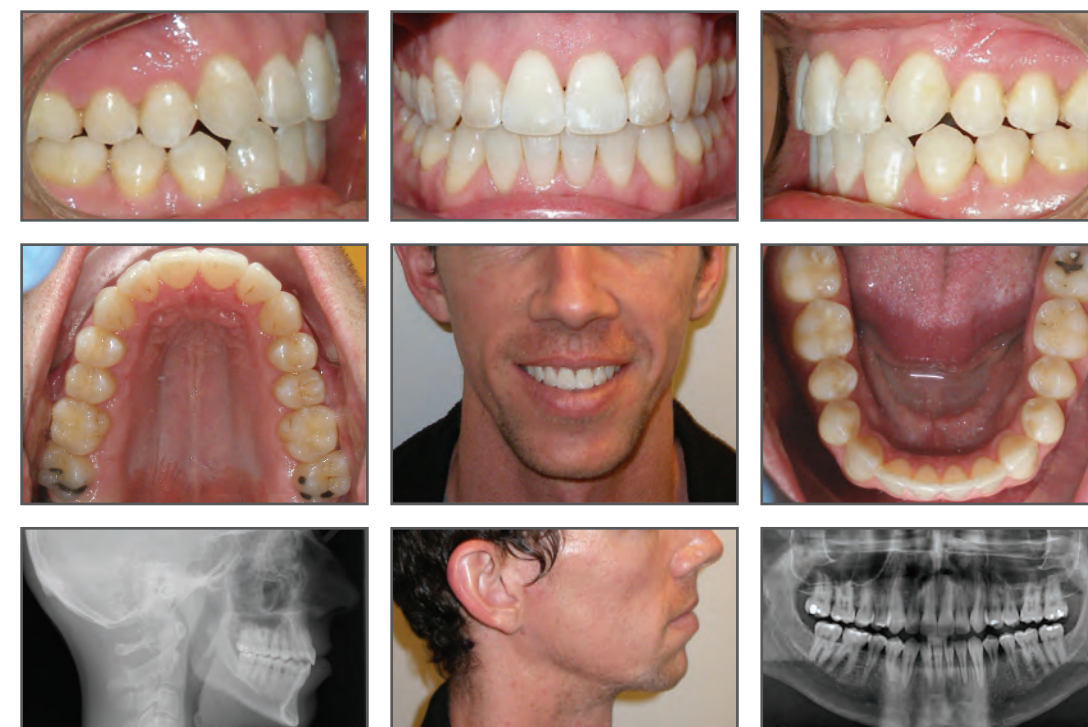OF ALIGNERS USED
Upper: 24 + 17 + 19
Lower: 24 + 17 + 19

ADDITIONAL TREATMENT To help close the posterior open bite, mid-treatment sectional braces with vertical elastics were used from canine to first molar in the upper and lower arches for 6 months.

RETENTION
Upper: Other clear
Lower: Other clear



BEFORE



AFTER

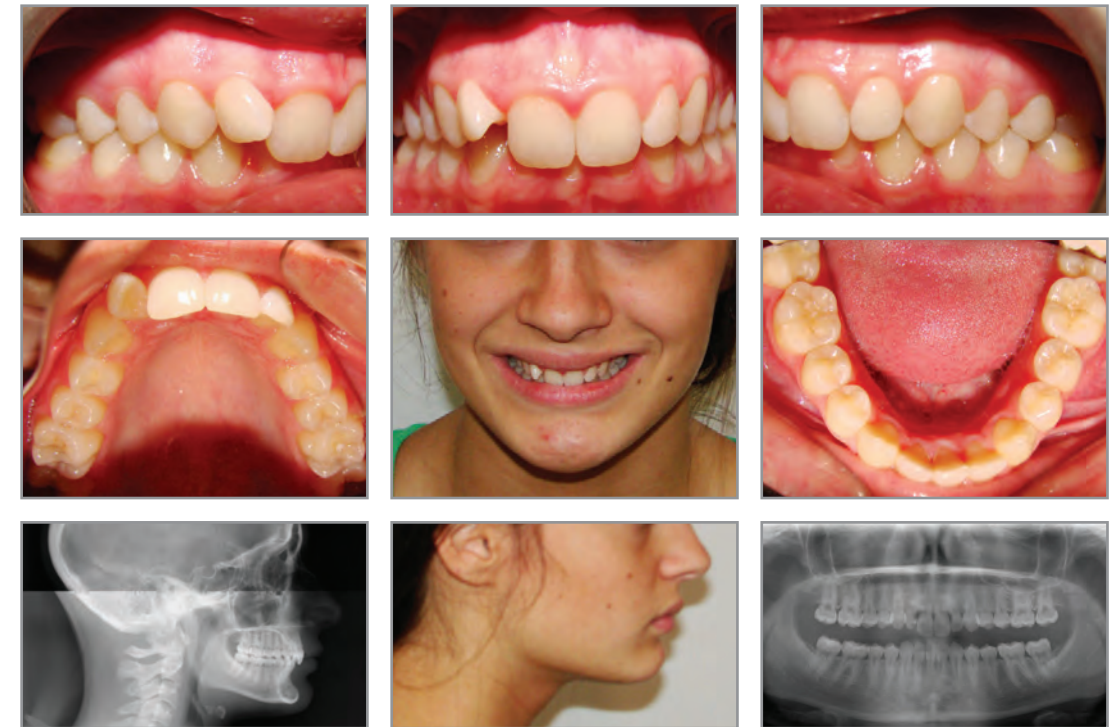

Dr. Steven Luccarelli
Williston Orthodontics
Mineola, NY

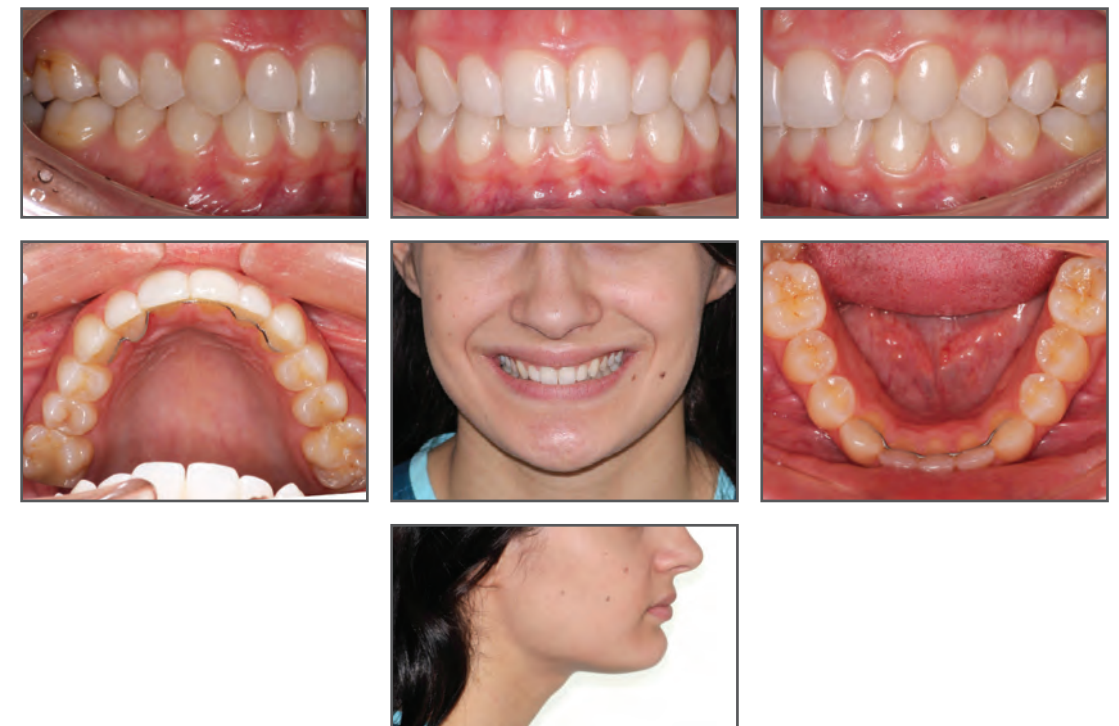www.longislandorthodontics.com

TREATMENT SUMMARY

PATIENT	17-year-old female
CHIEF CONCERN	The patient was concerned about her crowding and overjet.
DIAGNOSIS	Right: Class I Left: Class I Missing mandibular left lateral incisor (agenesis), "Division 2" upper incisor appearance on right side, with deep bite and excessive overjet. Under-torqued maxillary and mandibular incisors.
LENGTH OF TREATMENT	26 months
# OF ALIGNERS USED	Upper: 17 + 10 + 15 Lower: 17 + 10 + 15
ADDITIONAL TREATMENT	None
RETENTION	Upper: Essix® over bonded lingual Lower: Essix® over bonded lingual



BEFORE



AFTER



Dr. Michelle Fogg Neal
Michelle Fogg Neal, DDS
Kirkland, WA

www.nealsmiles.com

TREATMENT SUMMARY

PATIENT 15-year-old male

CHIEF CONCERN The patient had previously been treated with Phase I orthodontics for his "underbite." The treatment was successful, but the bite has since relapsed during pubertal growth.

DIAGNOSIS Right: Class I
Left: Class I

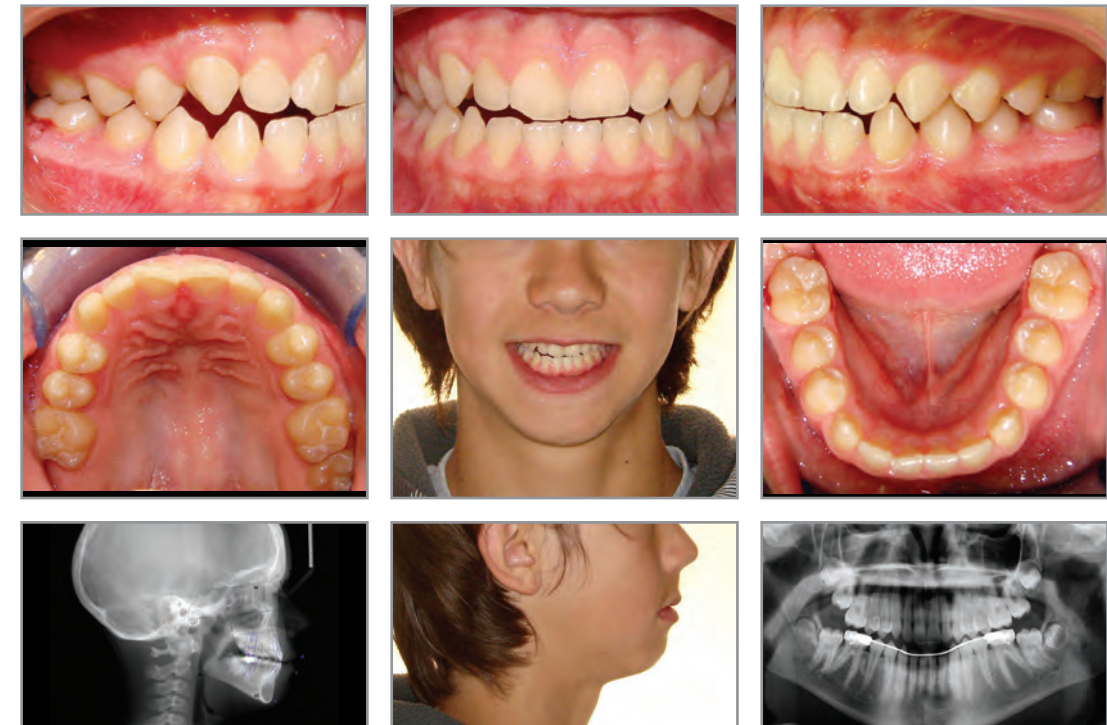
Anterior open bite with 0 mm overjet. Nocturnal bruxism habit with enamel attrition of the incisors. Prior Phase 1 orthodontic treatment for Class III correction during mixed dentition included an RPE, a reverse-pull HG, Mx 2x4, and a lower lingual arch during retention.

LENGTH OF TREATMENT 20 months

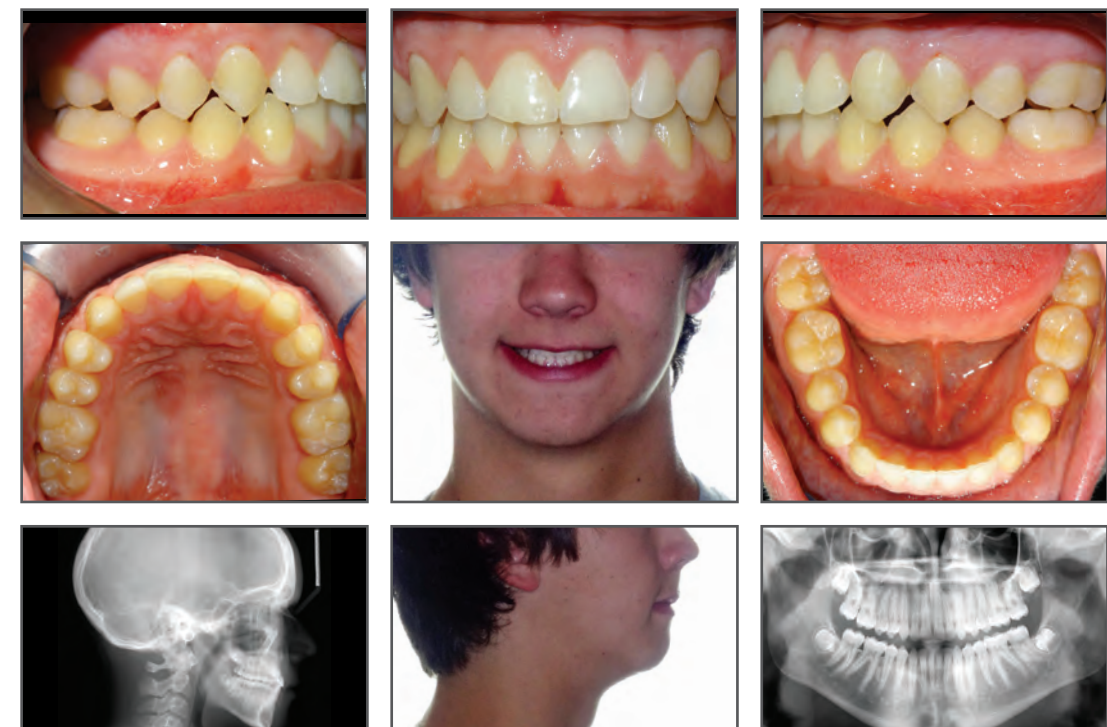
OF ALIGNERS USED Upper: 21 + 9
Lower: 23 + 10

ADDITIONAL TREATMENT Class III elastics were used throughout the duration of treatment, with buttons bonded to the upper first molars and hooks cut into the lower aligners near the first bicusps. Box elastics were used at the end of treatment, with buttons bonded to UR 3/4 and LR 4/5. Veneers were recommended but declined.

RETENTION Upper: Vivera®
Lower: Vivera®



BEFORE



AFTER



Dr. Jonathan Nicozisis
Princeton Orthodontics
Princeton, NJ

www.princetonorthodontics.net

TREATMENT SUMMARY

PATIENT 25-year-old female

CHIEF CONCERN The patient was concerned about her crowded teeth, uneven smile, and crossbite.

DIAGNOSIS
Right: Class I
Left: Class I

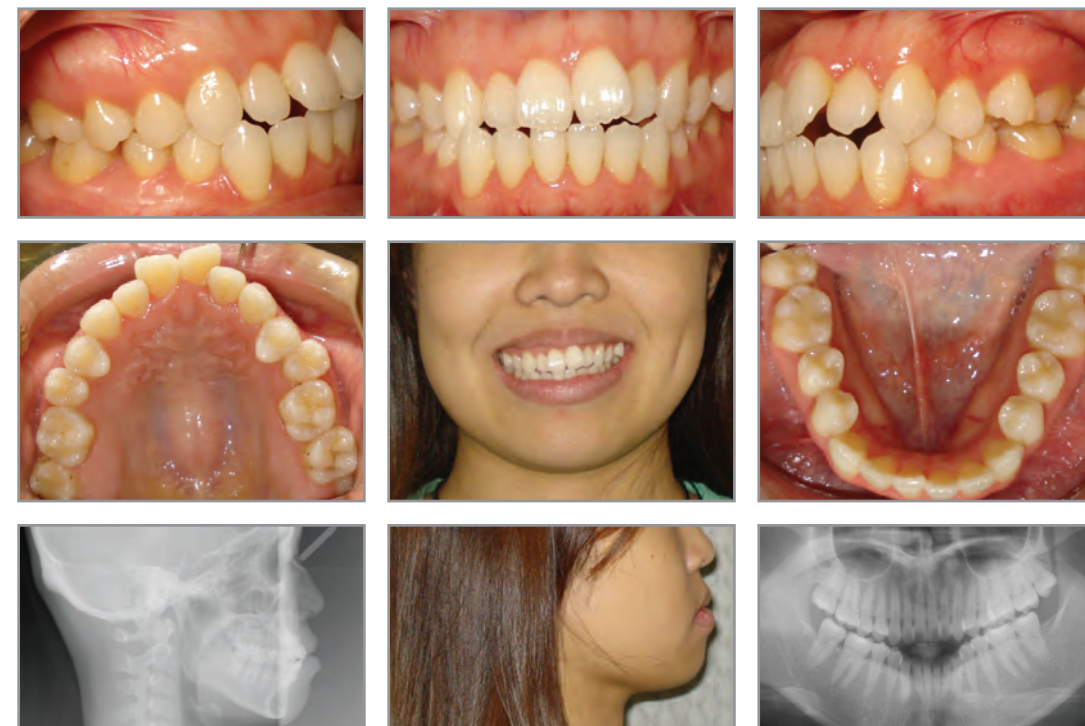
Crowding, uneven smile line, upper left second bicuspid in buccal crossbite, and canted occlusal plane.

LENGTH OF TREATMENT 13 months

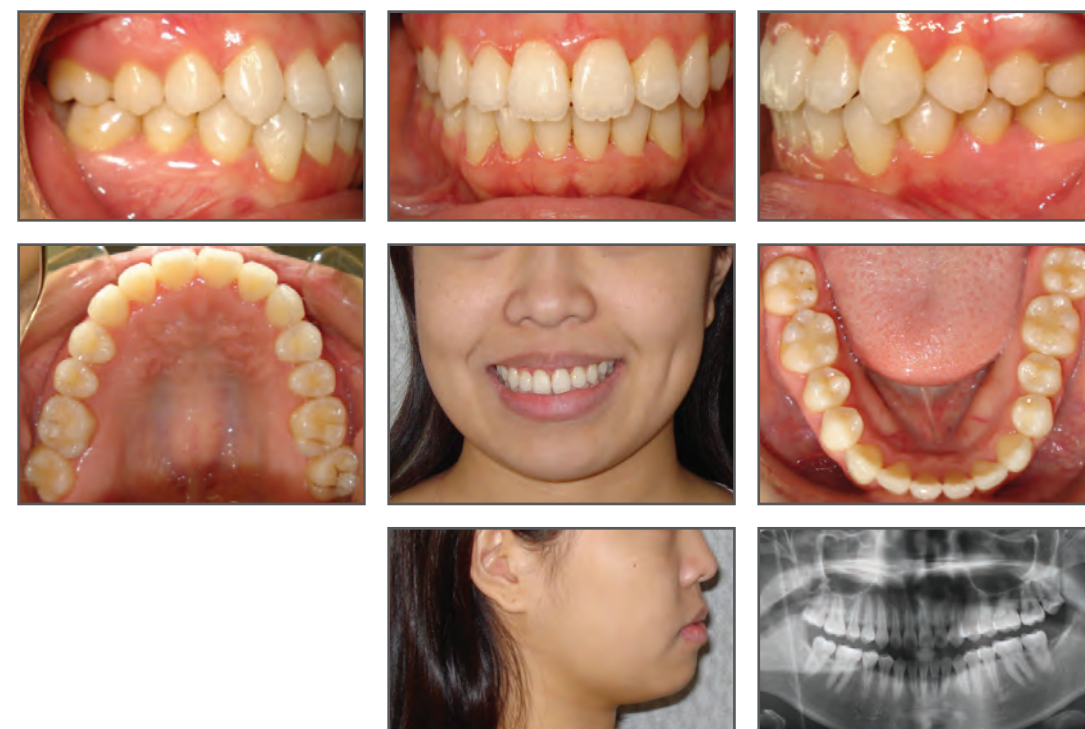OF ALIGNERS USED
Upper: 28
Lower: 28

ADDITIONAL TREATMENT None

RETENTION
Upper: Essix® over bonded lingual
Lower: Essix® over bonded lingual



BEFORE



AFTER



Dr. Jonathan Nicozisis
Princeton Orthodontics
Princeton, NJ

www.princetonorthodontics.net

TREATMENT SUMMARY

PATIENT 14-year-old female

CHIEF CONCERN The patient was concerned about her palatally-erupted cuspid and did not want fixed braces in high school.

DIAGNOSIS Right: Class I
Left: Class I

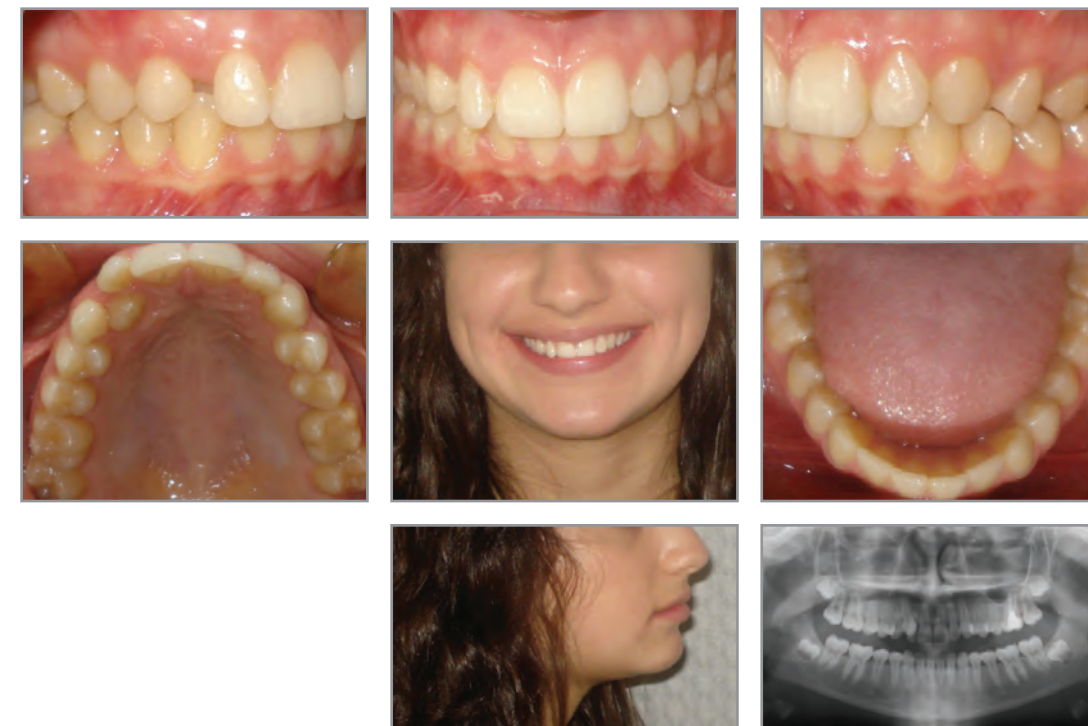
Palatally-erupted upper right permanent cuspid with retained primary cuspid.
No orthodontic treatment planned in the lower arch.

LENGTH OF TREATMENT 18 months

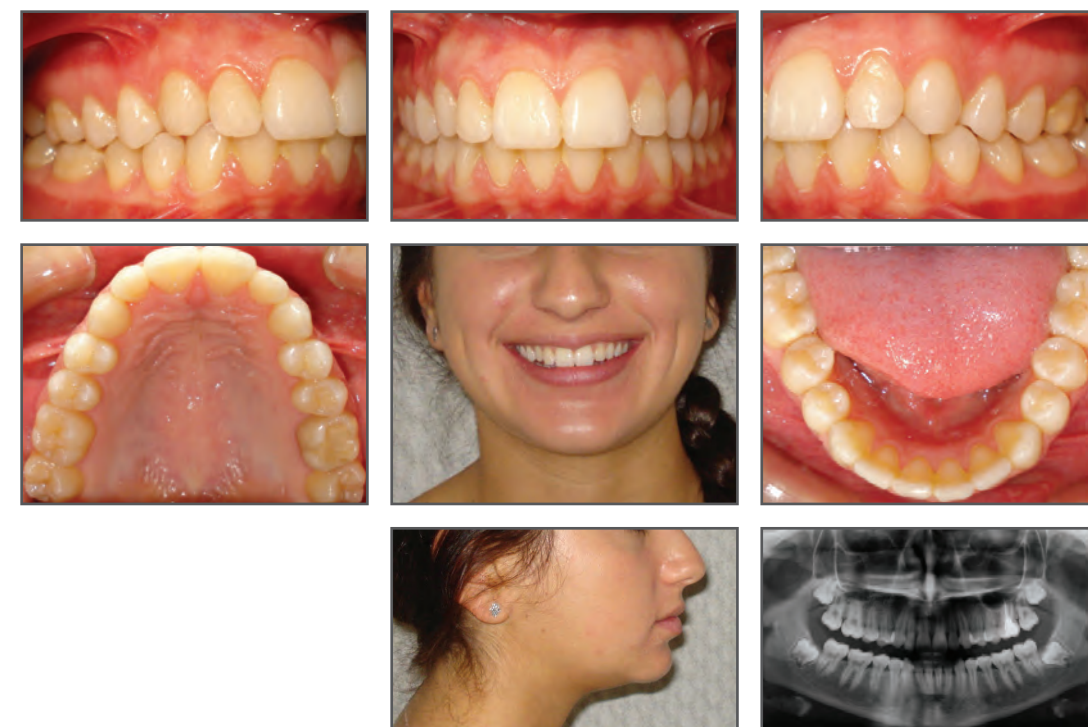
OF ALIGNERS USED Upper: 28 + 14
Lower: 0 (arch was not treated)

ADDITIONAL TREATMENT Extraction of retained primary upper right cuspid.

RETENTION Upper: Other clear
Lower: N/A



BEFORE



AFTER

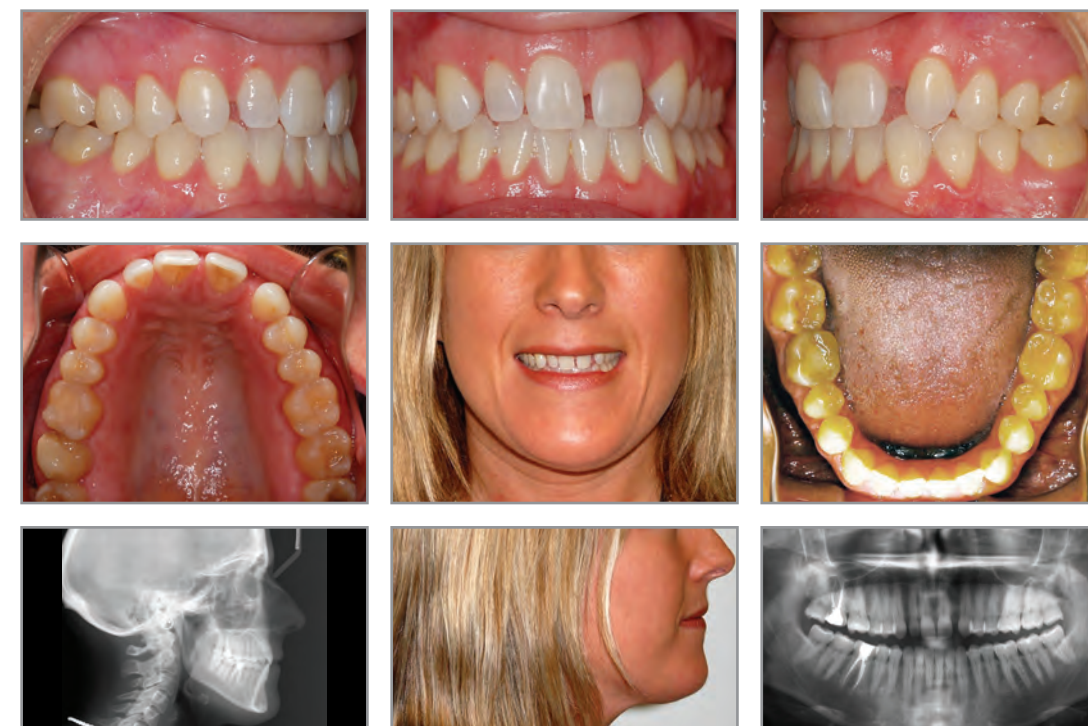

Dr. Bradley Nirenblatt
Nirenblatt Orthodontics
Charleston, SC

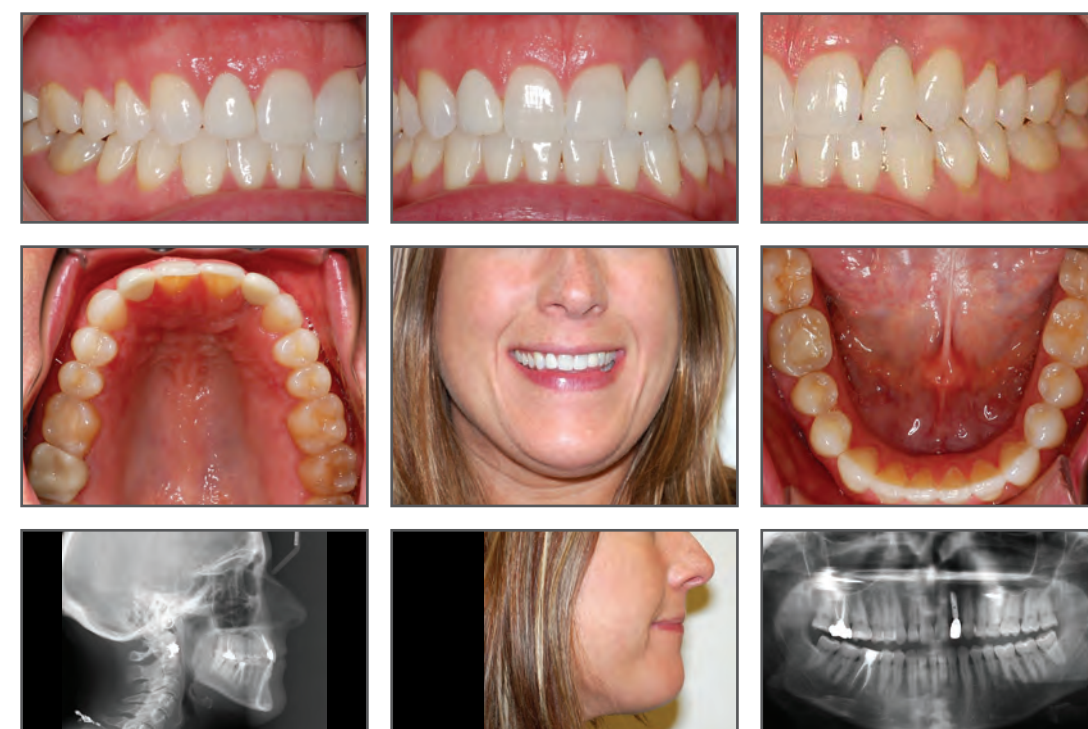
www.drnirenblatt.com

TREATMENT SUMMARY

PATIENT	41-year-old female
CHIEF CONCERN	Upper spacing and upper midline shift because of a small tooth #7 and missing tooth #10.
DIAGNOSIS	Right: Class I Left: Class I Upper spacing and lower crowding. Normal overbite and normal overjet. Upper midline shifted to the left because of missing tooth #10. Centered lower midline. Narrow tooth #7. Normal periodontium and healthy gingiva. TMJ clicking and limited movement. Good oral hygiene.
LENGTH OF TREATMENT	11 months
# OF ALIGNERS USED	Upper: 23 Lower: 23
ADDITIONAL TREATMENT	Tooth whitening, veneer for tooth #7, and implant and crown for tooth #10.
RETENTION	Upper: Other clear Lower: Other clear



BEFORE



AFTER



Drs. Robert and James Passamano
Passamano Orthodontics
Irvine, CA

www.youbraces.com

TREATMENT SUMMARY

PATIENT 65-year-old female

CHIEF CONCERN The patient was concerned about her crooked lower front teeth, and a space between her two front upper teeth.

DIAGNOSIS
Right: Class I
Left: Class I

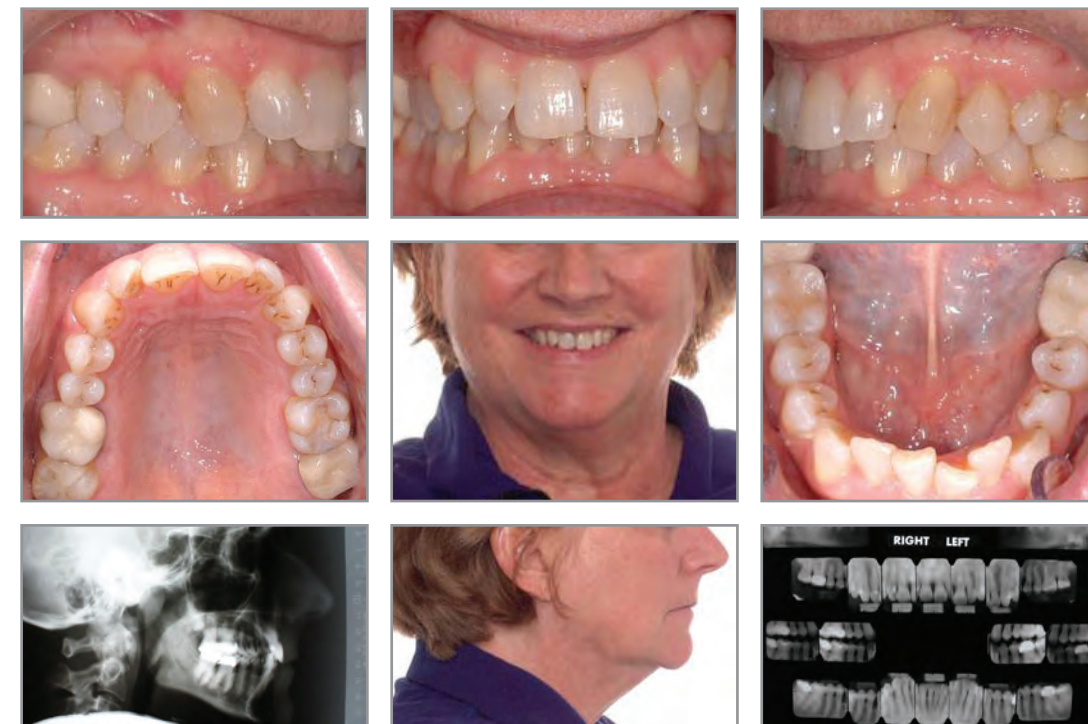
3 mm overjet, 4.5 mm overbite, and 5 mm mandibular crowding. "Division 2" upper incisor profile, with a black triangle space between the upper centrals. Lower dental midline is shifted 0.5 mm to the left of the upper dental midline. Gingival recession around the upper first bicuspid and upper right second bicuspid.

LENGTH OF TREATMENT 20 months

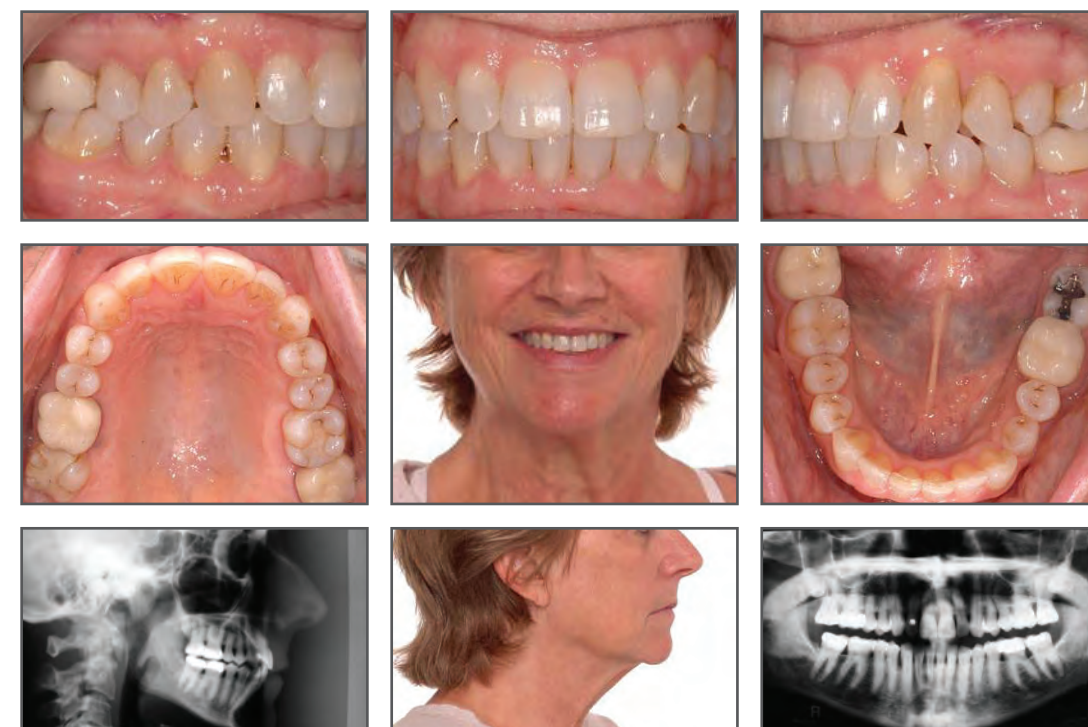OF ALIGNERS USED
Upper: 21 + 20
Lower: 21 + 17

ADDITIONAL TREATMENT None

RETENTION
Upper: Vivera®
Lower: Vivera®



BEFORE



AFTER



Dr. Luis Piedade
Ritebite Orthodontics
Waterloo, ON, Canada

www.ritebite.ca



TREATMENT SUMMARY

PATIENT 20-year-old male

CHIEF CONCERN The patient was concerned about his open bite.

DIAGNOSIS
Right: Class I
Left: Class I

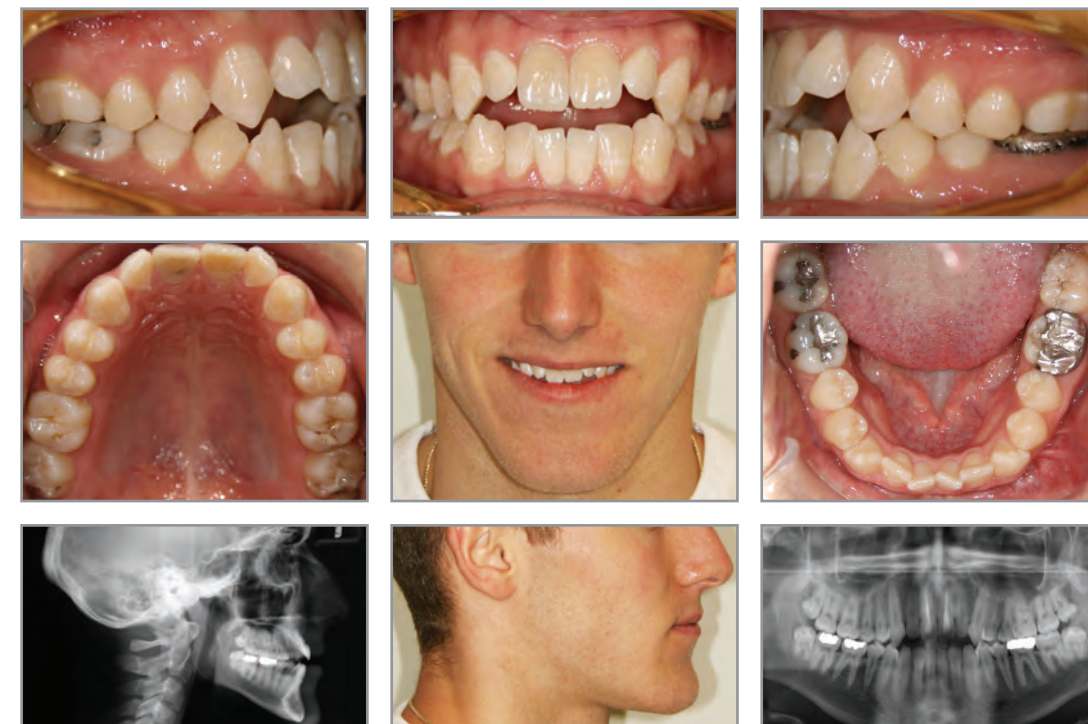
Mild to moderate crowding in both arches, and a moderate to severe anterior open bite.

LENGTH OF TREATMENT 24 months

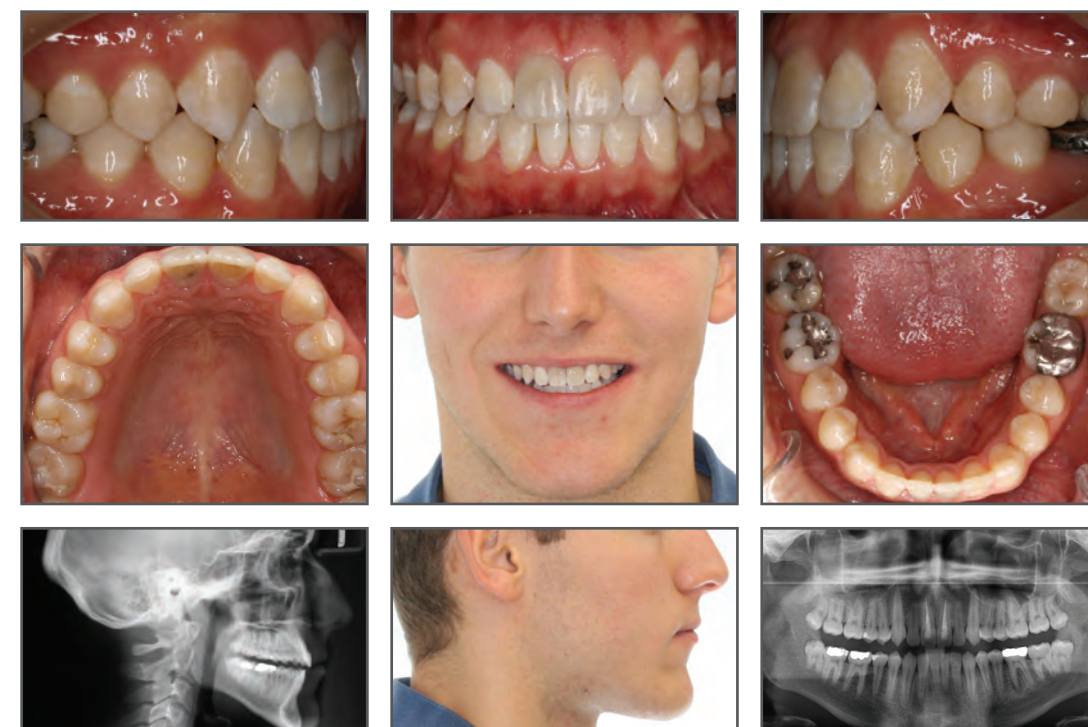
OF ALIGNERS USED
Upper: 42 + 27
Lower: 42 + 27

ADDITIONAL TREATMENT Upper TADs (4) placed buccally between the upper 6's and 7's and lingually between the upper 5's and 6's, with sling elastics over the aligners for 20 months to help intrude the posterior teeth.

RETENTION
Upper: Vivera®
Lower: Vivera®



BEFORE



AFTER

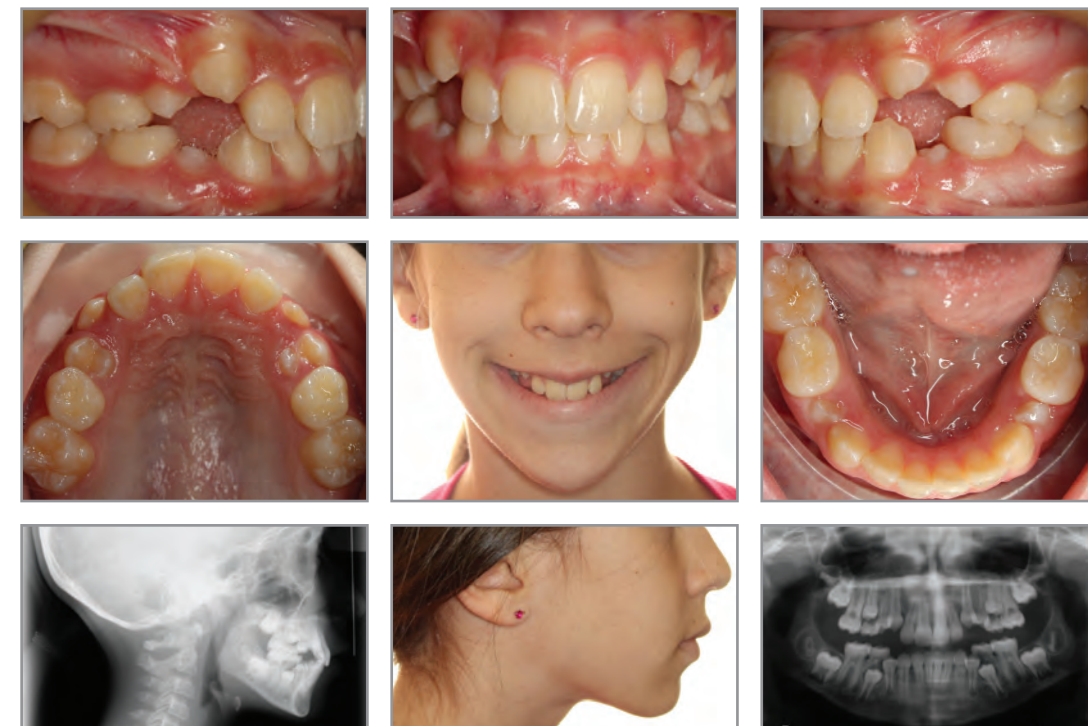

Dr. Kurt Silberstein
Silberstein Orthodontics
Highland Park, IL

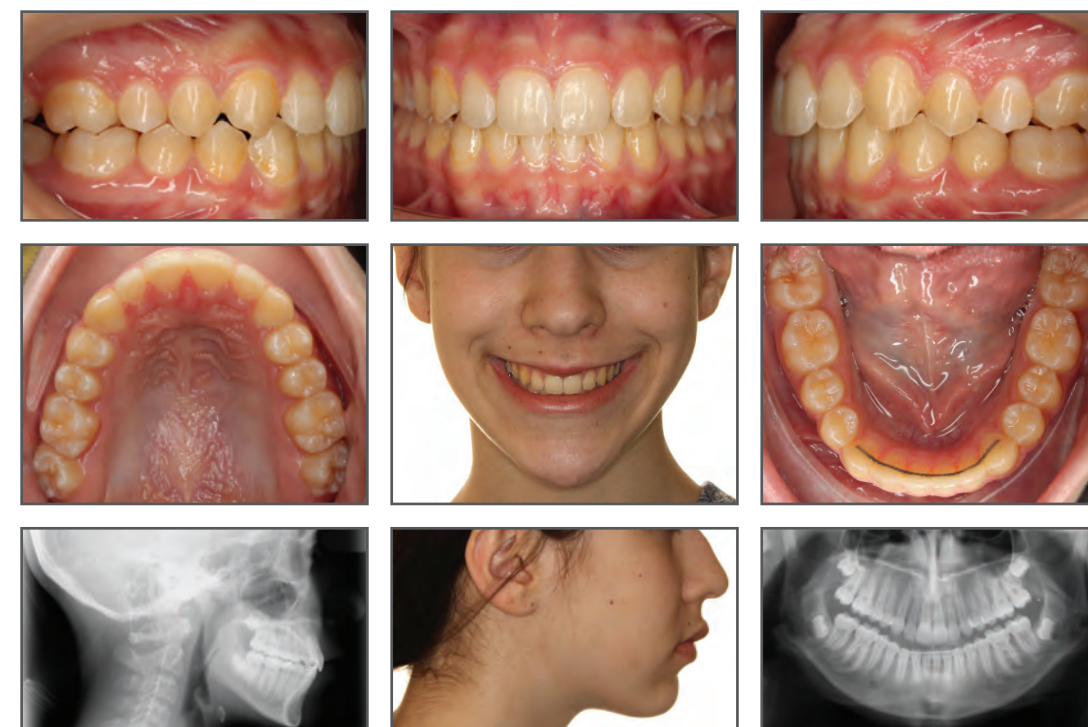www.silbortho.com

TREATMENT SUMMARY

PATIENT	12-year-old female
CHIEF CONCERN	The patient's concern was wanting straight teeth.
DIAGNOSIS	Right: Class I Left: Class I Steep mandibular plane angle. High upper canines positioned labially in the arch. Unerupted and ectopically-positioned lower 5's and 7's.
LENGTH OF TREATMENT	29 months
# OF ALIGNERS USED	Upper: 12 + 13 + 19 Lower: 12 + 13 + 19
ADDITIONAL TREATMENT	None
RETENTION	Upper: Invisalign® retainer Lower: Last aligner over bonded lingual



BEFORE



AFTER



Dr. Kurt Silberstein
Silberstein Orthodontics
Highland Park, IL

www.silbortho.com

TREATMENT SUMMARY

PATIENT 35-year-old female

CHIEF CONCERN Mandibular crowding was the primary concern (orthodontic relapse from orthodontic treatment as a child). The open bite was a secondary concern.

DIAGNOSIS
Right: Class I
Left: Class I

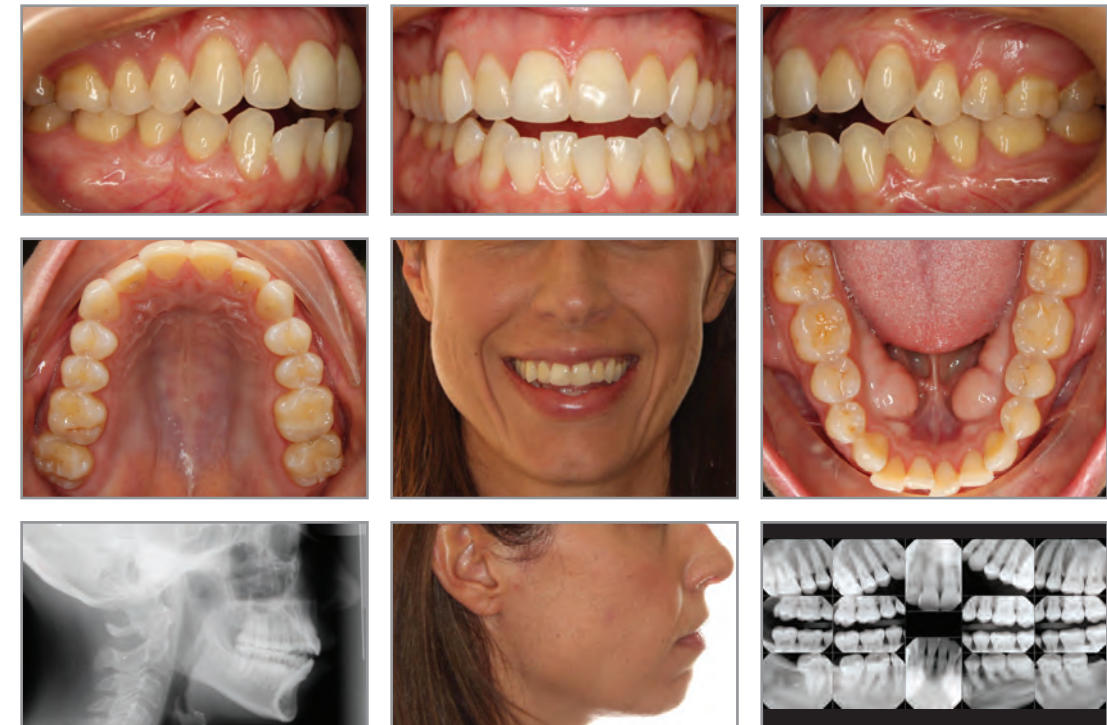
Moderate lower crowding and mild upper crowding, with a reverse curve of Spee and large mandibular tori present. Anterior open bite from first premolar to first premolar. Minimal overjet, with the lower midline shifted to the left. Convex profile, with good facial symmetry and balance.

LENGTH OF TREATMENT 22 months

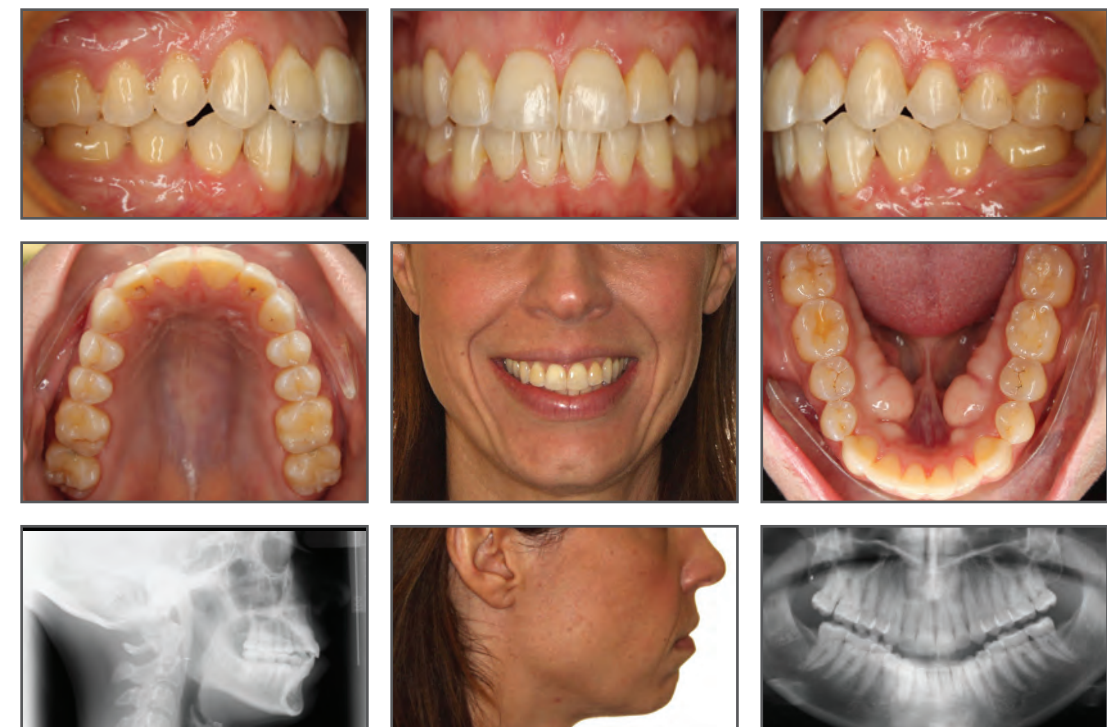OF ALIGNERS USED
Upper: 17 + 16
Lower: 17 + 16

ADDITIONAL TREATMENT None

RETENTION
Upper: Vivera®
Lower: Vivera®



BEFORE



AFTER



Dr. Manuel Sousa
Salem Centre for Orthodontix
Salem, NH

www.smilenh.com

TREATMENT SUMMARY

PATIENT 39-year-old female

CHIEF CONCERN Anterior open bite, the appearance of her smile, a speech impediment, and inadequate space for dental implants. The patient had been told by three other dental practitioners that surgery was needed and that Invisalign was not an option.

DIAGNOSIS Right: Class I
Left: Class I

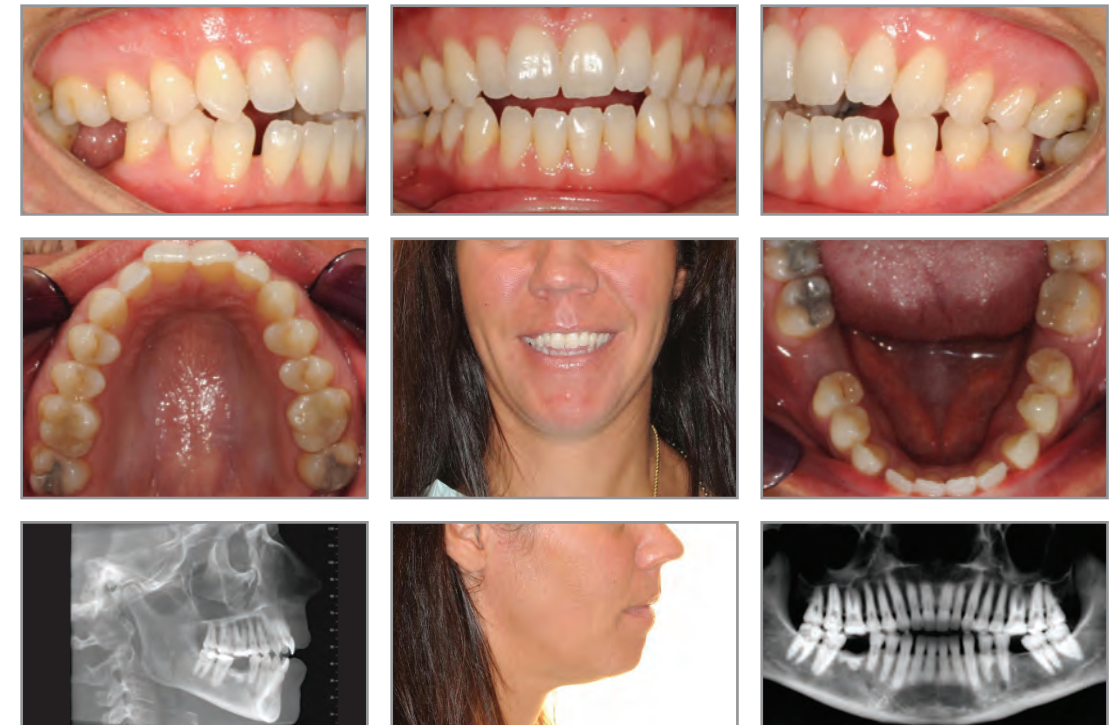4-5 mm anterior open bite. Mild to moderate upper crowding and lower spacing. Noticeable midline discrepancy. Signs of tongue thrust. Maxillary third molars had been removed in hopes of bite closure (but no improvement was noted). Root fragment of #30 was left in place to preserve the bone in that area.

LENGTH OF TREATMENT 22 months

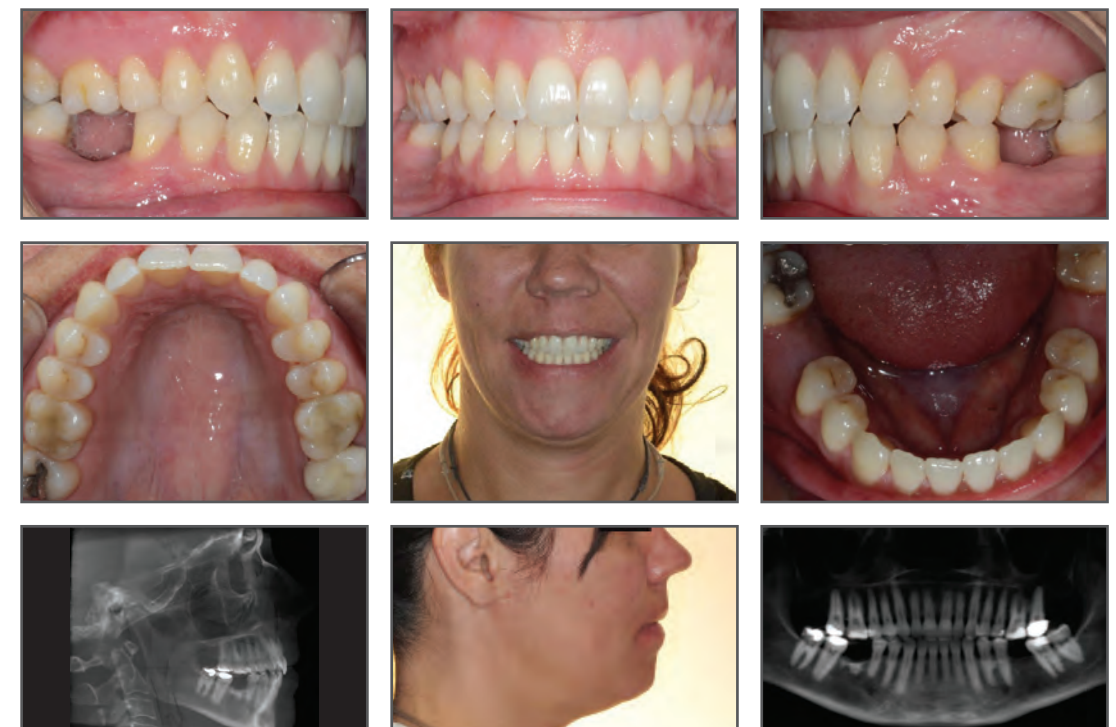OF ALIGNERS USED Upper: 23 + 15
Lower: 23 + 15

ADDITIONAL TREATMENT None

RETENTION Upper: Other clear
Lower: Other clear



BEFORE



AFTER

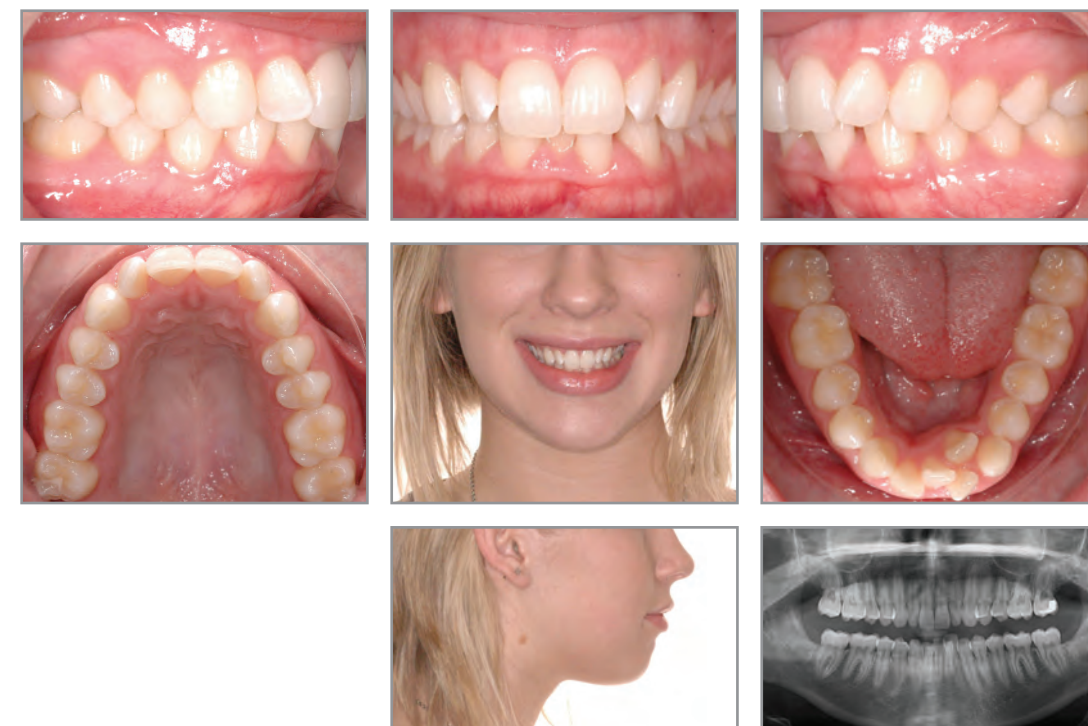


Dr. John Sparaga
Clear Smiles Alaska
Anchorage, AK

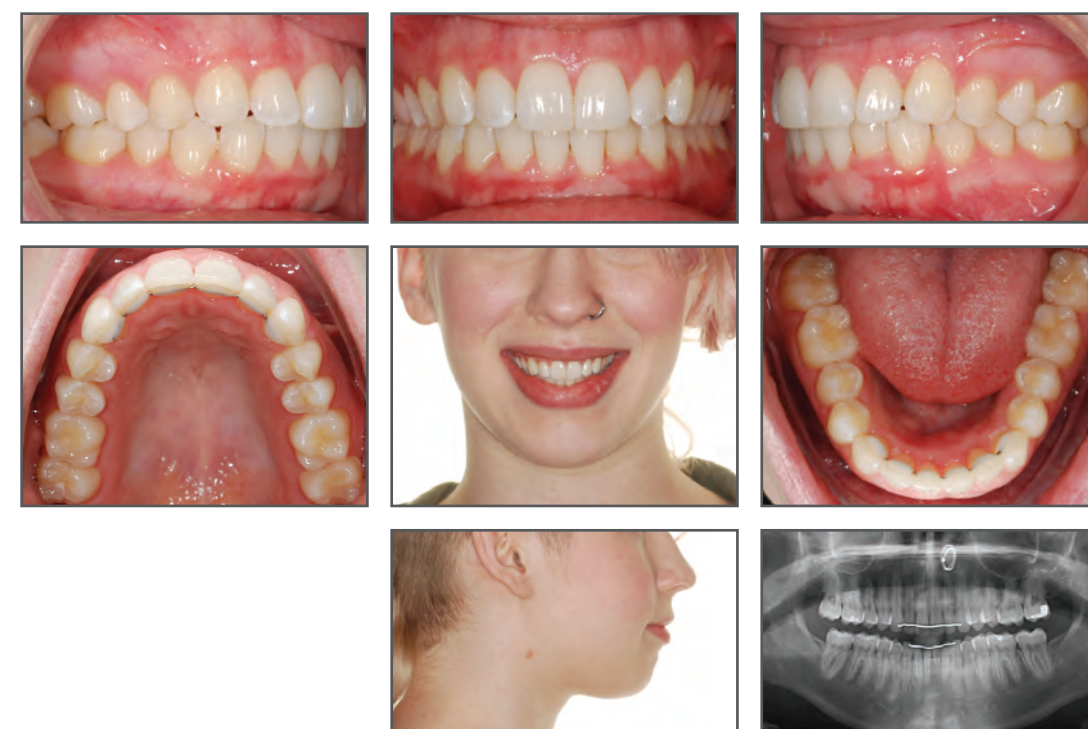www.clearsmilesalaska.com

TREATMENT SUMMARY

PATIENT	18-year-old female
CHIEF CONCERN	Smile aesthetics, lower dental crowding ("overlapped" teeth), and upper lateral incisor rotations.
DIAGNOSIS	Right: Class I Left: Class I Deep bite, blocked-out tooth #23, and maxillary and mandibular crowding.
LENGTH OF TREATMENT	34 months
# OF ALIGNERS USED	Upper: 20 Lower: 42
ADDITIONAL TREATMENT	Vertical seating elastics were used for six months to extrude a non-tracking tooth #7. Elastics were connected from a bonded clear hook to an elastic hook + button in the aligner. A soft tissue graft was completed for labial of #24 during treatment to ensure adequate periodontal support.
RETENTION	Upper: Bonded lingual Lower: Bonded lingual



BEFORE



AFTER



Dr. John Sparaga
Clear Smiles Alaska
Anchorage, AK

www.clearsmilesalaska.com

TREATMENT SUMMARY

PATIENT 15-year-old female

CHIEF CONCERN The patient was concerned about her deep bite, crowded dentition, and smile aesthetics.

DIAGNOSIS
Right: Class I
Left: Class I

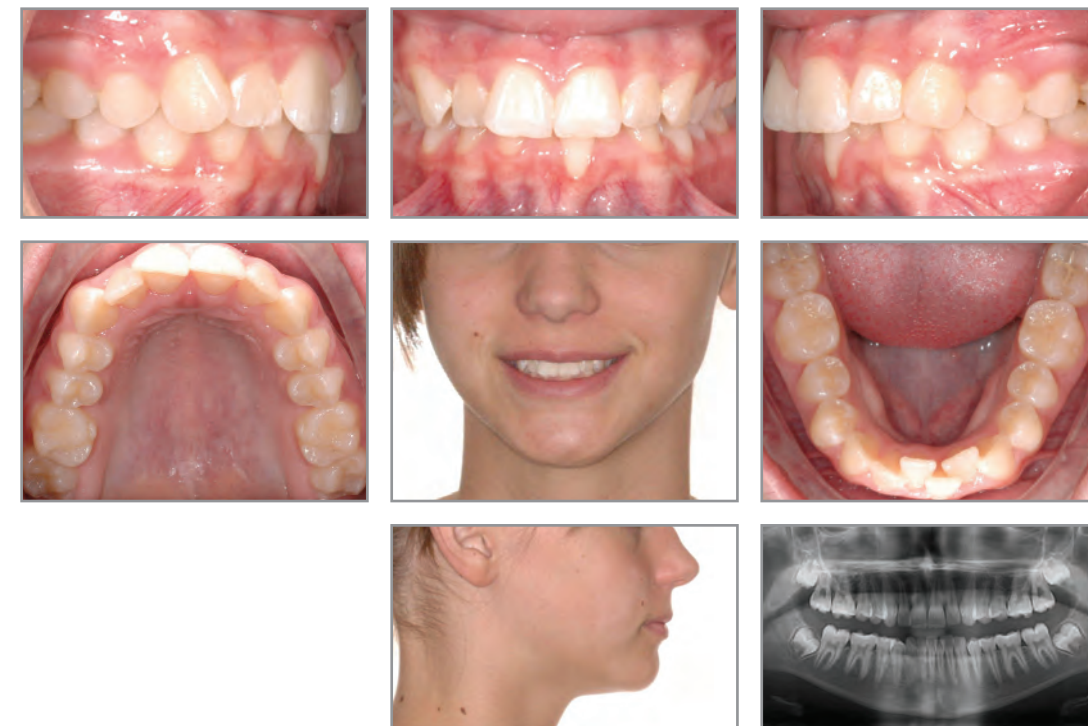
Maxillary and mandibular crowding, with anterior deep bite. Gingival stripping around tooth #24.

LENGTH OF TREATMENT 46 months

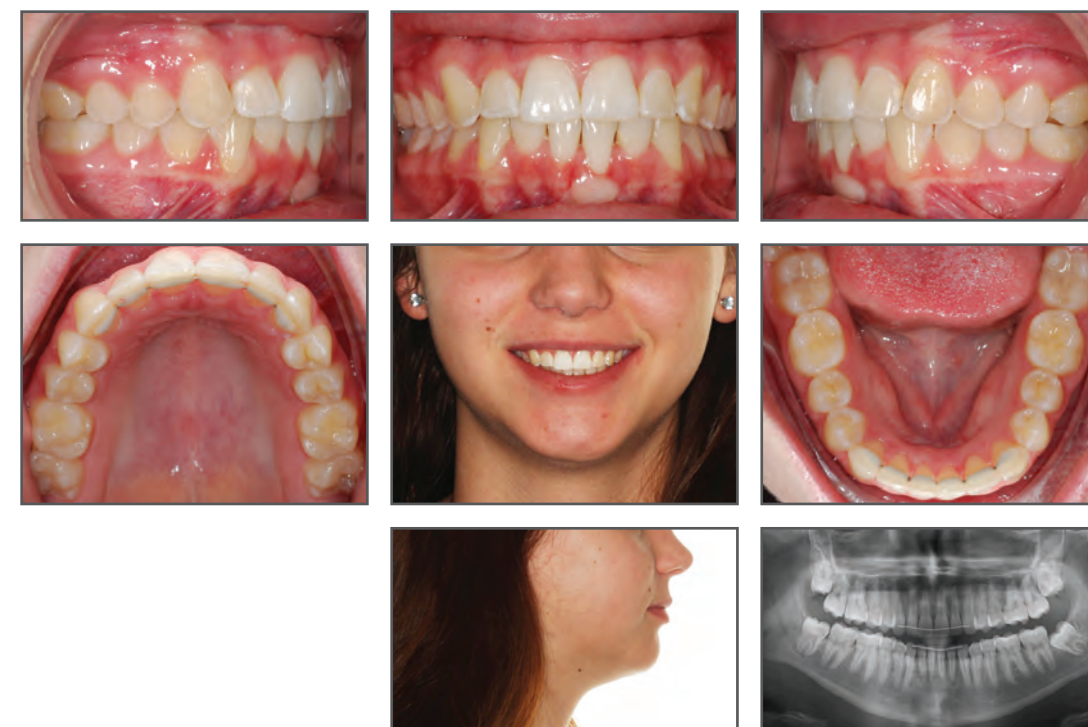
OF ALIGNERS USED
Upper: 25 + 32 + 16
Lower: 25 + 32 + 19

ADDITIONAL TREATMENT Vertical seating elastics were used to extrude non-tracking teeth #7 and #10 for 6 months, from clear hooks bonded on the teeth to buttons in the aligners. Gingival graft completed for tooth #24.

RETENTION
Upper: Bonded lingual
Lower: Bonded lingual



BEFORE



AFTER



Dr. Jason Tam
MCO Orthodontics
Markham, ON, Canada

www.mcosmiles.com

TREATMENT SUMMARY

PATIENT 13-year-old female

CHIEF CONCERN "When I close my mouth, it looks like it's open."

DIAGNOSIS
Right: Class I
Left: Class I

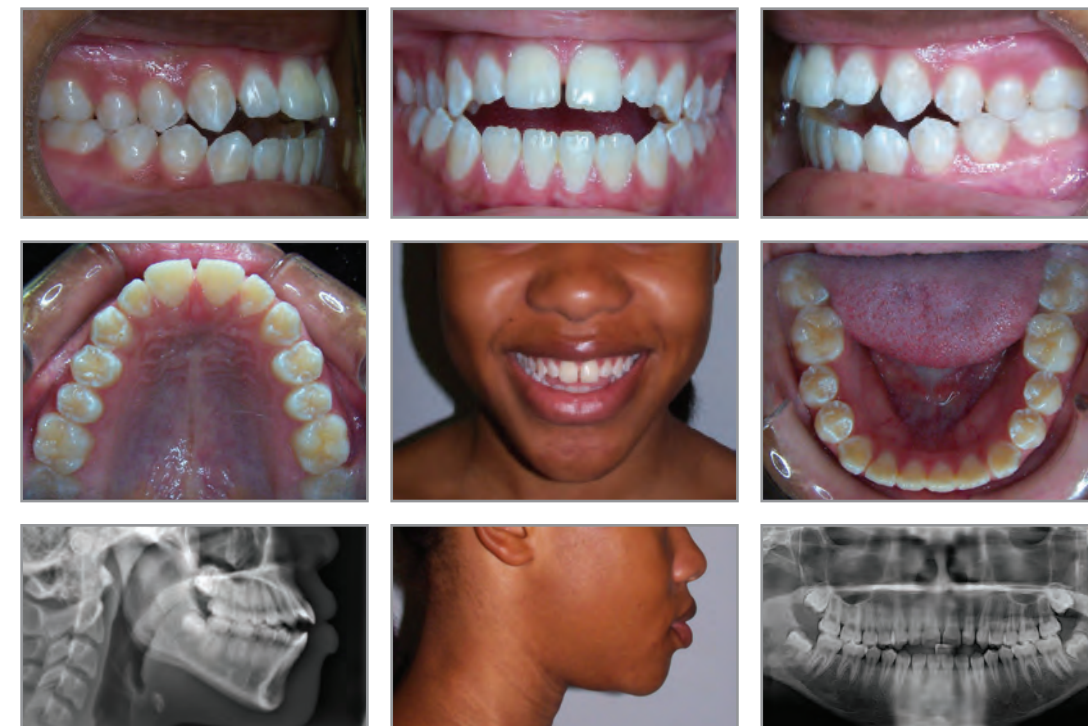Bimaxillary protrusive profile, with a unilateral posterior crossbite on the right side, 4 mm anterior open bite, and a 2 mm diastema. Mild upper and lower spacing, with a tongue thrust on swallowing.

LENGTH OF TREATMENT 24 months

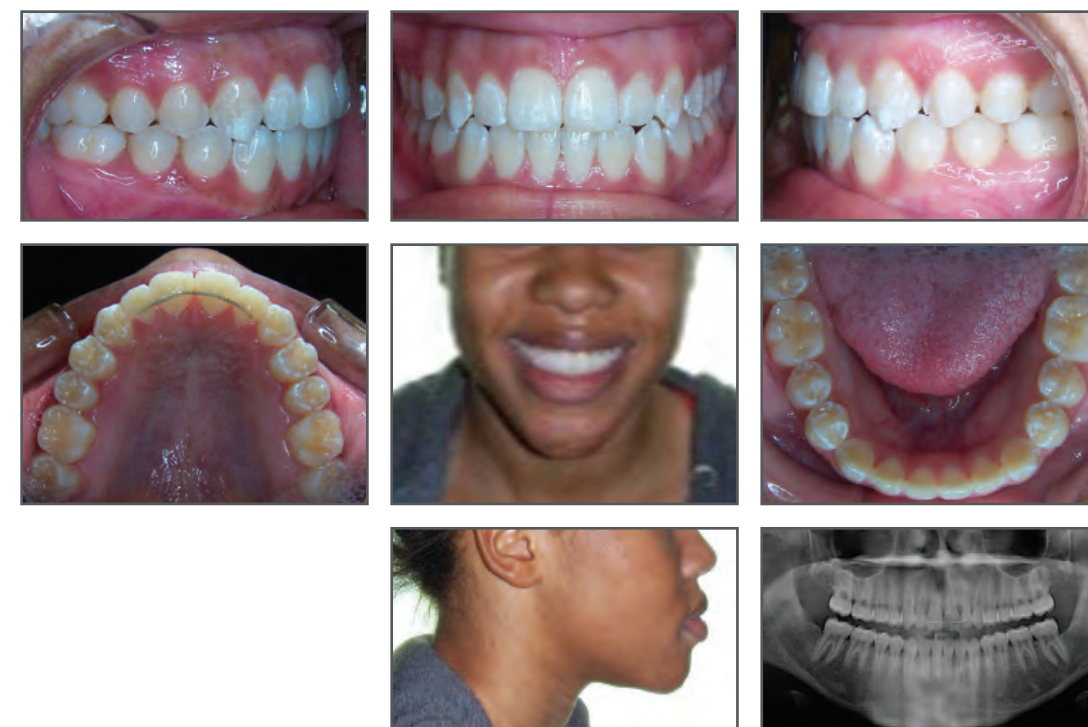OF ALIGNERS USED
Upper: 37 + 10
Lower: 37 + 10

ADDITIONAL TREATMENT None

RETENTION
Upper: Vivera® over bonded lingual
Lower: Vivera®



BEFORE



AFTER



Dr. Samie Thabet
Thabet Orthodontics
Germantown, MD

www.thabetorthodontics.com

TREATMENT SUMMARY

PATIENT 38-year-old male

CHIEF CONCERN The patient did not like his smile, and it was difficult to clean his teeth with floss due to the crowding.

DIAGNOSIS
Right: Class I
Left: Class I

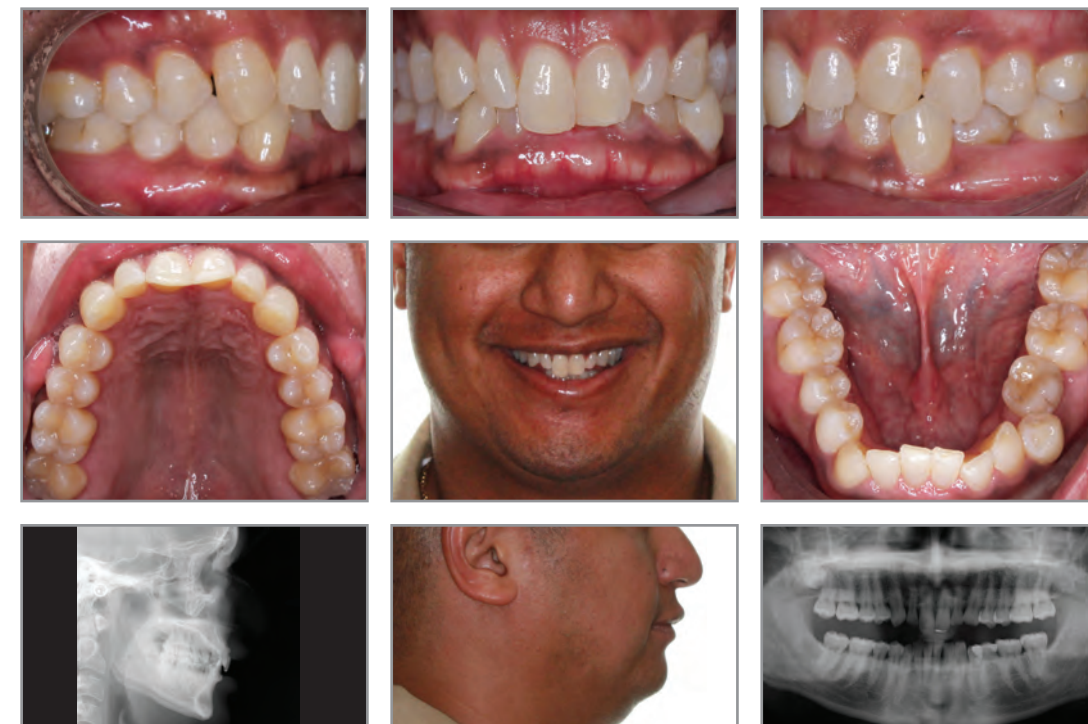Missing mandibular left 2nd premolar, with retained primary molar. Moderate crowding in the upper arch and severe crowding in the lower arch. Severe impinging overbite and normal overjet. Mandibular midline shifted to the right.

LENGTH OF TREATMENT 23 months

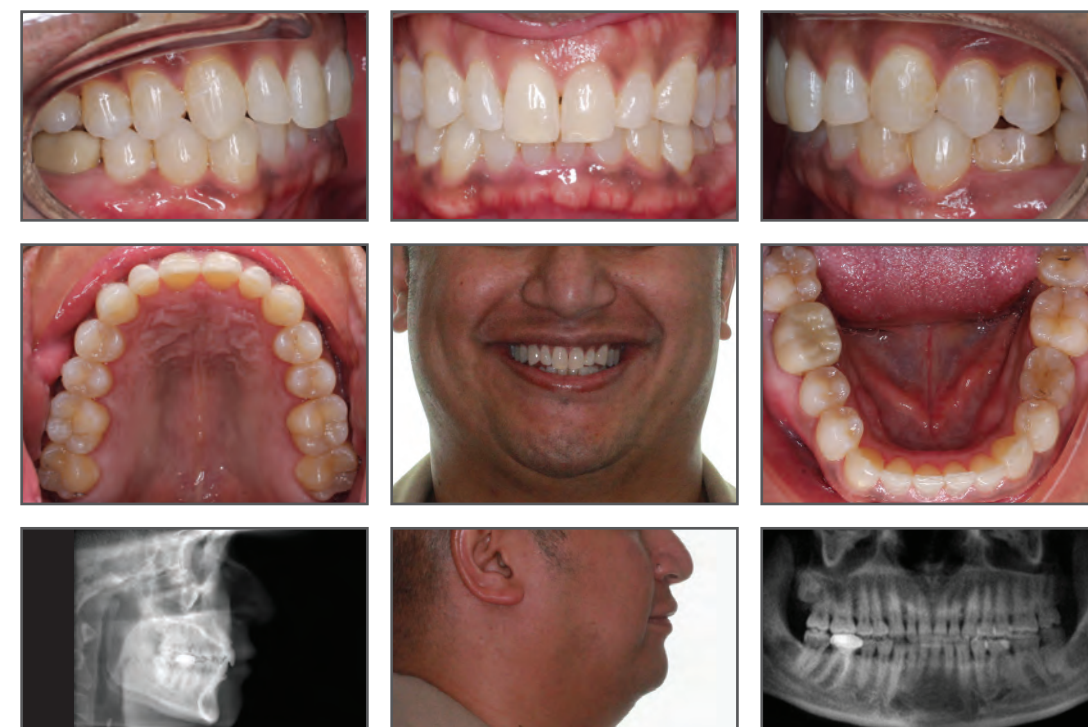OF ALIGNERS USED
Upper: 40 + 20 + 30
Lower: 40 + 20 + 30

ADDITIONAL TREATMENT None

RETENTION
Upper: Vivera®
Lower: Vivera®




BEFORE



AFTER

CLASS II TREATMENTS





Dr. Nahal Ashouri
Nahal Ashouri, DDS, MS
Mountain View, CA

www.DrAshouri.com

TREATMENT SUMMARY

PATIENT 23-year-old female

CHIEF CONCERN The patient's main concern was her crooked teeth.

DIAGNOSIS Right: Class II
Left: Class II

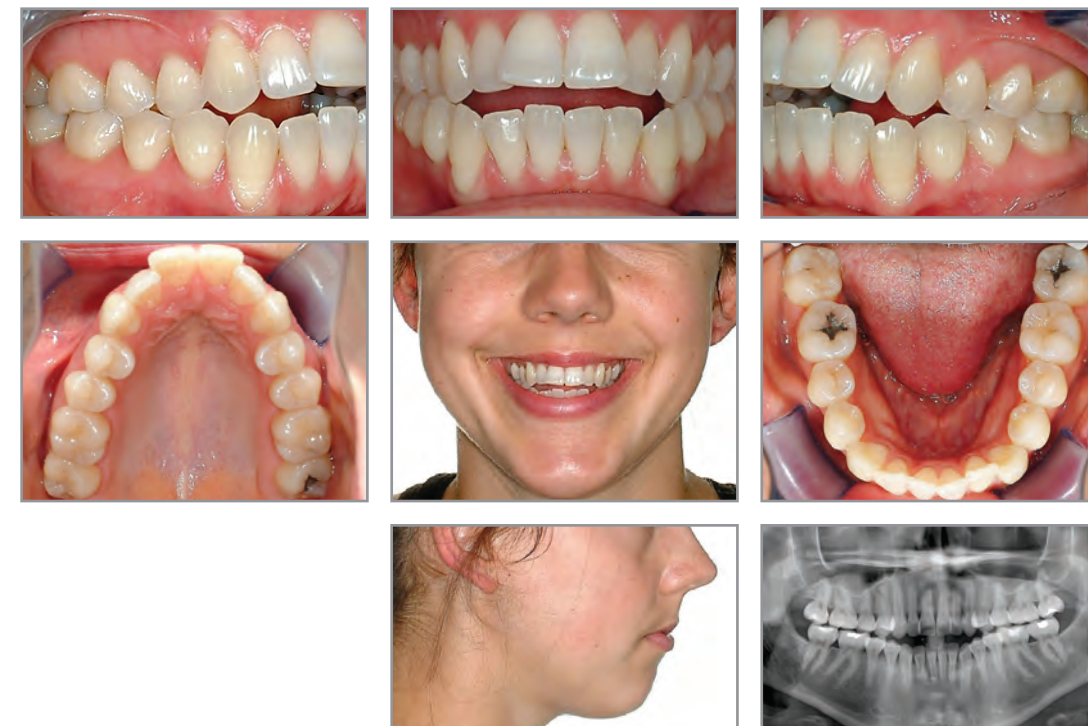Class II tendency, with anterior open bite and excessive overjet. Maxillary and mandibular crowding.

LENGTH OF TREATMENT 18 months

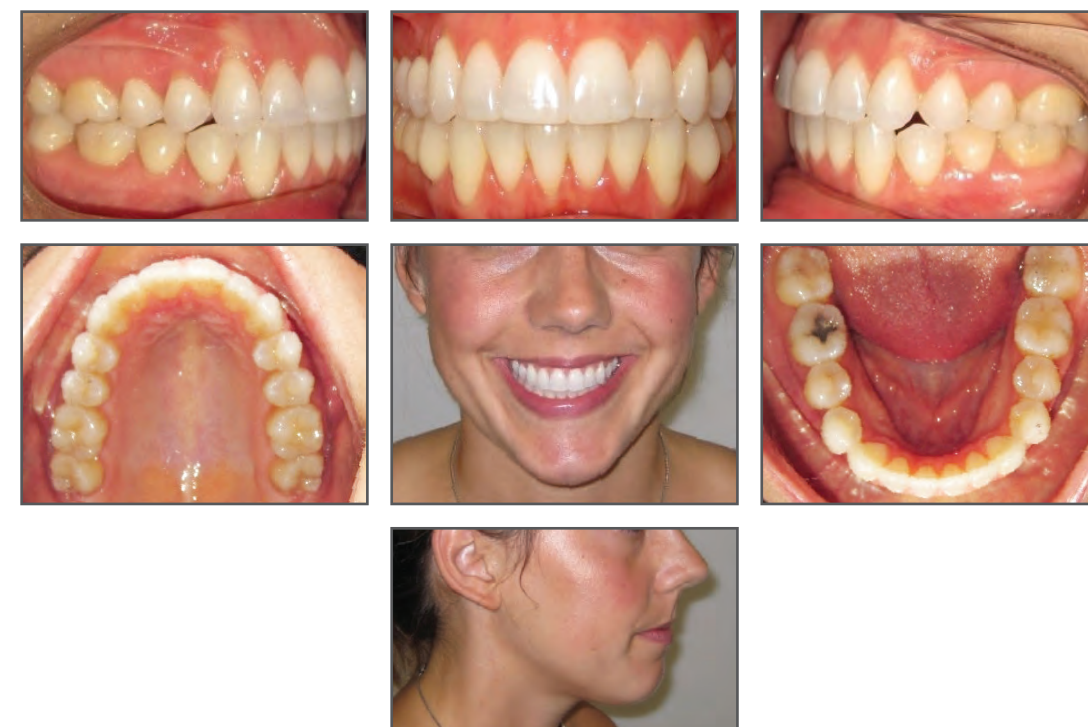OF ALIGNERS USED Upper: 49 + 28
Lower: 49 + 28

ADDITIONAL TREATMENT Class II elastics were used throughout the duration of treatment, with hooks cut into the upper aligners near the canines and buttons bonded to the lower first molars.

RETENTION Upper: Other clear
Lower: Other clear



BEFORE



AFTER

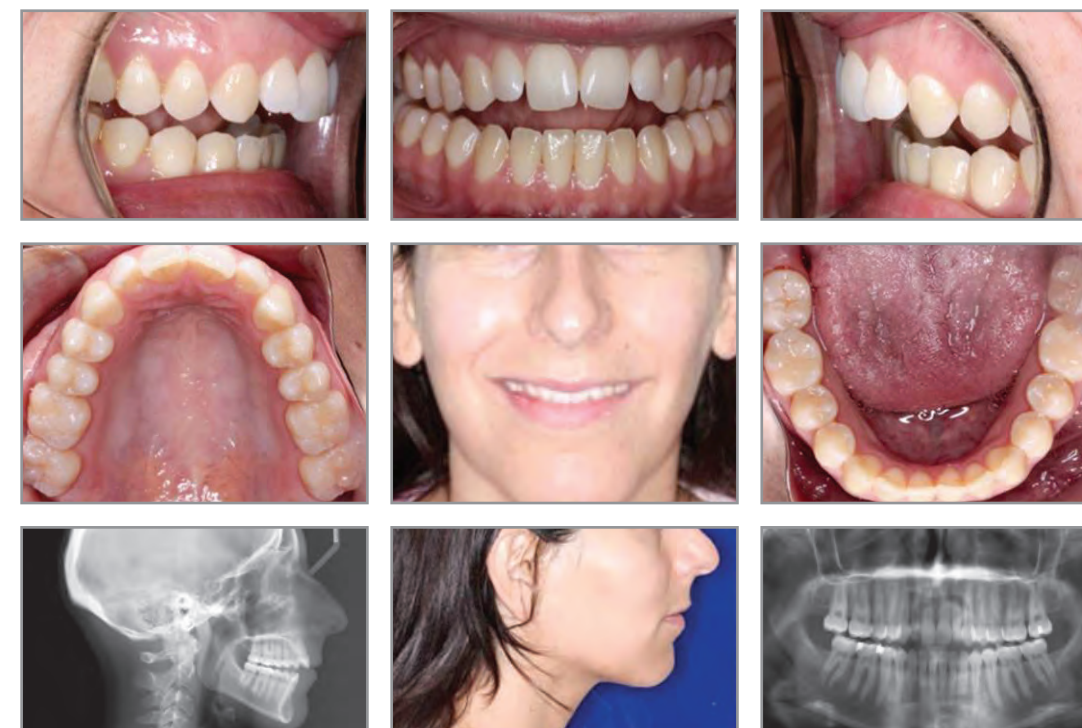

Dr. Patricia Bendick
Fairfield Orthodontic Associates
Fairfield, CT

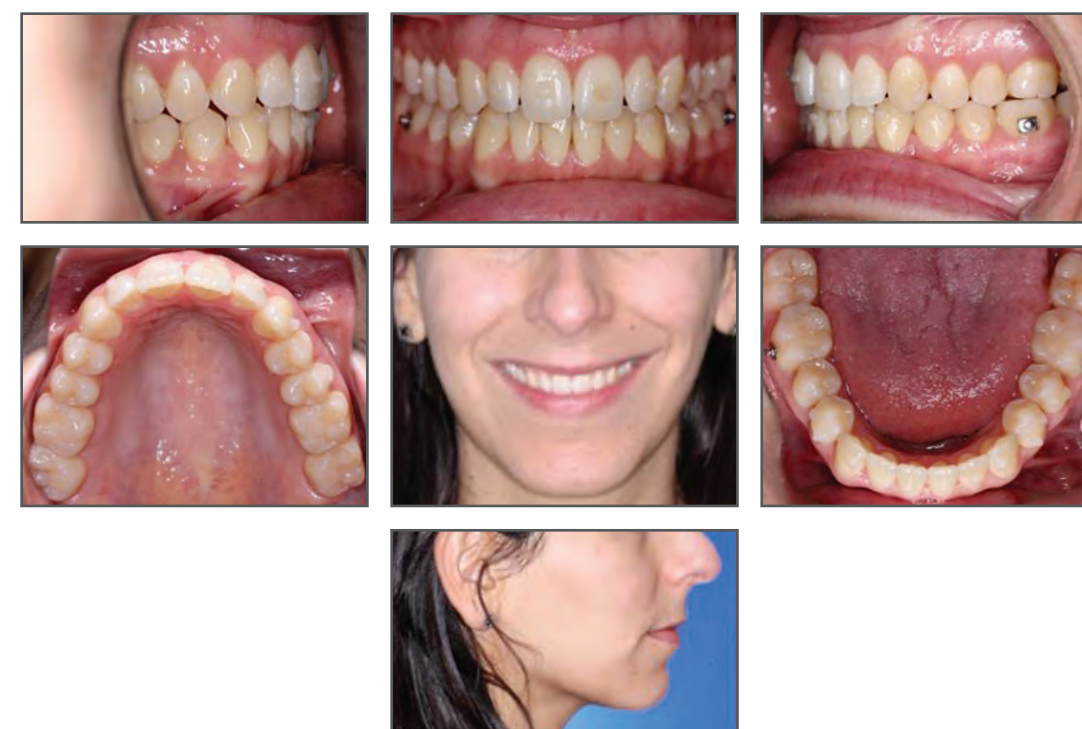www.fairfieldorthodonticassociates.com

TREATMENT SUMMARY

PATIENT	19-year-old female
CHIEF CONCERN	The patient cannot bite into food with her incisors.
DIAGNOSIS	Right: Class II Left: Class II Severe anterior and posterior open bite and severe overjet.
LENGTH OF TREATMENT	6 months
# OF ALIGNERS USED	Upper: 14 Lower: 14
ADDITIONAL TREATMENT	Class II elastics were used for 6 months, with hooks cut into the aligners near the upper cuspid and buttons bonded to the lower first molars.
RETENTION	Upper: Last aligner for 6 months, followed by Vivera® Lower: Last aligner for 6 months, followed by Vivera®



BEFORE



AFTER

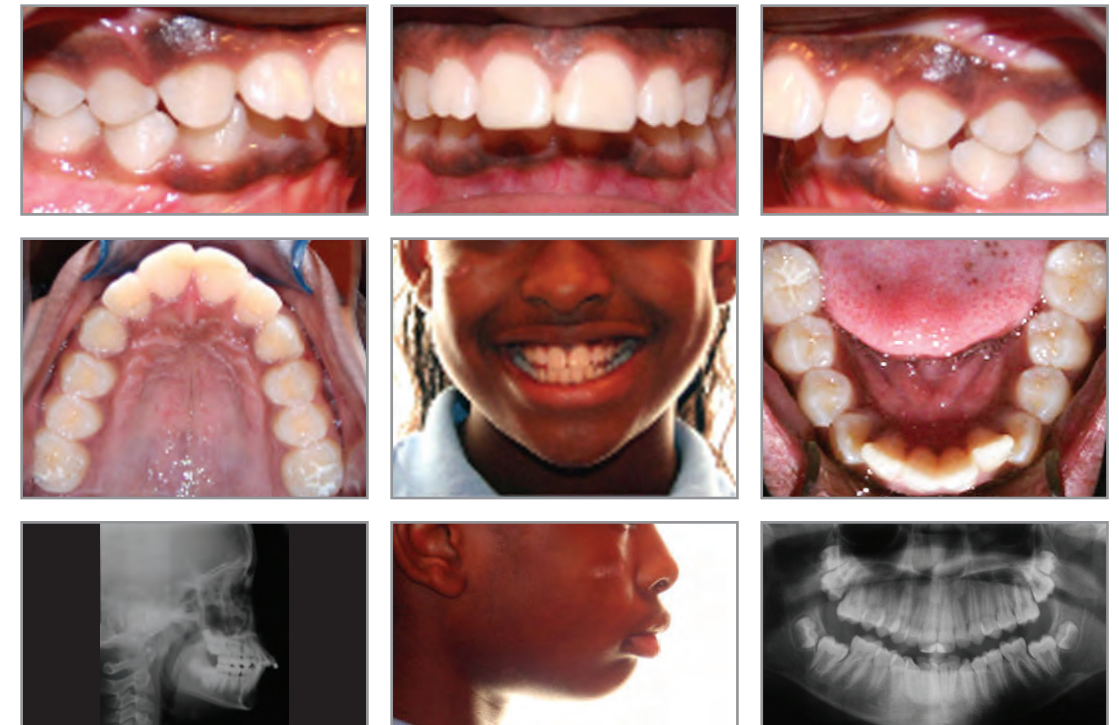

Dr. Bartley Benson
Benson Orthodontics
Mount Juliet, TN

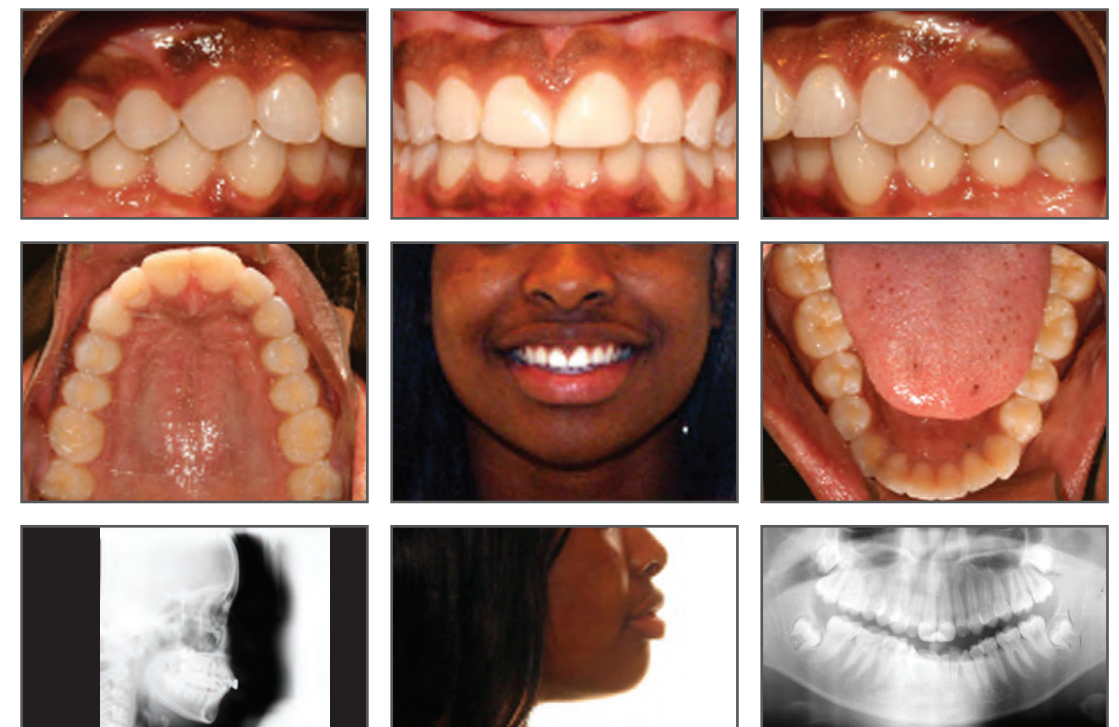
www.bensonorthodontics.com

TREATMENT SUMMARY

PATIENT	14-year-old female
CHIEF CONCERN	Protruded upper front teeth with excessive overjet, and crooked lower front teeth. Patient needed a treatment option compatible with her singing and performing career.
DIAGNOSIS	Right: Class II Left: Class II Division 1 malocclusion with protruded maxillary incisors, 6 mm overjet, and deep overbite. Moderate lower anterior crowding.
LENGTH OF TREATMENT	6 months Phase I treatment + 16 months Phase II Invisalign treatment
# OF ALIGNERS USED	Upper: 26 Lower: 26
ADDITIONAL TREATMENT	Phase 1 treatment with a Twin Block functional appliance.
RETENTION	Upper: Last aligner Lower: Last aligner



BEFORE



AFTER

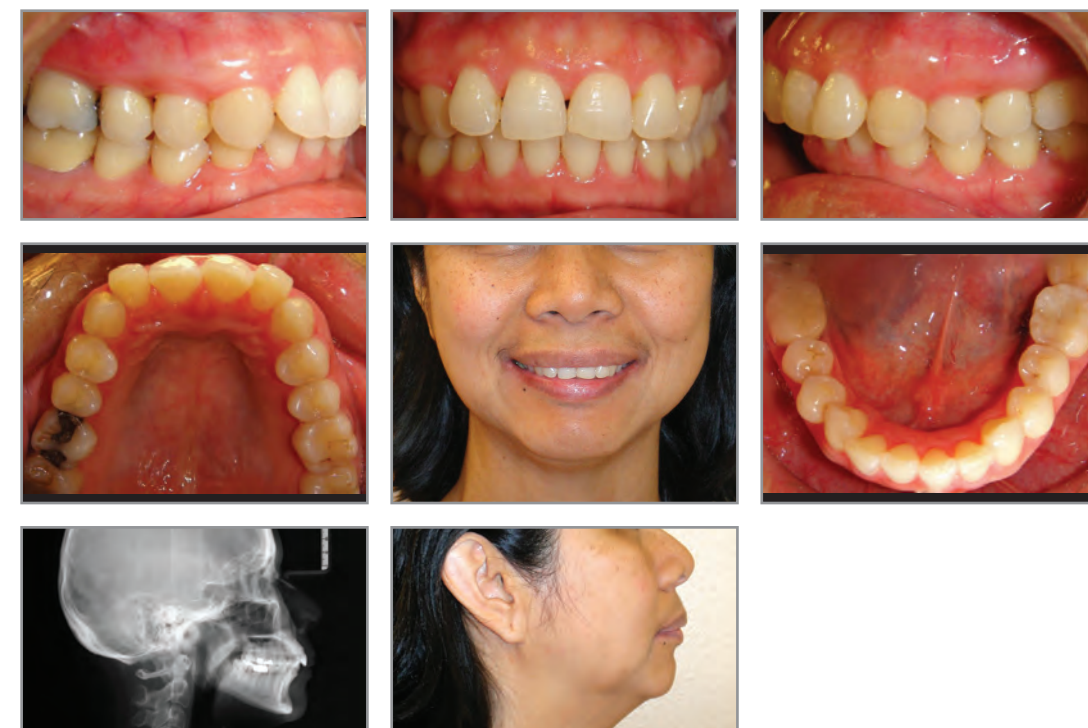

Dr. Sujata Bhatia
Kihei Orthodontics
Kihei, HI

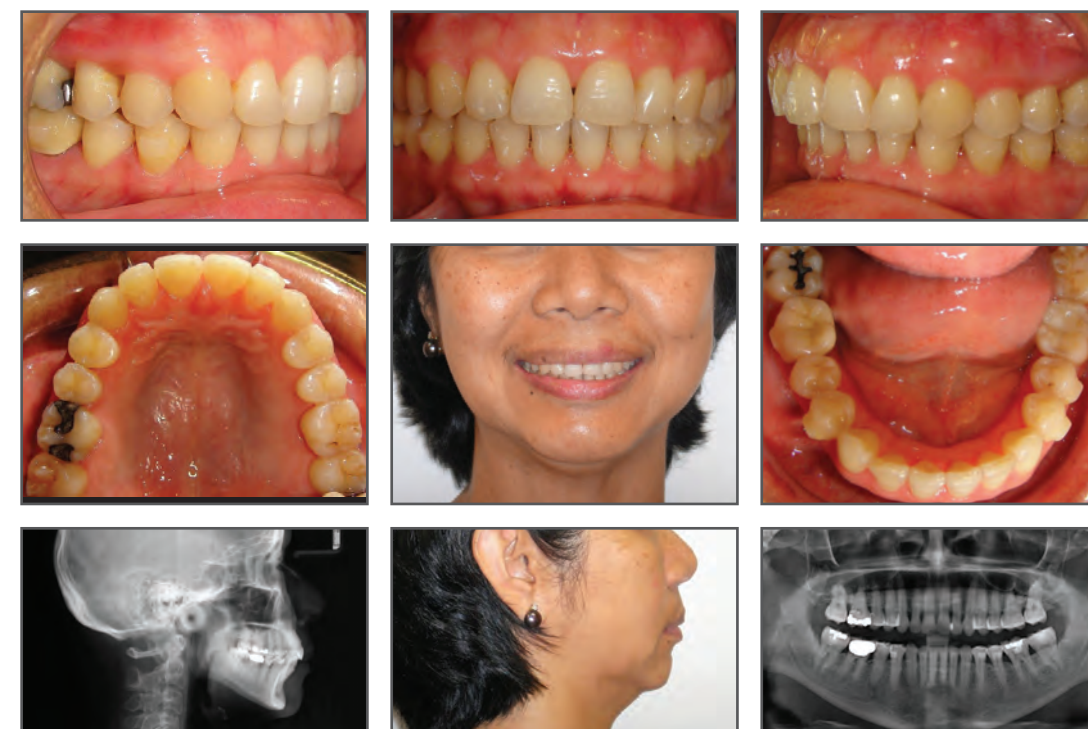www.kiheiorthodonticsmaui.com

TREATMENT SUMMARY

PATIENT	52-year-old female
CHIEF CONCERN	A desire to discontinue using the anterior repositioning splint that she had been wearing for over 5 years.
DIAGNOSIS	Right: Class II Left: Class II Patient is unable to function without her anterior repositioning splint. Frequent headaches and jaw soreness.
LENGTH OF TREATMENT	26 months
# OF ALIGNERS USED	Upper: 22 + 32 Lower: 22 + 20
ADDITIONAL TREATMENT	None. Vertical elastics were avoided, but the lower attachments were left on during the patient's retention phase to ensure that the extrusion achieved was maintained.
RETENTION	Upper: Last aligner Lower: Last aligner



BEFORE



AFTER

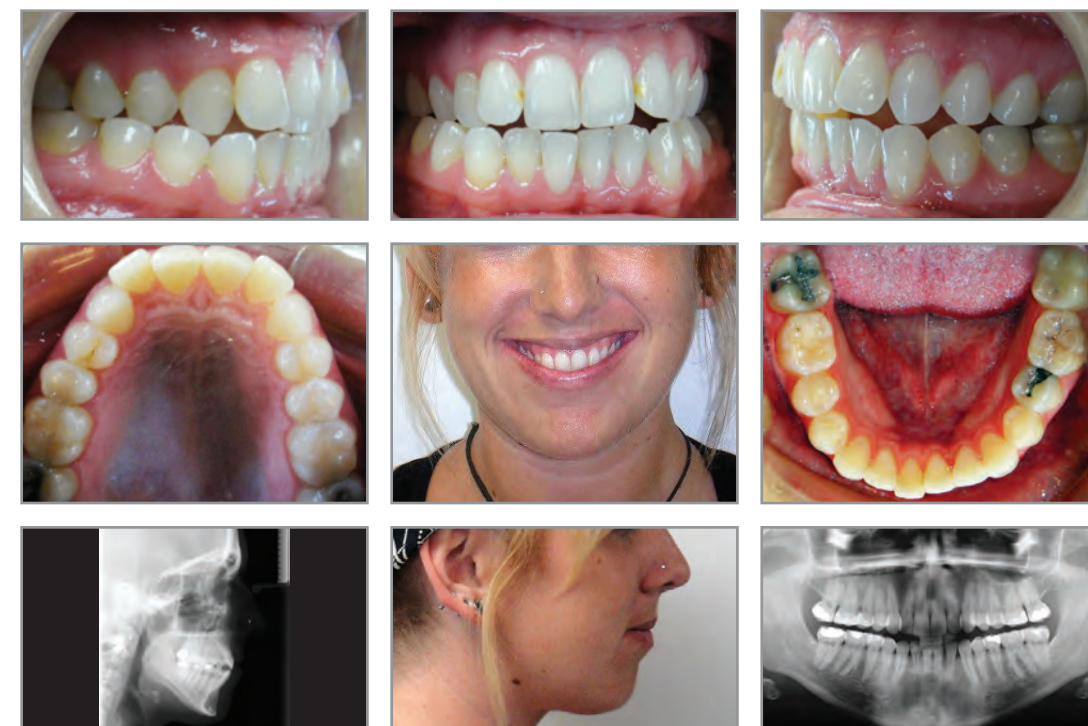

Dr. Sujata Bhatia
Kihei Orthodontics
Kihei, HI

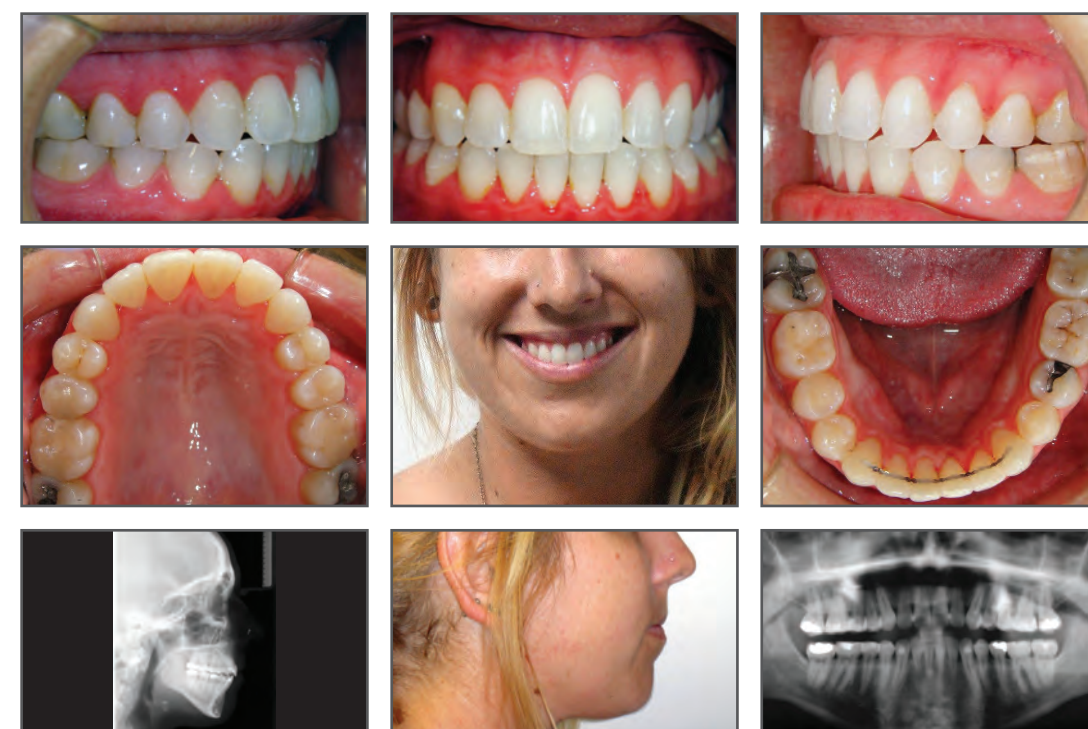www.kiheiorthodonticsmaui.com

TREATMENT SUMMARY

PATIENT	27-year-old female
CHIEF CONCERN	"I am unable to chew my food properly because my teeth don't mesh well."
DIAGNOSIS	Right: Class III Left: Class II Bilateral posterior crossbite, with anterior open bite. Moderate to severe crowding in the upper and lower arches.
LENGTH OF TREATMENT	19 months
# OF ALIGNERS USED	Upper: 39 Lower: 39
ADDITIONAL TREATMENT	None
RETENTION	Upper: Vivera® Lower: Vivera® over bonded lingual



BEFORE



AFTER

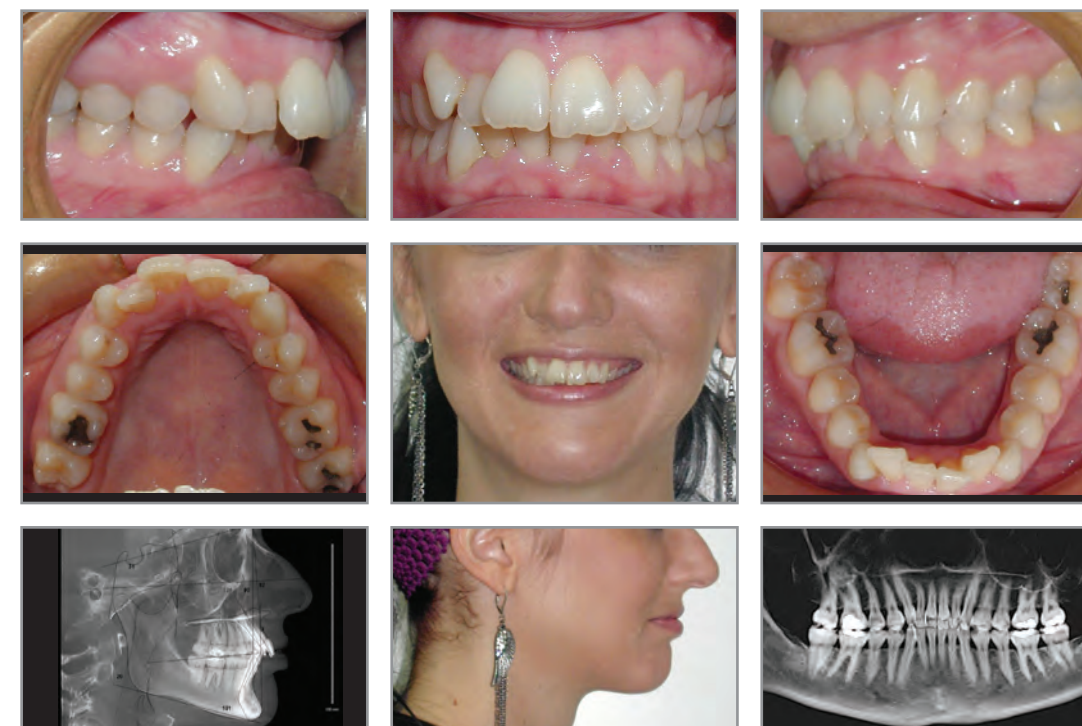

Dr. Charles Brodsky
Brodsky Orthodontics
Lakewood, CA

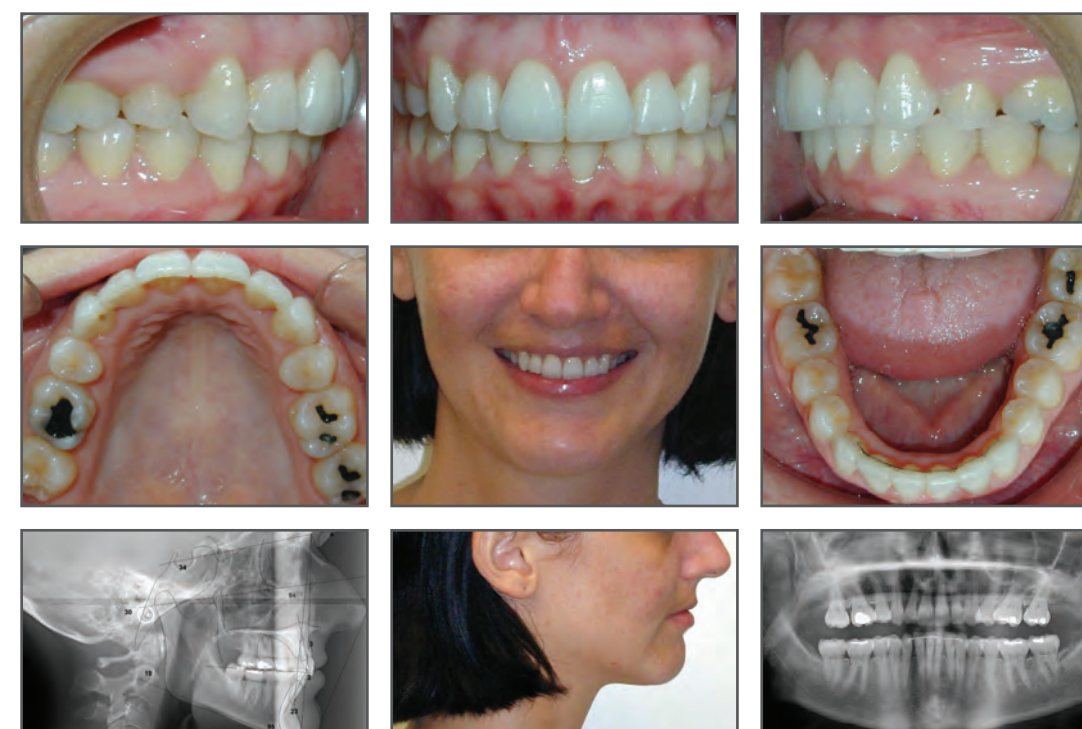www.drbrodskysmile.com

TREATMENT SUMMARY

PATIENT	26-year-old female
CHIEF CONCERN	The crowding of her upper and lower teeth, and the protrusion of the upper front teeth.
DIAGNOSIS	Right: Class II Left: Class II Crowding of the upper and lower teeth. Protruded upper front teeth.
LENGTH OF TREATMENT	27 months
# OF ALIGNERS USED	Upper: 27 + 15 + 13 Lower: 27 + 15 + 13
ADDITIONAL TREATMENT	The upper first bicuspid were extracted.
RETENTION	Upper: Other clear Lower: Bonded lingual



BEFORE



AFTER



Dr. Joseph Ciccio
Ciccio and Demarest Orthodontics
Bronxville, NY

www.nyorthodocs.com

TREATMENT SUMMARY

PATIENT 13-year-old male

CHIEF CONCERN The position of the upper left canine, the “overbite,” and he “does not want braces.”

DIAGNOSIS
Right: Class II
Left: Class II

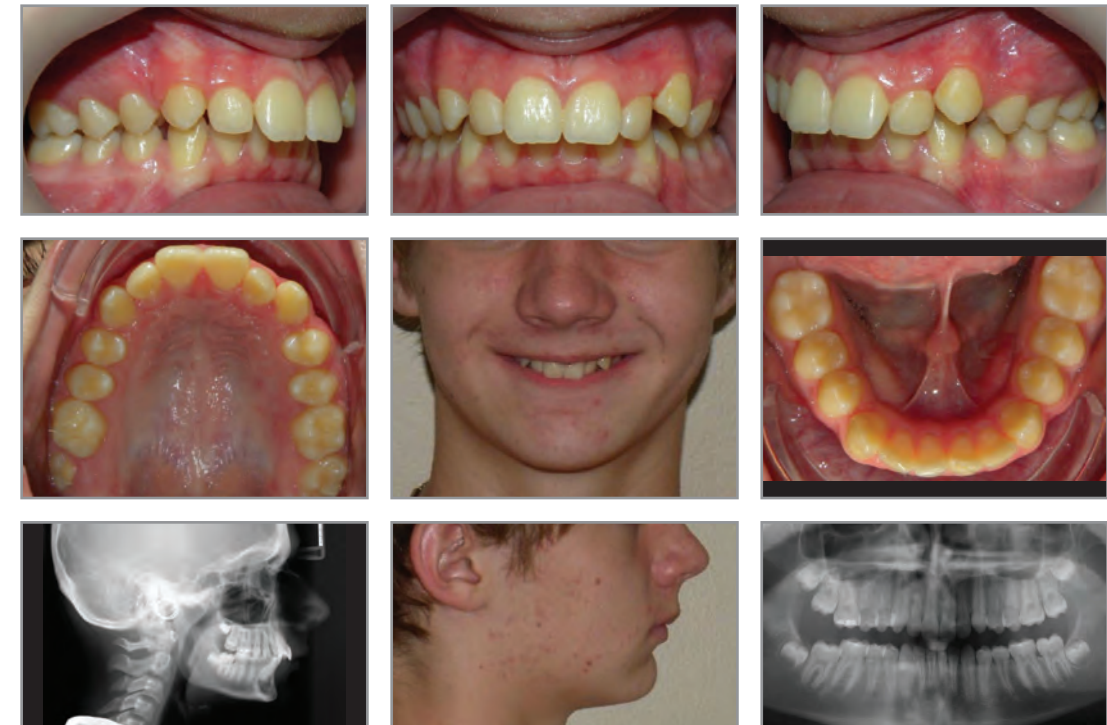
Moderate to severe overjet and overbite. Mild crowding with flared incisors and deep curve of Spee. Retrognathic mandible. Moderately convex profile with obtuse nasolabial angle. Occlusal wear from bruxism. Tipped dental midlines.

LENGTH OF TREATMENT 24 months

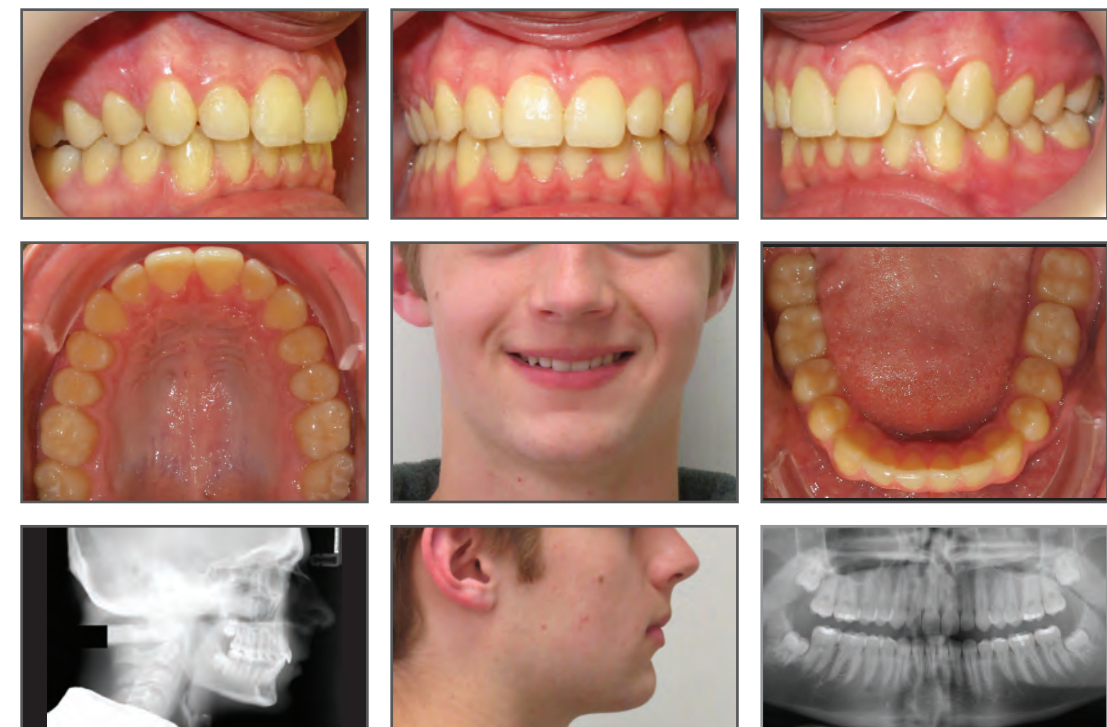
OF ALIGNERS USED
Upper: 17 + 20 + 8
Lower: 17 + 20 + 8

ADDITIONAL TREATMENT Class II elastics were worn part-time for 19 months, with elastic hooks cut into the aligners near the upper canines and lower first molars.

RETENTION
Upper: Invisalign® retainer
Lower: Invisalign® retainer



BEFORE

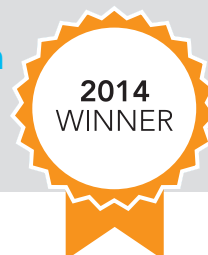

AFTER



Dr. Dustin Coles
Premier Orthodontics
Chandler, AZ

www.premierorthoaz.com



TREATMENT SUMMARY

PATIENT 37-year-old male

CHIEF CONCERN "My teeth are not straight, and I don't like to smile."

DIAGNOSIS
Right: Class II
Left: Class I

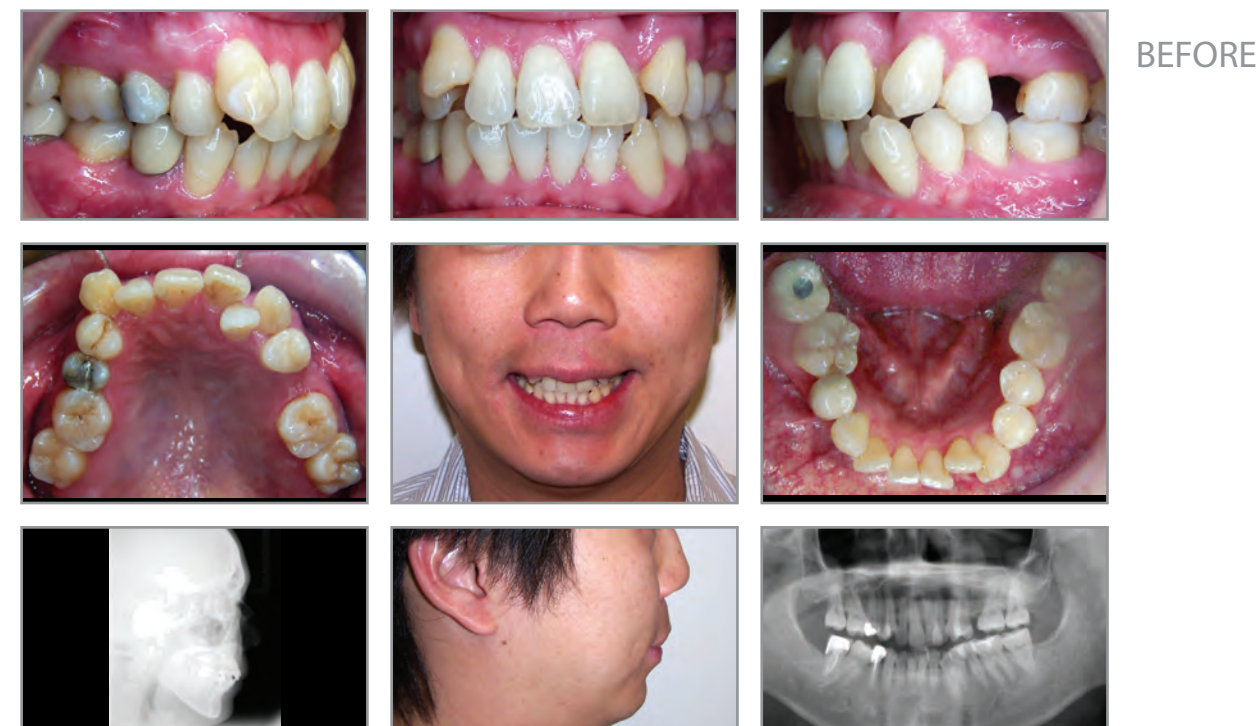Severe upper and lower crowding, with blocked-out upper right canine and lingual crossbite of the upper left lateral incisor. Significant upper midline shift (4 mm) to the left. Edentulous space from missing UL5. LR5 is also missing, but the space is closed.

LENGTH OF TREATMENT 31 months

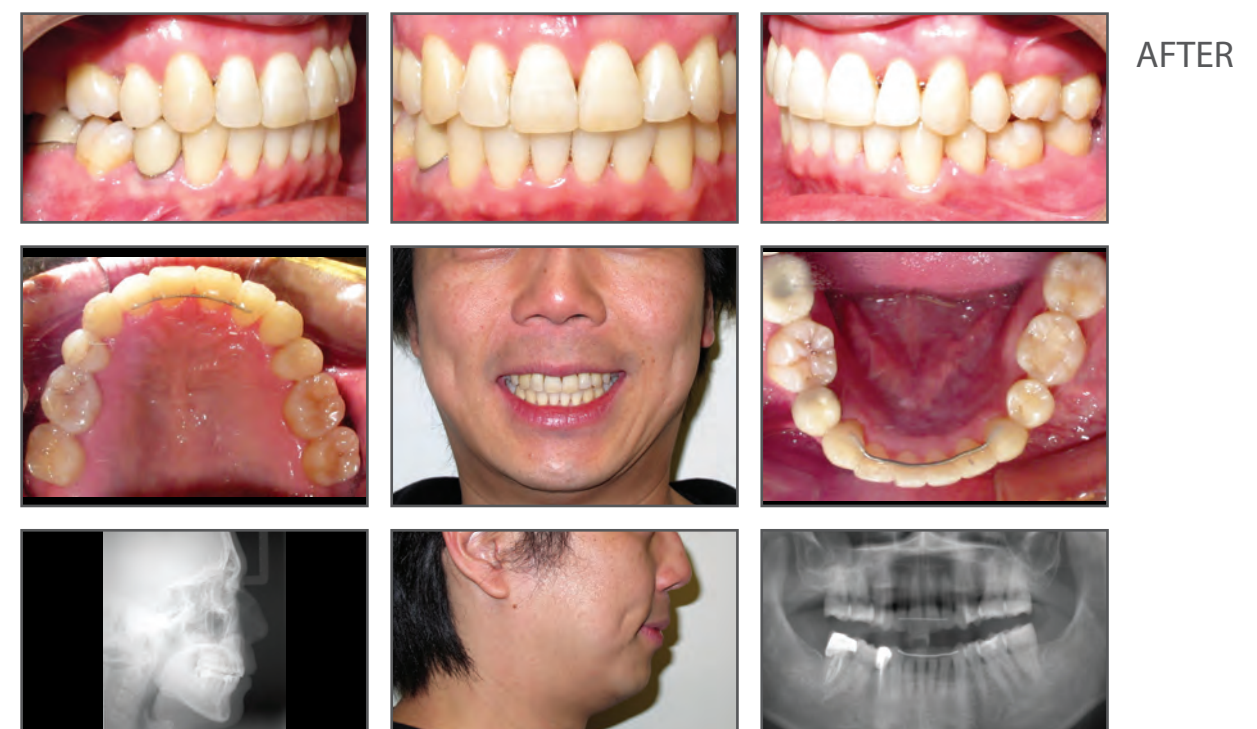OF ALIGNERS USED
Upper: 38 + 28 + 3
Lower: 38 + 28

ADDITIONAL TREATMENT Extracted LL4 and UR5 (instead of the UR4, because of the large existing restoration present). For anchorage control, ligated a TAD in UR 6/7 area to buttons bonded to UR 6/7. Class II elastics were used during the initial series, with hooks cut into the upper aligners near the canines and buttons bonded to the lower first molars.

RETENTION
Upper: Other clear over bonded lingual
Lower: Bonded lingual



BEFORE



AFTER



Dr. Dustin Coles
Premier Orthodontics
Chandler, AZ

www.premierorthoaz.com

TREATMENT SUMMARY

PATIENT 11-year-old female

CHIEF CONCERN The patient does not like to smile because of her “overbite” and “fangs.”

DIAGNOSIS Right: Class II
Left: Class II

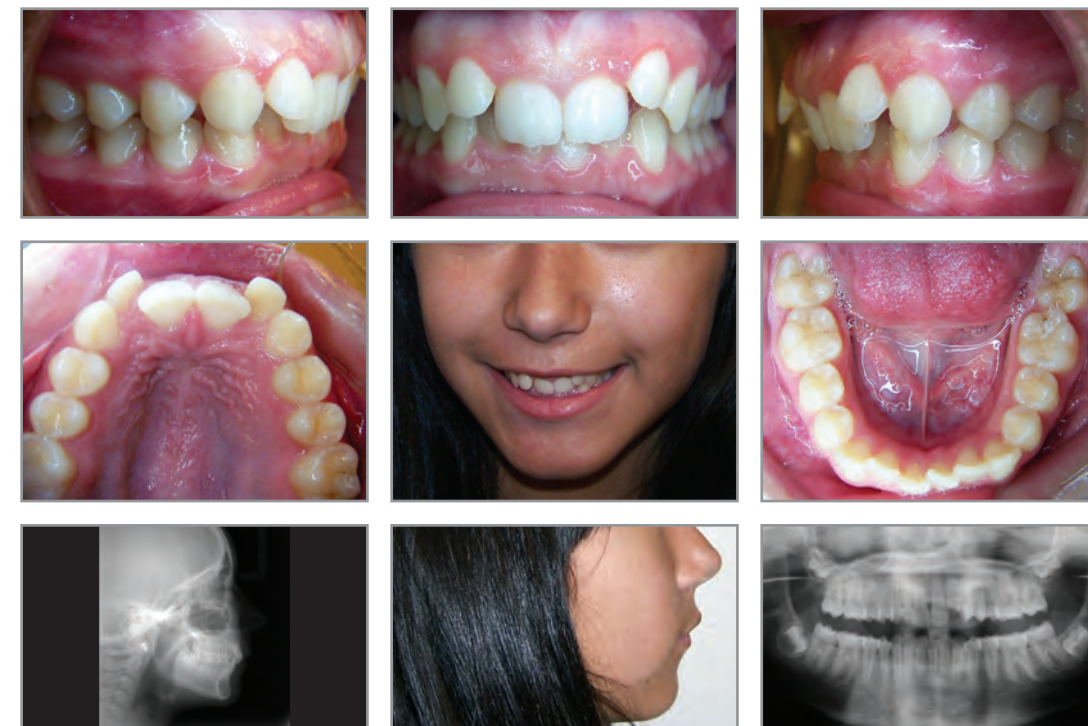Division 2 malocclusion. Crowded upper and lower incisors. 80% deep bite. Excessive overjet (4 mm). Lower midline shifted to the right by 1 mm. Retroclined upper incisors. Retrusive lower lip.

LENGTH OF TREATMENT 20 months

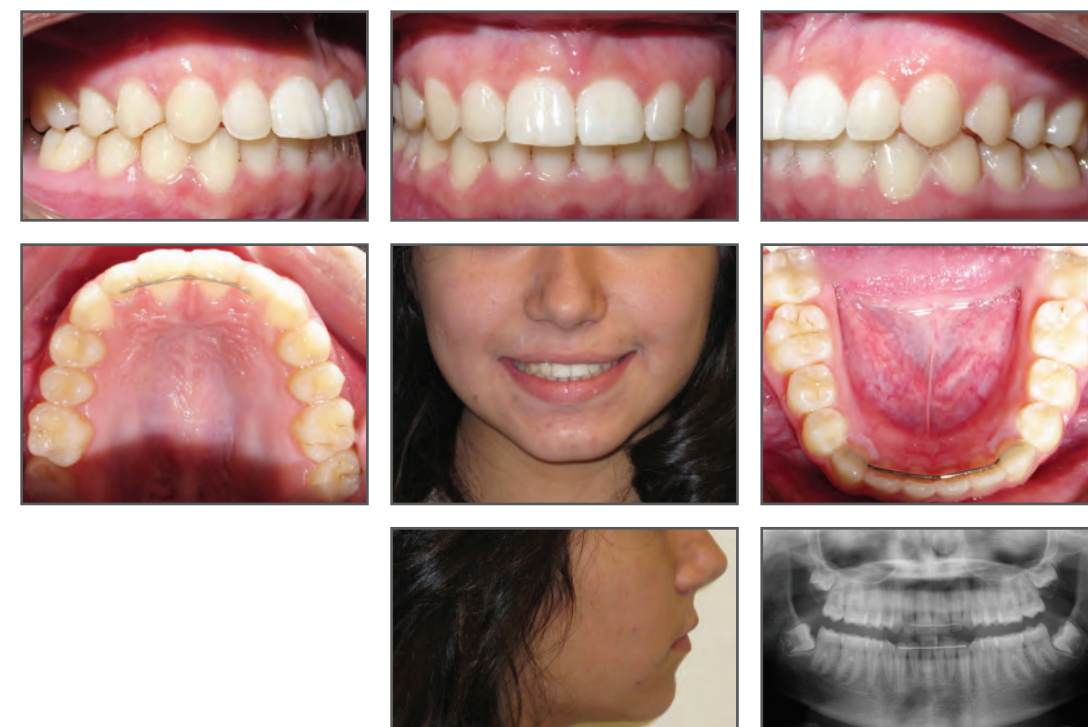
OF ALIGNERS USED Upper: 42
Lower: 42

ADDITIONAL TREATMENT Class II elastics were used for 16 months, with elastic hooks cut into the aligners near the upper cuspids and buttons bonded to the lower first molars.

RETENTION Upper: Other clear over bonded lingual
Lower: Bonded lingual



BEFORE



AFTER



Dr. Linda Crawford
Beaux Sourires, PLLC
Dallas, TX

www.drindacrawford.com

TREATMENT SUMMARY

PATIENT 14-year-old male

CHIEF CONCERN The patient wanted to improve his smile, reduce the overjet, and avoid orthognathic surgery.

DIAGNOSIS
Right: Class II
Left: Class II

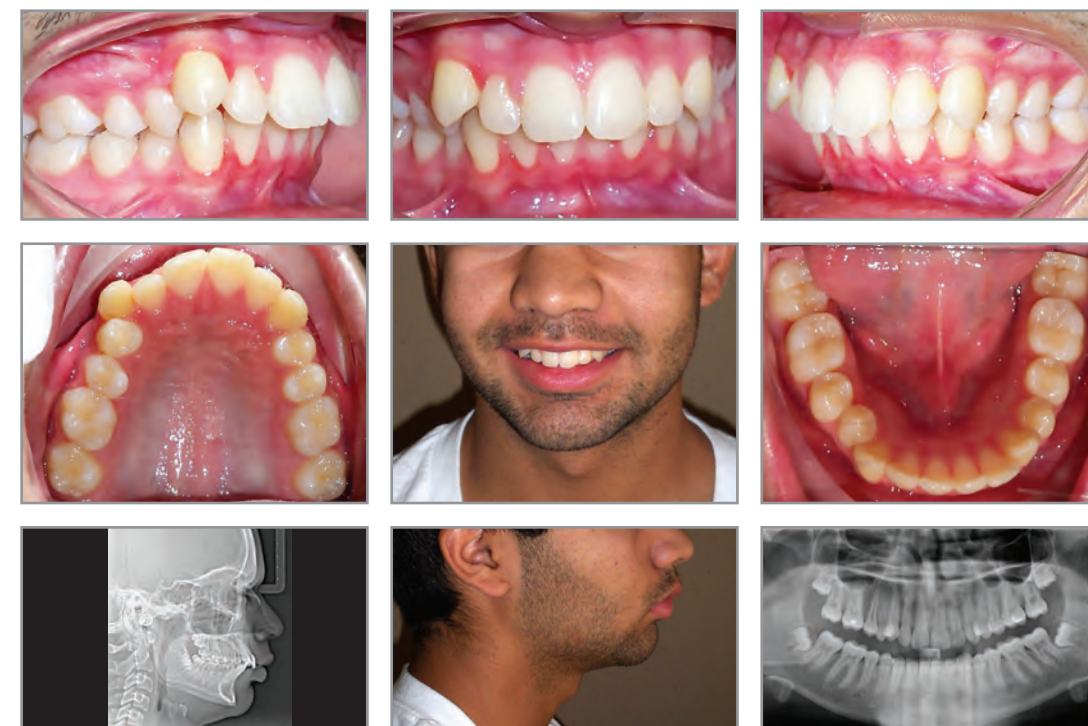
Full step Class II. Increased overbite and overjet. Asymmetric arch forms due to collapsed right buccal segment. Moderately deep curve of Spee. Shifted midline.

LENGTH OF TREATMENT 20 months

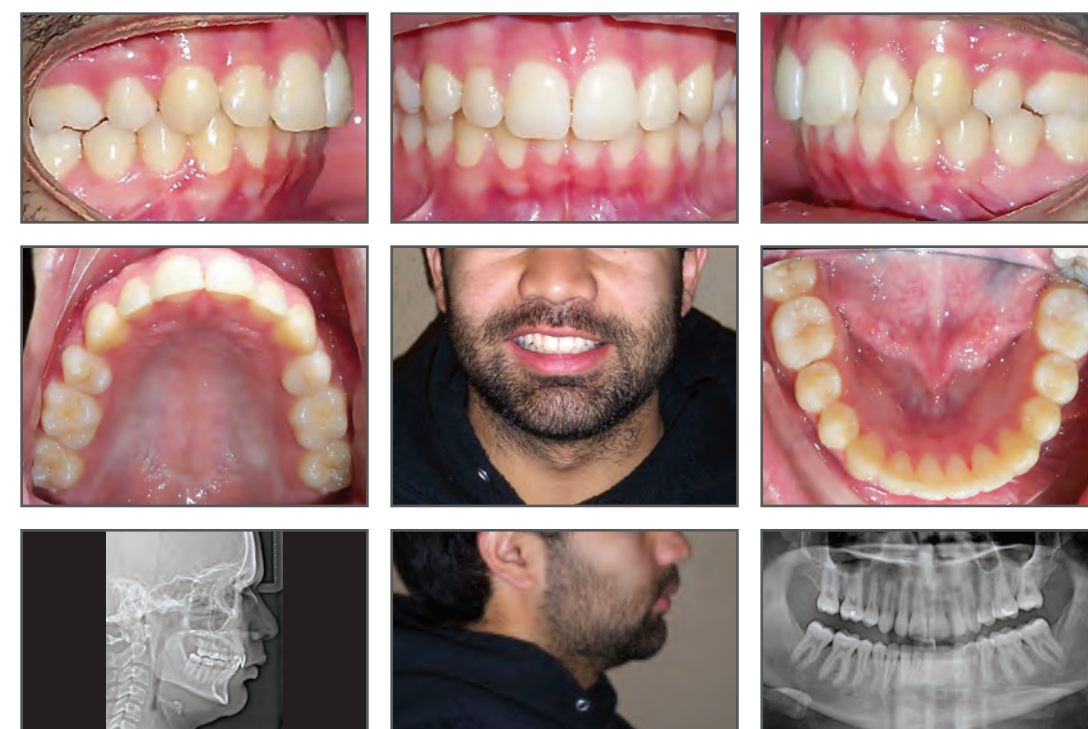OF ALIGNERS USED
Upper: 34
Lower: 34

ADDITIONAL TREATMENT The upper first bicuspid were extracted. Class II and vertical elastics were used for 20 months, with buttons bonded to #3, 6, 11, 14, 19, and 30.

RETENTION
Upper: Last aligner
Lower: Last aligner



BEFORE



AFTER



Dr. Linda Crawford
Beaux Sourires, PLLC
Dallas, TX

www.drindacrawford.com

TREATMENT SUMMARY

PATIENT 26-year-old female

CHIEF CONCERN The patient wanted to improve her smile and reduce the overjet, but without using fixed appliances.

DIAGNOSIS
Right: Class II
Left: Class II

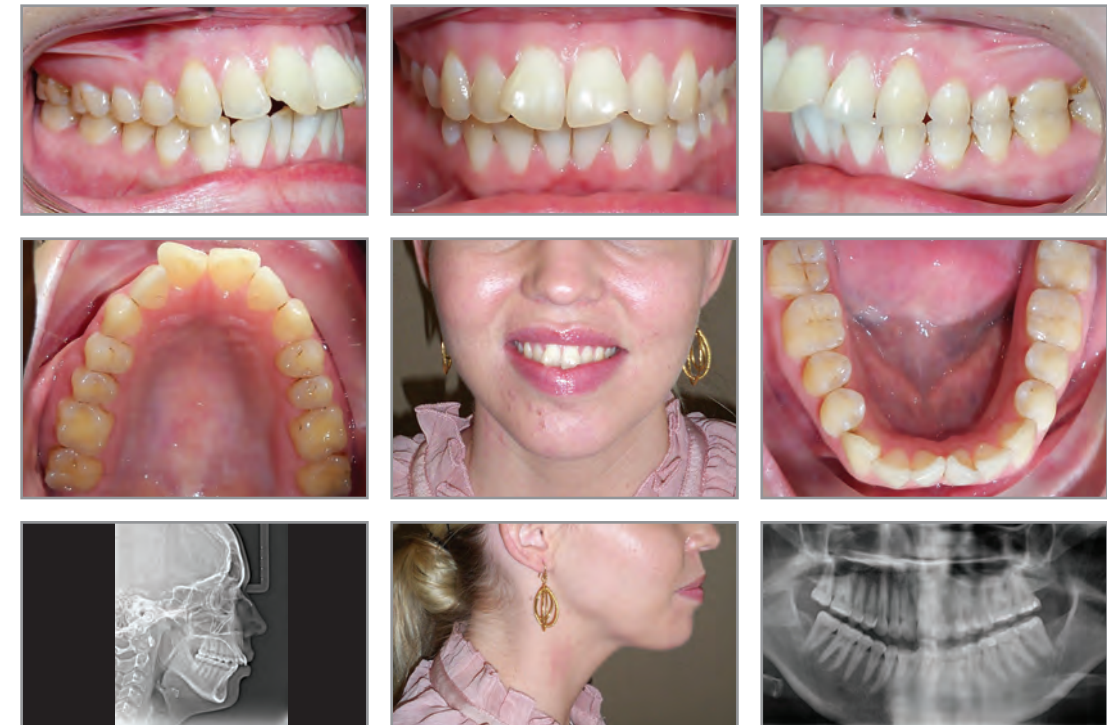Class II skeletal and dental pattern. Increased overjet. Temporomandibular joint symptoms. Flared incisors and crowding. Narrow arch forms. Midline discrepancy.

LENGTH OF TREATMENT 24 months

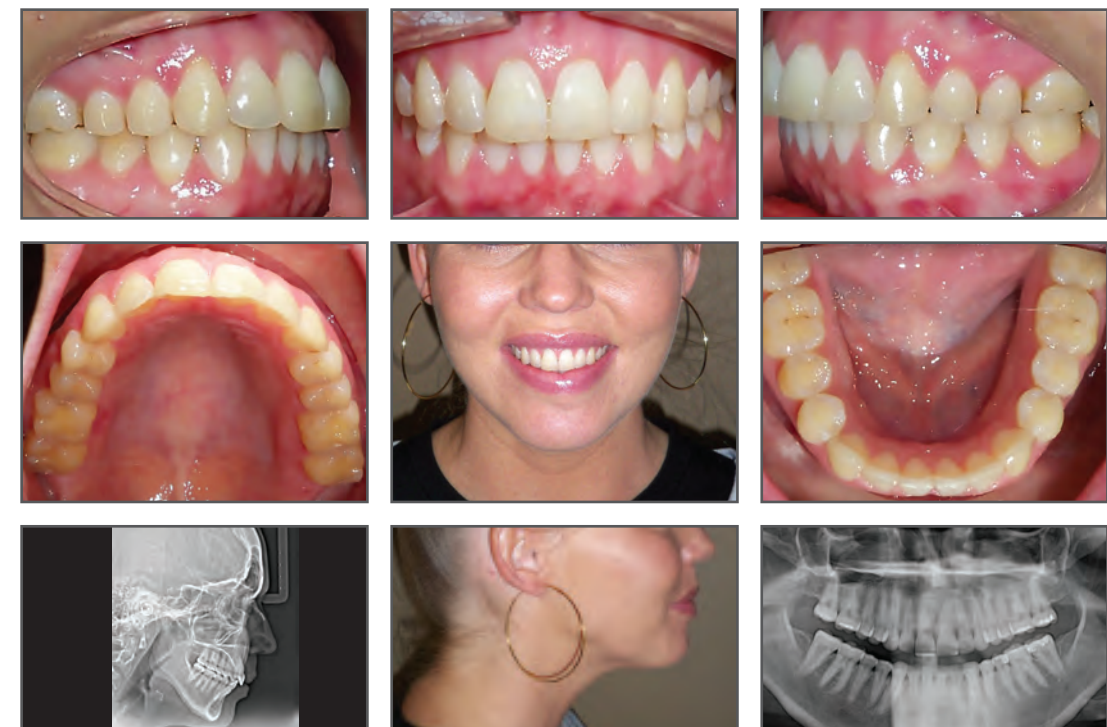OF ALIGNERS USED
Upper: 21 + 18 + 24
Lower: 21 + 18 + 24

ADDITIONAL TREATMENT Class II elastics were used during the first 39 stages, with buttons bonded to teeth numbers 6, 11, 19, and 30. In addition, the chipped distal-incisal surfaces of teeth numbers 8 and 9 were restored with composite.

RETENTION
Upper: Last aligner
Lower: Last aligner



BEFORE



AFTER

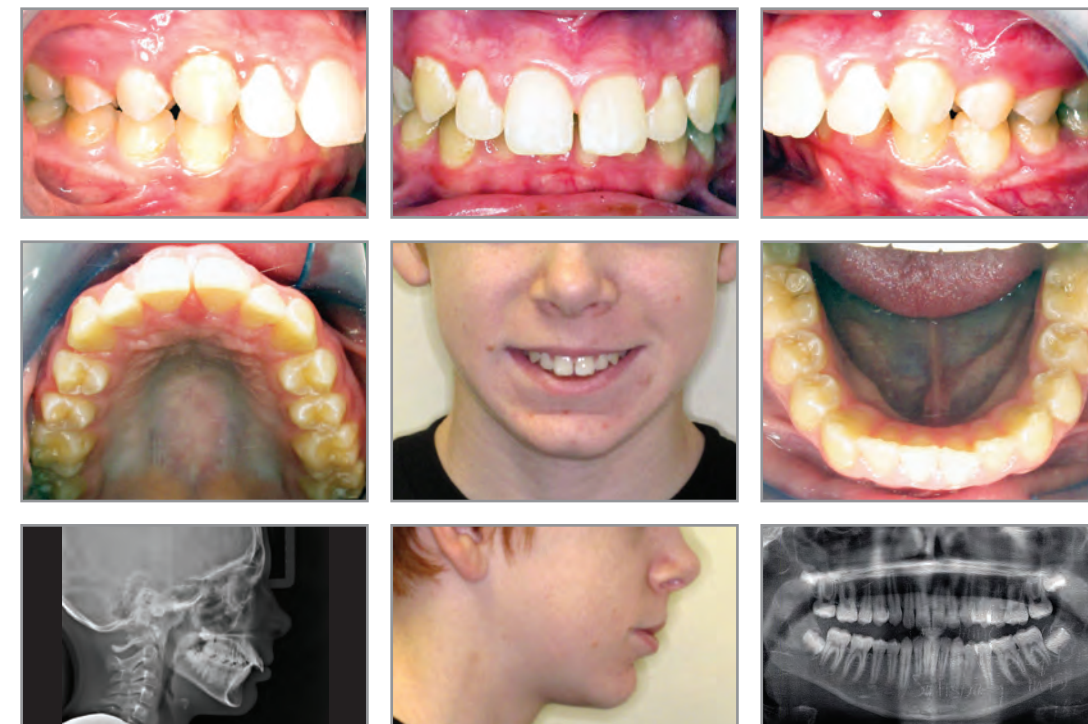

Dr. James Crouse
James M. Crouse, DDS
Salisbury, MD

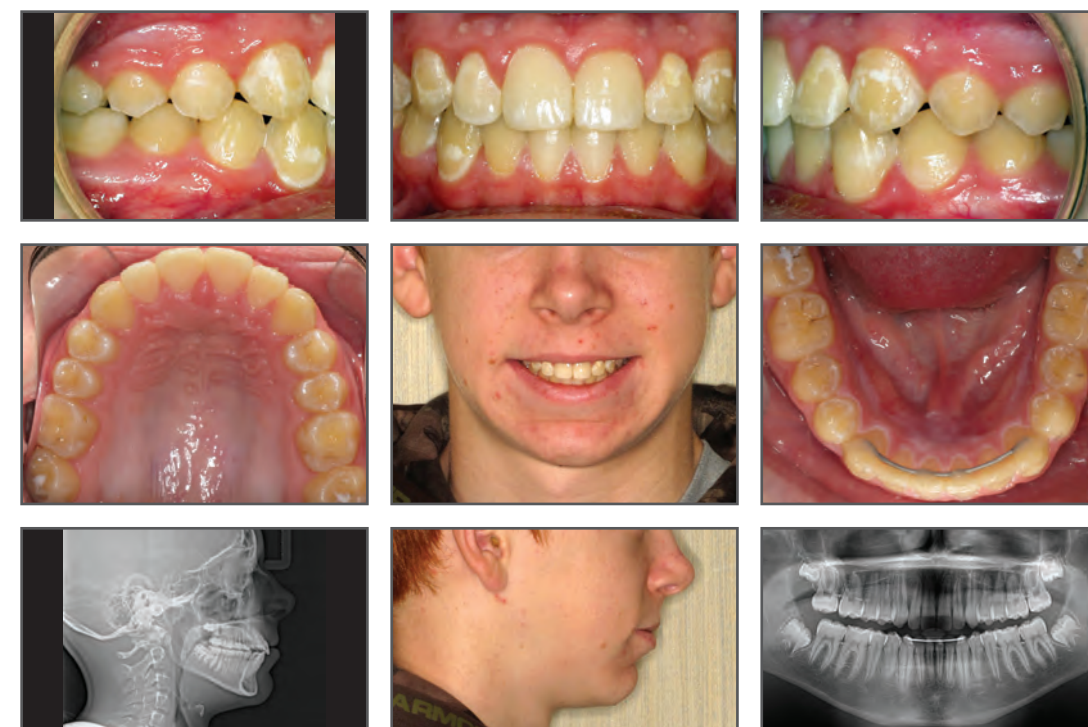
www.drcrousesbraceplace.com

TREATMENT SUMMARY

PATIENT	12-year-old male
CHIEF CONCERN	The patient was concerned about his deep overbite.
DIAGNOSIS	Right: Class II Left: Class II
	Full cusp Class II. 2 mm mandibular crowding and 1 mm maxillary spacing. Deep curve of Spee. 6 mm overbite and 10 mm overjet. Excessive lip curl.
LENGTH OF TREATMENT	11 months
# OF ALIGNERS USED	Upper: 40 Lower: 40
ADDITIONAL TREATMENT	Class II elastics were used full-time for 7 months and then nightly for an additional month, with hooks cut into the aligners near the upper canines and lower first molars.
RETENTION	Upper: Other clear Lower: Bonded lingual



BEFORE



AFTER



Dr. Chunni Duan
Duan Orthodontics
Seattle, WA

www.duanorthodontics.com

TREATMENT SUMMARY

PATIENT 12-year-old male

CHIEF CONCERN The patient had a narrow smile and very crowded teeth which were hard to keep clean.

DIAGNOSIS Right: Class II
Left: Class I

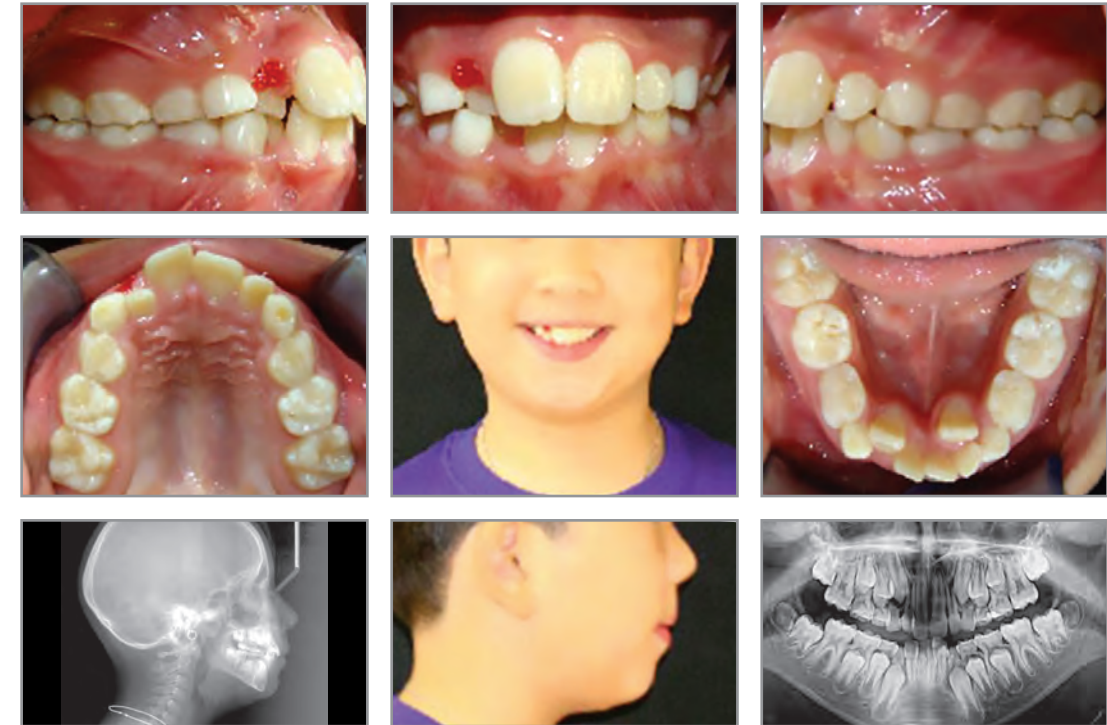Skeletal Class II, with mandibular retrognathism. Division 1 malocclusion. Narrow arches and steep mandibular plane angle. Mild Bolton discrepancy due to narrow #7 and 10. Moderate upper and severe lower crowding. Obstructed airway.

LENGTH OF TREATMENT 18 months Phase I treatment + 17 months Phase II Invisalign treatment

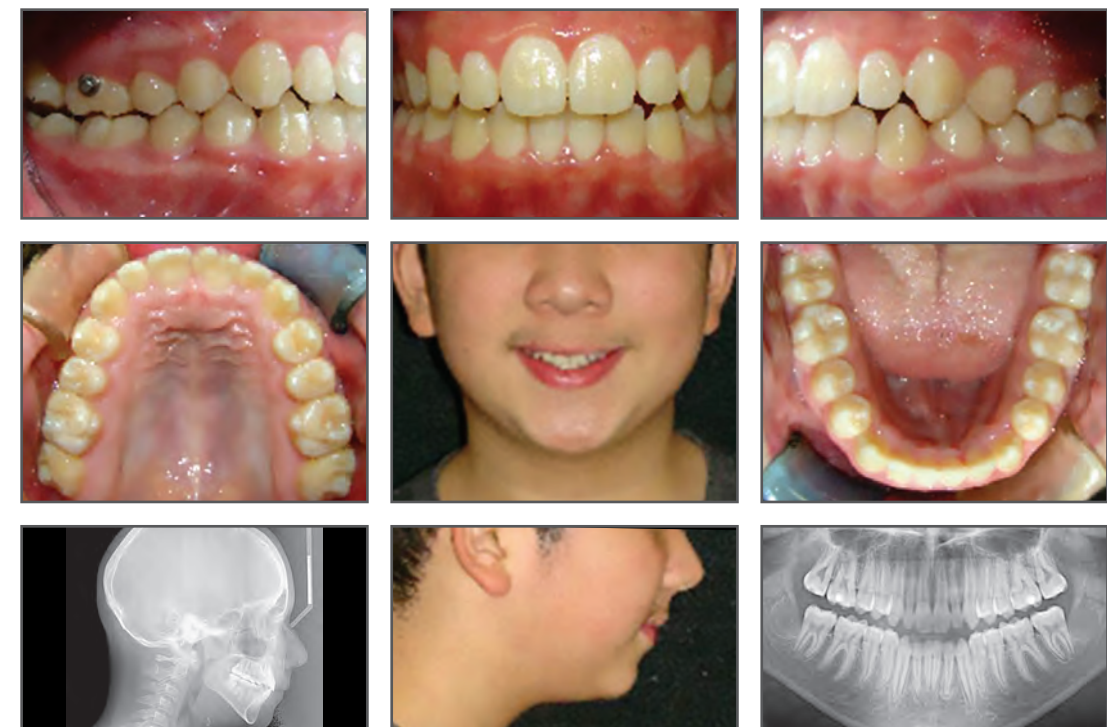OF ALIGNERS USED Upper: 35
Lower: 35

ADDITIONAL TREATMENT Phase 1 treatment consisting of upper and lower expanders to obtain adequate arch widths, and space preservation with upper bite plate and lower space maintainer. To improve the interdigitation, Class III elastics were used for 1.5 months on the right side from a button bonded on the first molar to a hook near the lower canine.

RETENTION Upper: Last aligner
Lower: Last aligner



BEFORE



AFTER



Dr. Tarek El-Bialy
Sphinx Orthodontics
Edmonton, AB, Canada

www.sphinxorthodontics.com

TREATMENT SUMMARY

PATIENT 15-year-old male

CHIEF CONCERN The patient was concerned about his overjet, deep overbite, and spaces between the upper incisors.

DIAGNOSIS
Right: Class II
Left: Class II

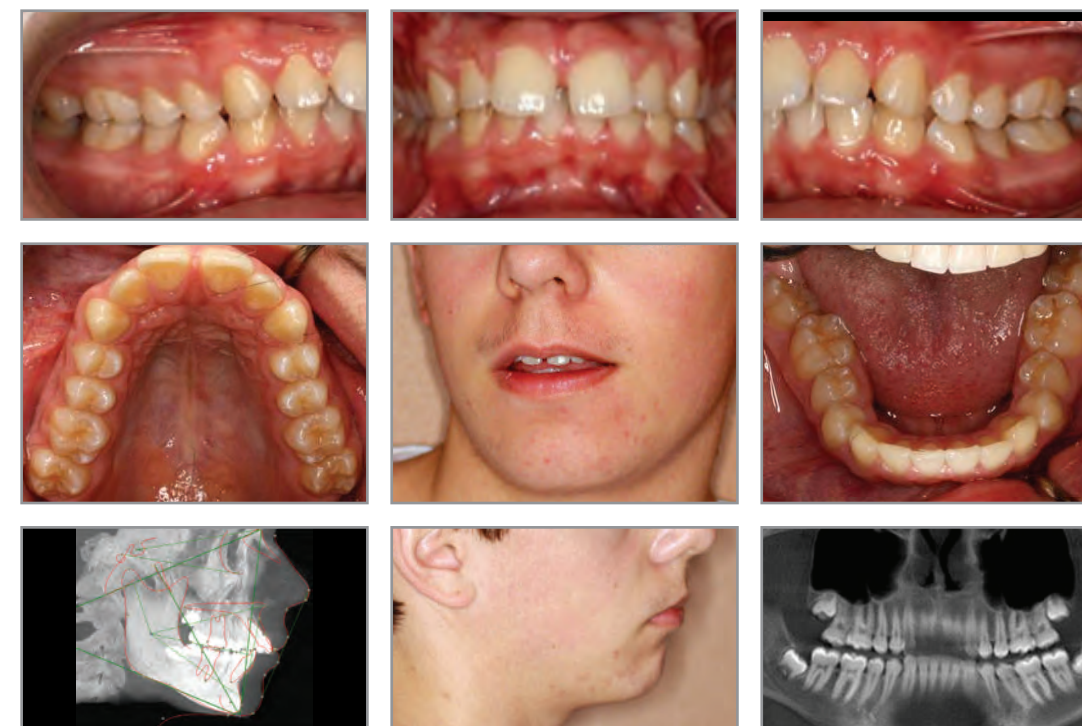Increased overjet, deep overbite and convex profile. Spaces present between the upper incisors.

LENGTH OF TREATMENT 14 months

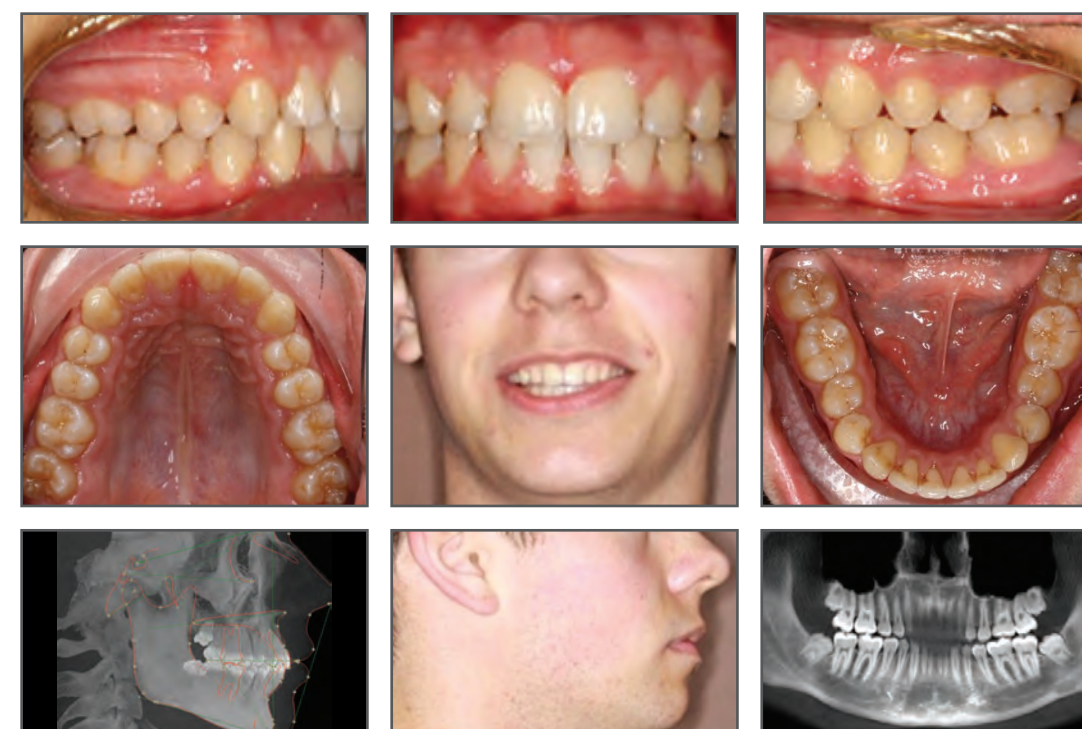
OF ALIGNERS USED
Upper: 52
Lower: 52

ADDITIONAL TREATMENT Class II elastics were used throughout the entire treatment, with buttons bonded to the lower first molars and hooks cut into aligners near the upper canines.

RETENTION
Upper: Vivera®
Lower: Vivera®



BEFORE



AFTER



Dr. Robert Elliott
Lo Elliott Orthodontics, Inc.
Prince George, BC, Canada

www.perfectsmile.ca

TREATMENT SUMMARY

PATIENT 46-year-old male

CHIEF CONCERN The patient was concerned about his crowding and smile aesthetics, but did not want to have fixed braces.

DIAGNOSIS
Right: Class II
Left: Class II

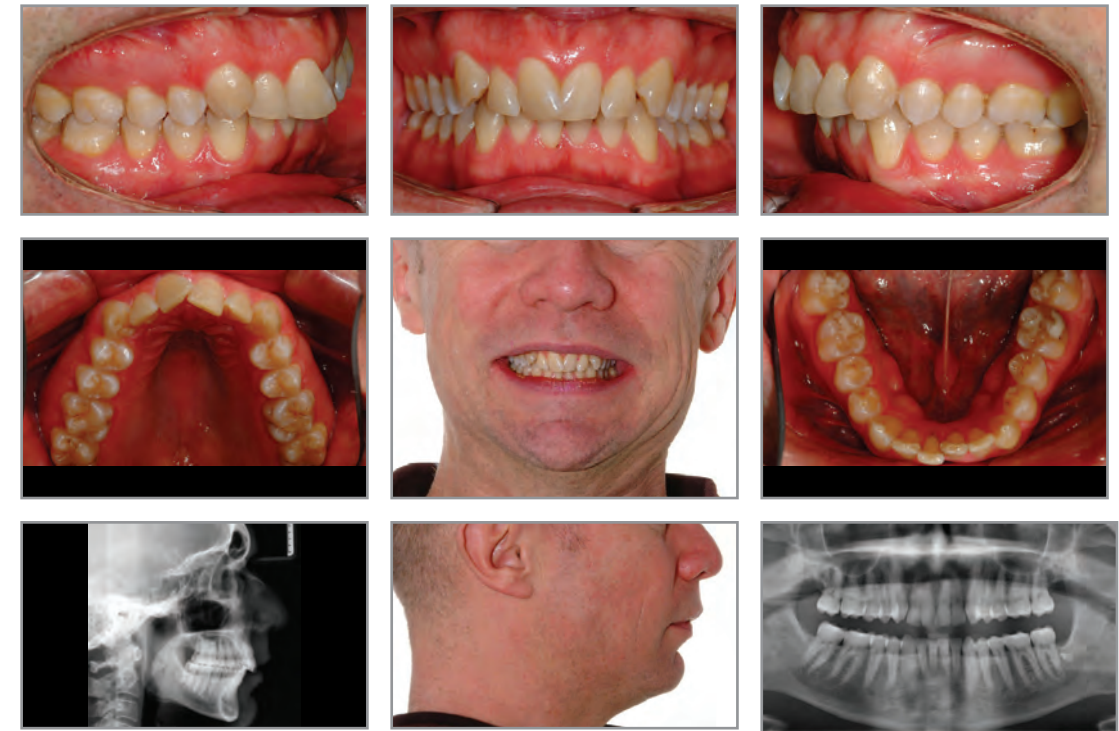Moderate upper and lower crowding, with worn incisal edges. 3rd molars not present (retained root fragment in the lower left). 50% overbite and 7 mm overjet.

LENGTH OF TREATMENT 21 months

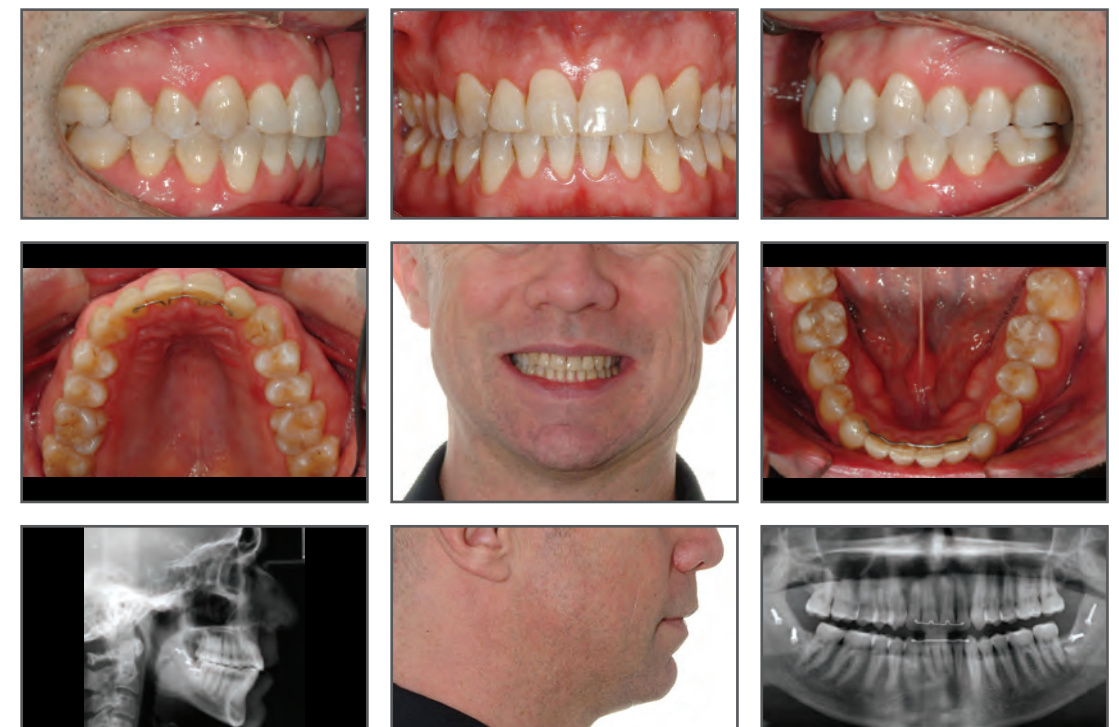OF ALIGNERS USED
Upper: 22
Lower: 18

ADDITIONAL TREATMENT Mandibular advancement, with vertical elastics used to allow for guided healing during the immediate post-surgical treatment phase. Elastics were used for 3 months, with hooks cut into the aligners near the maxillary and mandibular canines, bicuspids, and first molars. IPR of maxillary central incisors was done to eliminate gingival embrasure as well as aesthetic re-contouring of maxillary incisors. No restorative material was used on the maxillary incisors.

RETENTION
Upper: Other clear over bonded lingual
Lower: Bonded lingual



BEFORE



AFTER



Dr. Donna Galante
Cater Galante Orthodontics
Rocklin, CA

www.luvmysmile.com

TREATMENT SUMMARY

PATIENT 17-year-old female

CHIEF CONCERN The patient was concerned about her overbite and crowded front teeth.

DIAGNOSIS Right: Class II
Left: Class II

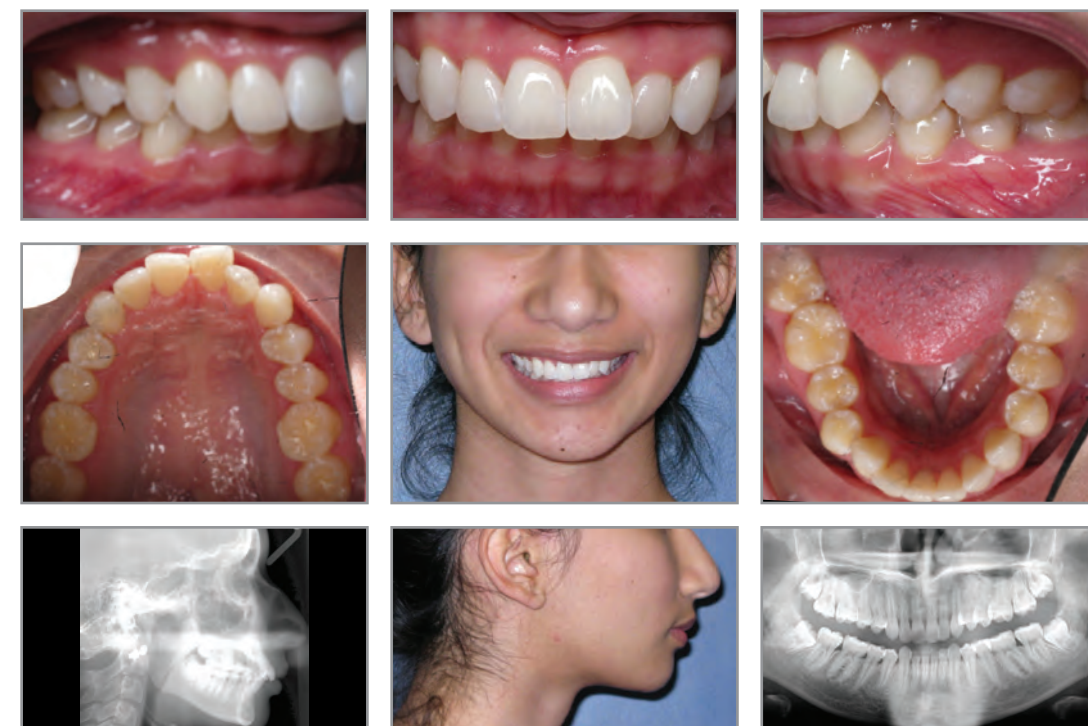Excessive overjet, with moderate upper and mild lower crowding.

LENGTH OF TREATMENT 16 months

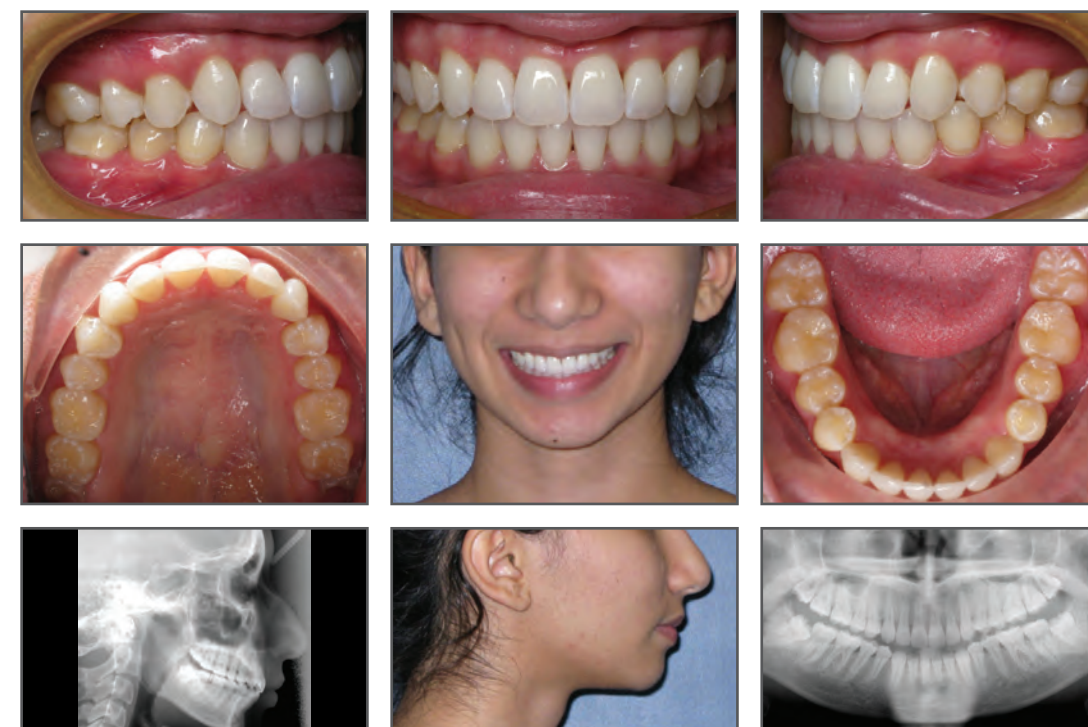OF ALIGNERS USED Upper: 52
Lower: 52

ADDITIONAL TREATMENT Class II elastics were used for 9 months, with hooks cut into the aligners near the upper canines and buttons bonded to the lower first molars.

RETENTION Upper: Other clear
Lower: Other clear



BEFORE



AFTER



Dr. Jose Luis Garcia
Braces By Garcia
Temecula, CA

www.bracesbygarcia.com



TREATMENT SUMMARY

PATIENT 18-year-old male

CHIEF CONCERN "I would like to correct my open bite and spaces."

DIAGNOSIS
Right: Class II
Left: Class II

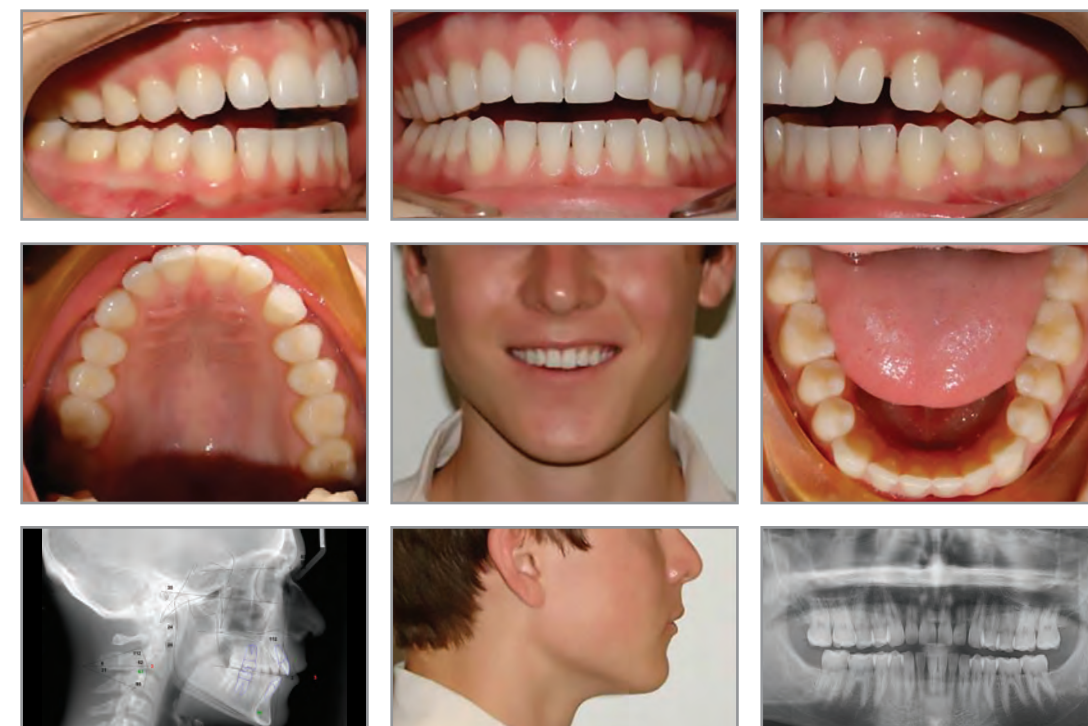
5 mm open bite and 7 mm overjet. Mild maxillary and mandibular spacing. Mild anterior tongue thrust.

LENGTH OF TREATMENT 18 months

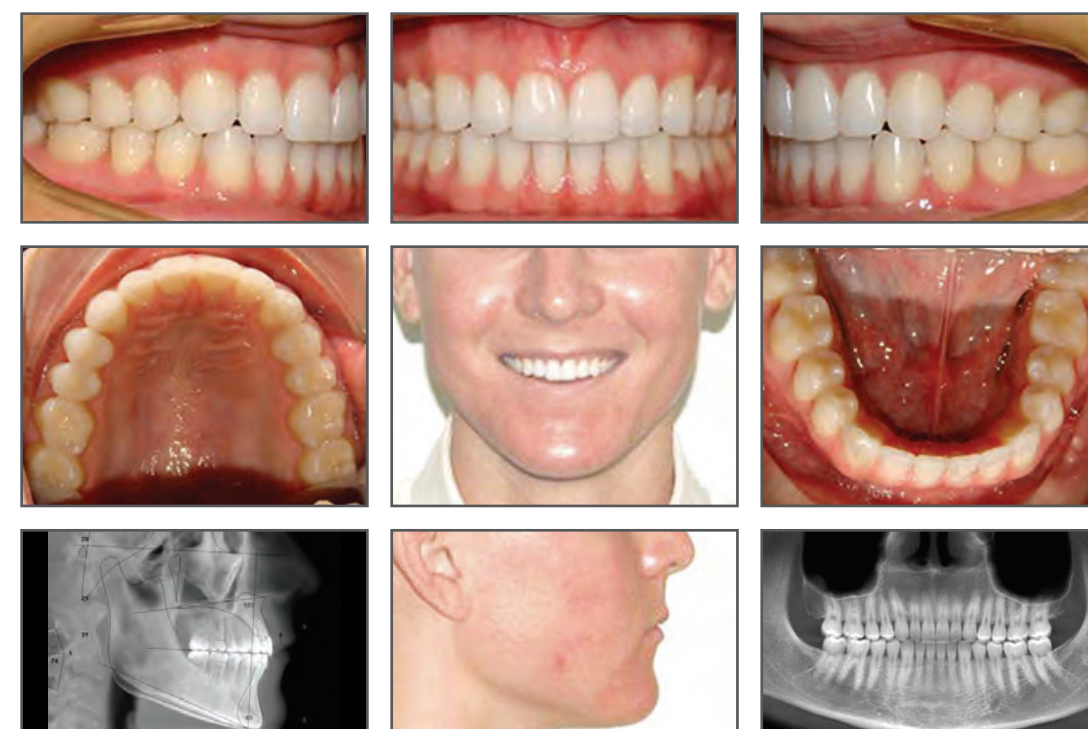
OF ALIGNERS USED
Upper: 16 + 10
Lower: 14 + 6

ADDITIONAL TREATMENT Class II elastics were used on the left side for 2 months full-time and then only at night for 1 month, with buttons bonded to the upper cuspid and lower first molar.

RETENTION
Upper: Other clear
Lower: Other clear



BEFORE



AFTER



Dr. Bella Shen Garnett
Bella Smile
San Francisco, CA

www.bellasmile.com

TREATMENT SUMMARY

PATIENT 31-year-old female

CHIEF CONCERN The patient was concerned about her open bite.

DIAGNOSIS
Right: Class II
Left: Class II

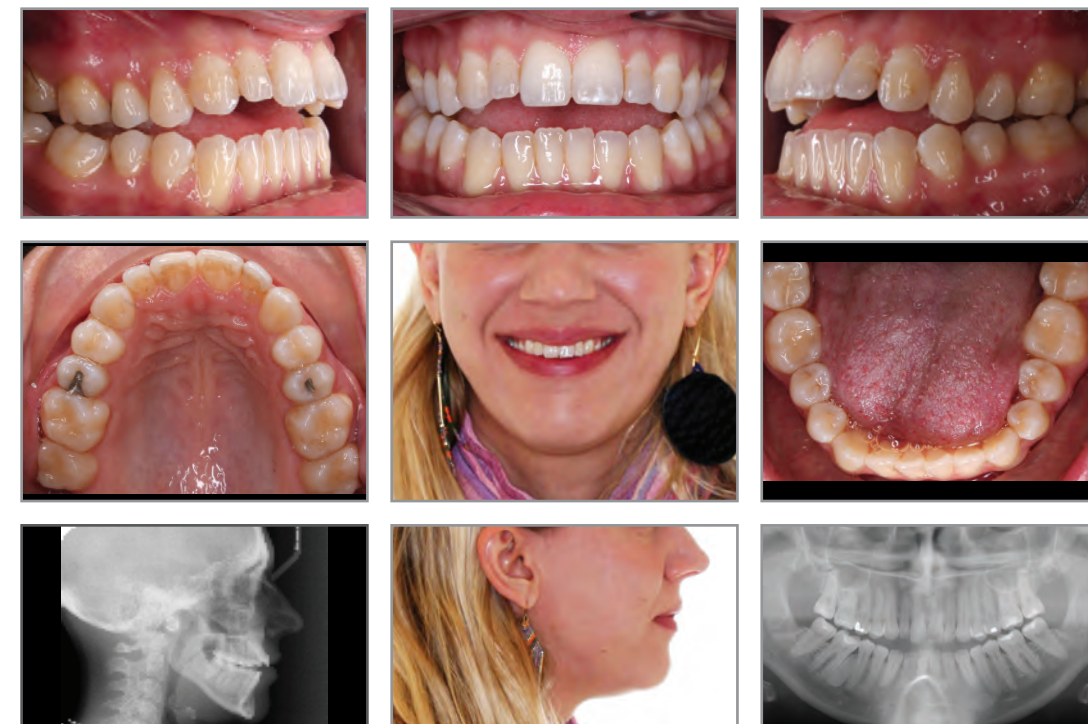High mandibular plane angle. This case was submitted for Angle Society membership (SN-Go-Gn>40°). 4 mm anterior open bite with severe overjet (6 mm). Constricted maxilla and mild lower crowding. Proclined upper incisors and anterior tongue thrust.

LENGTH OF TREATMENT 48 months

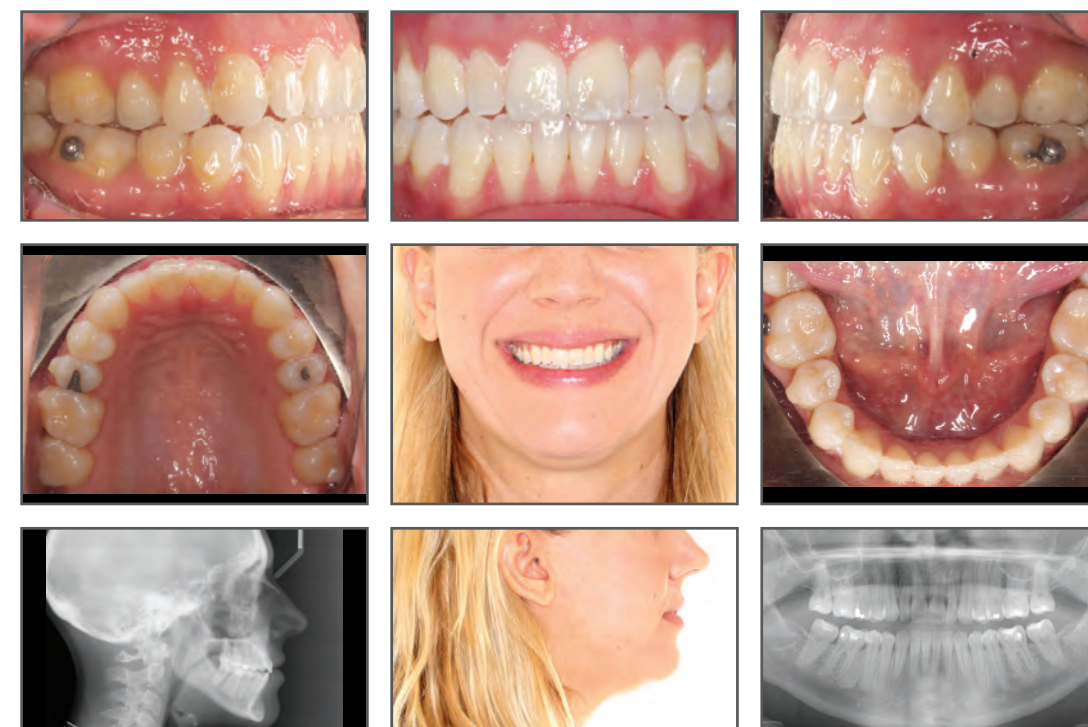
OF ALIGNERS USED
Upper: 17 + 14 + 26 + 19
Lower: 17 + 14 + 26 + 19

ADDITIONAL TREATMENT TADs were placed between the U6's and U7's, with sling elastics used for 2 years to intrude molars. Class II elastics were used throughout treatment, with hooks cut into the aligners near the U3's and buttons bonded to the L6's. AcceleDent® was used during the last refinement (3 months).

RETENTION
Upper: Essix® over bonded lingual
Lower: Essix® over bonded lingual



BEFORE



AFTER



Dr. Bella Shen Garnett
Bella Smile
San Francisco, CA

www.bellasmile.com

TREATMENT SUMMARY

PATIENT 25-year-old male

CHIEF CONCERN The patient was concerned about his crowded teeth.

DIAGNOSIS
Right: Class II
Left: Class II

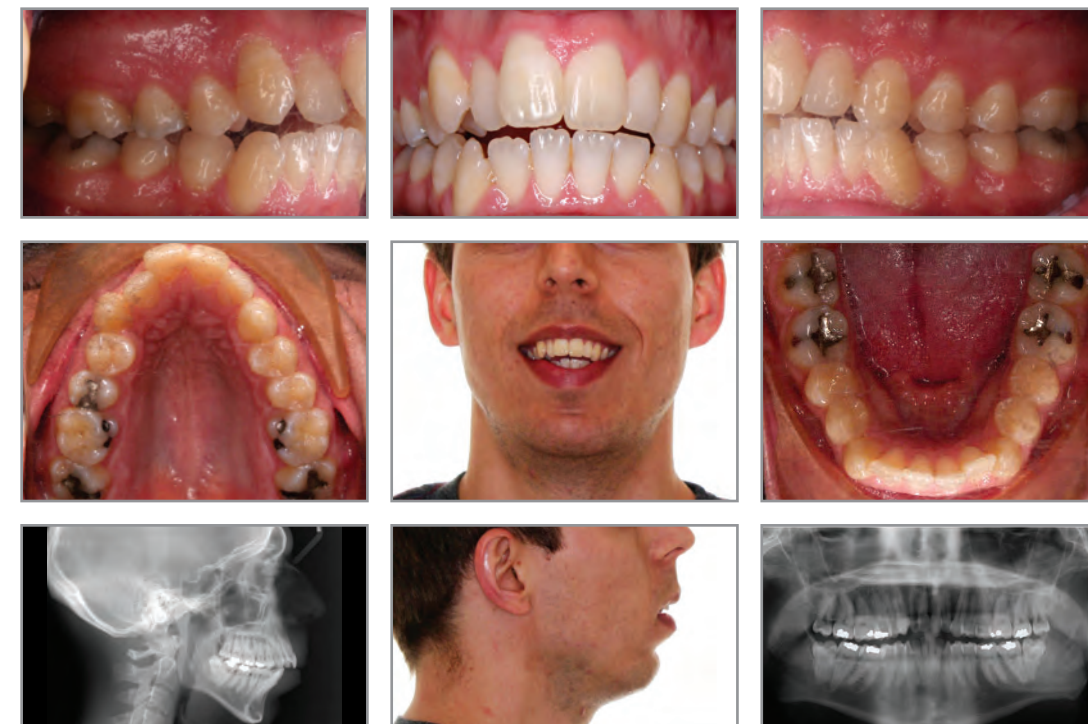Mild to moderate crowding. Narrow upper and lower arches. All 3rd molars present.

LENGTH OF TREATMENT 17 months

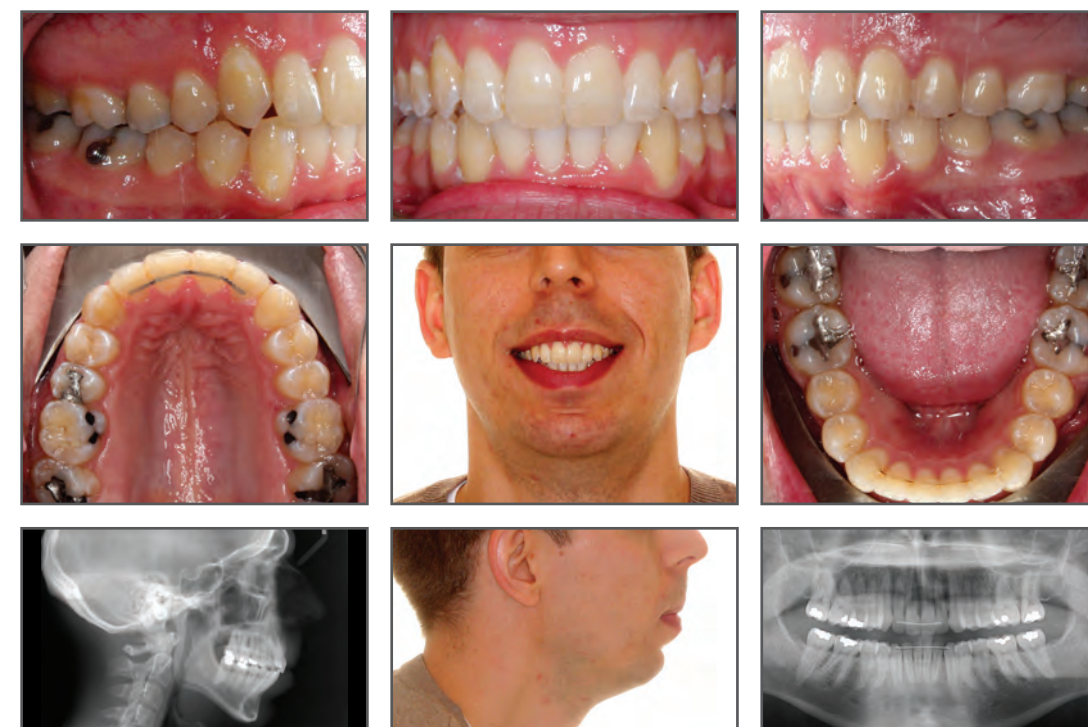OF ALIGNERS USED
Upper: 25 + 12
Lower: 21 + 13

ADDITIONAL TREATMENT Class II elastics were used throughout the entire treatment, with hooks cut into the aligners near the upper cuspids and buttons bonded to the lower first molars.

RETENTION
Upper: Essix® over bonded lingual
Lower: Essix® over bonded lingual



BEFORE



AFTER



Dr. Barry Glaser
Glaser Orthodontics
Cortlandt Manor, NY

www.glaserorthodontics.com

TREATMENT SUMMARY

PATIENT 15-year-old female

CHIEF CONCERN The patient doesn't like her crooked teeth.

DIAGNOSIS
Right: Class II
Left: Class II

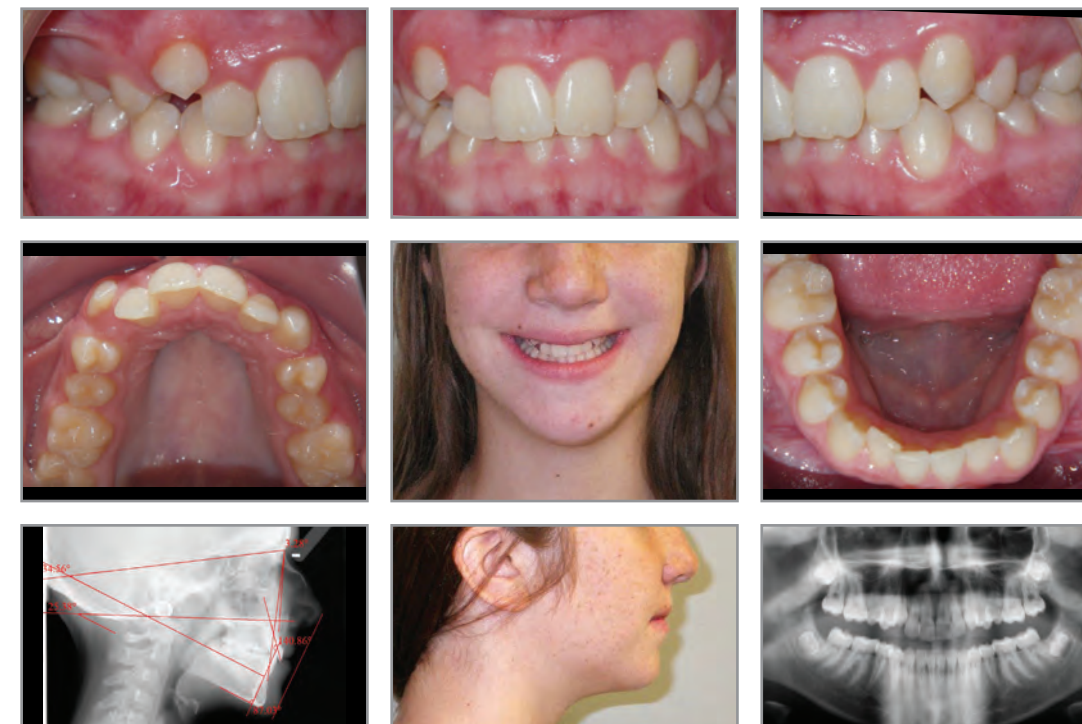
Division 1 malocclusion. Severe deep overbite with moderate upper and lower crowding. Upper canines are high and buccally displaced. Straight facial profile.

LENGTH OF TREATMENT 20 months

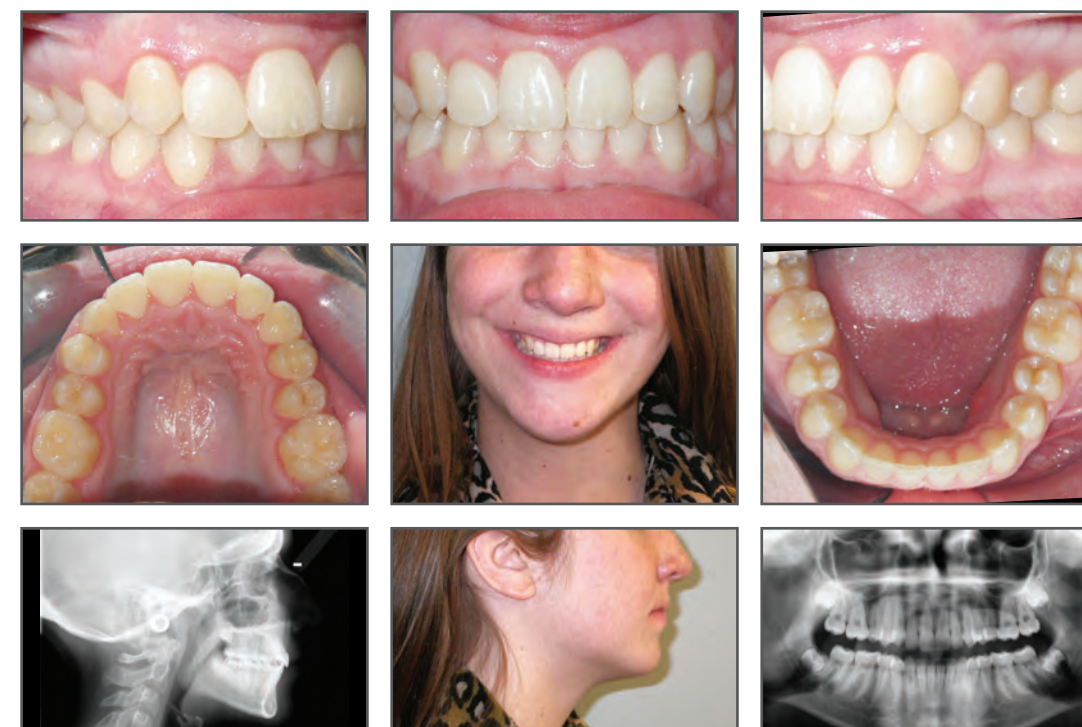
OF ALIGNERS USED
Upper: 18 + 17
Lower: 18 + 17

ADDITIONAL TREATMENT Triangular elastics were used for 9 months to extrude the canines, with buttons on the upper canines and hooks cut into the aligners near the lower canines and first bicuspsids.

RETENTION
Upper: Other clear
Lower: Other clear



BEFORE



AFTER

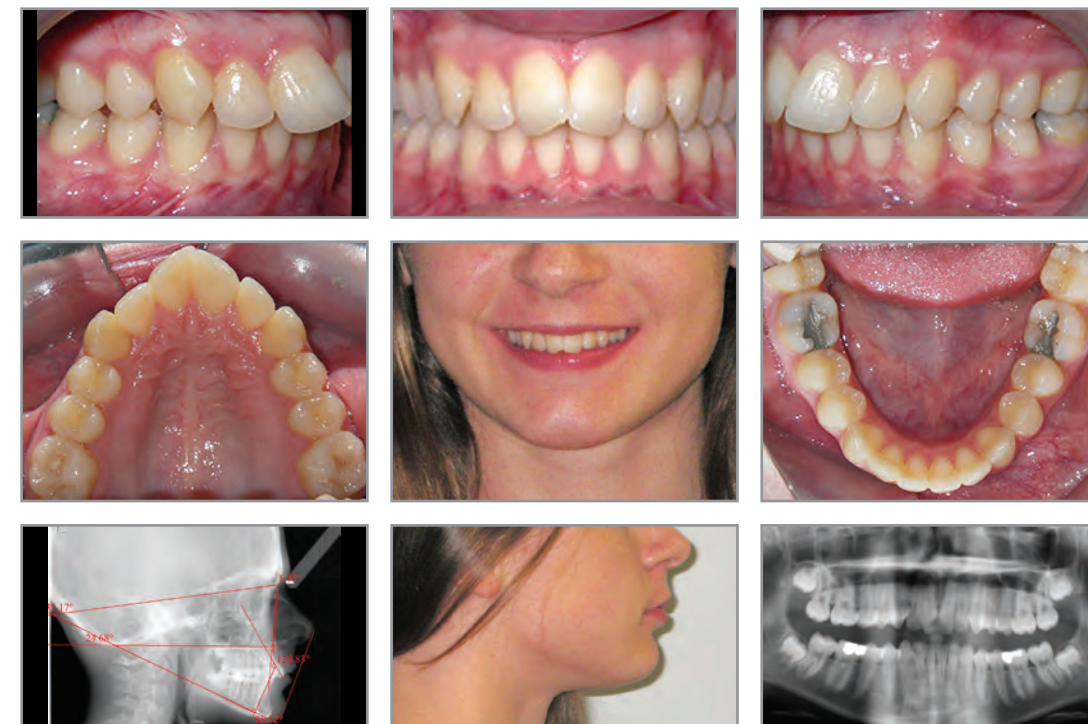

Dr. Barry Glaser
Glaser Orthodontics
Cortlandt Manor, NY

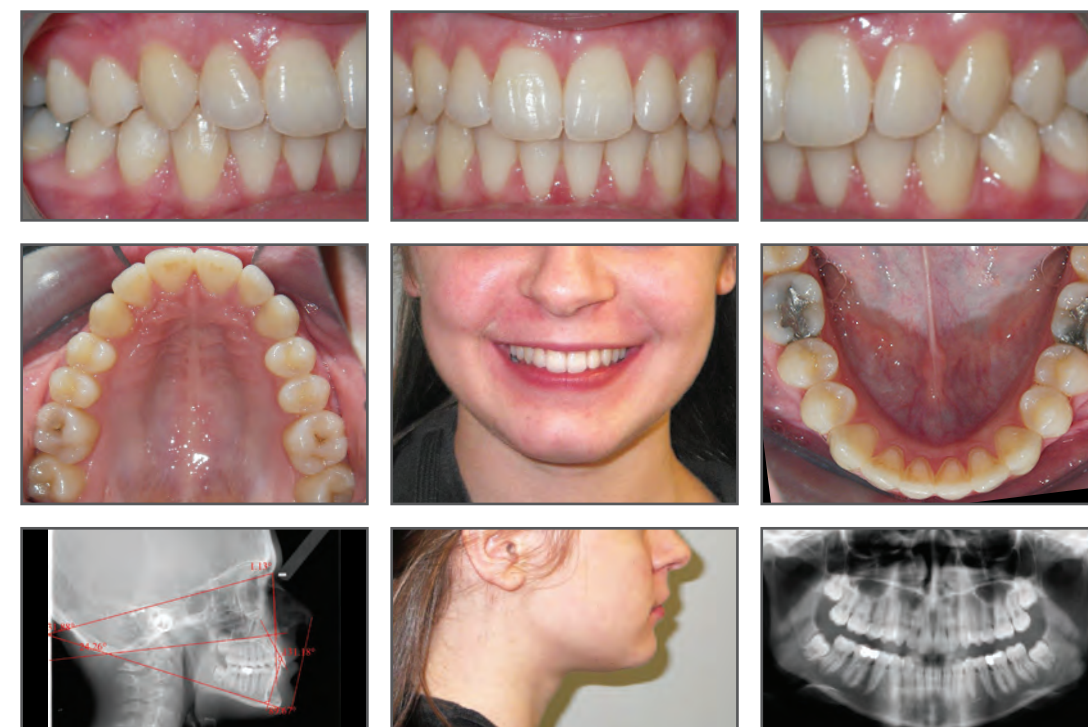
www.glaserorthodontics.com

TREATMENT SUMMARY

PATIENT	15-year-old female
CHIEF CONCERN	The patient wanted to correct her "overbite."
DIAGNOSIS	Right: Class II Left: Class II
	Division 1 malocclusion. Moderate upper and mild lower crowding. 7 mm overjet. Severely rotated upper central incisors, with a V-shaped upper arch.
LENGTH OF TREATMENT	22 months
# OF ALIGNERS USED	Upper: 25 + 20 Lower: 25 + 20
ADDITIONAL TREATMENT	1/4" 1.8 oz. Class II elastics were used on both sides for 22 months, with elastic hooks cut into the aligners near the upper canines and lower first molars.
RETENTION	Upper: Other clear Lower: Other clear



BEFORE



AFTER



Dr. Ira Goldberg
Goldberg Orthodontics
Roslyn, NY

www.goldbergortho.com

TREATMENT SUMMARY

PATIENT 32-year-old female

CHIEF CONCERN "Crooked teeth and overbite" (overjet).

DIAGNOSIS
Right: Class II
Left: Class II

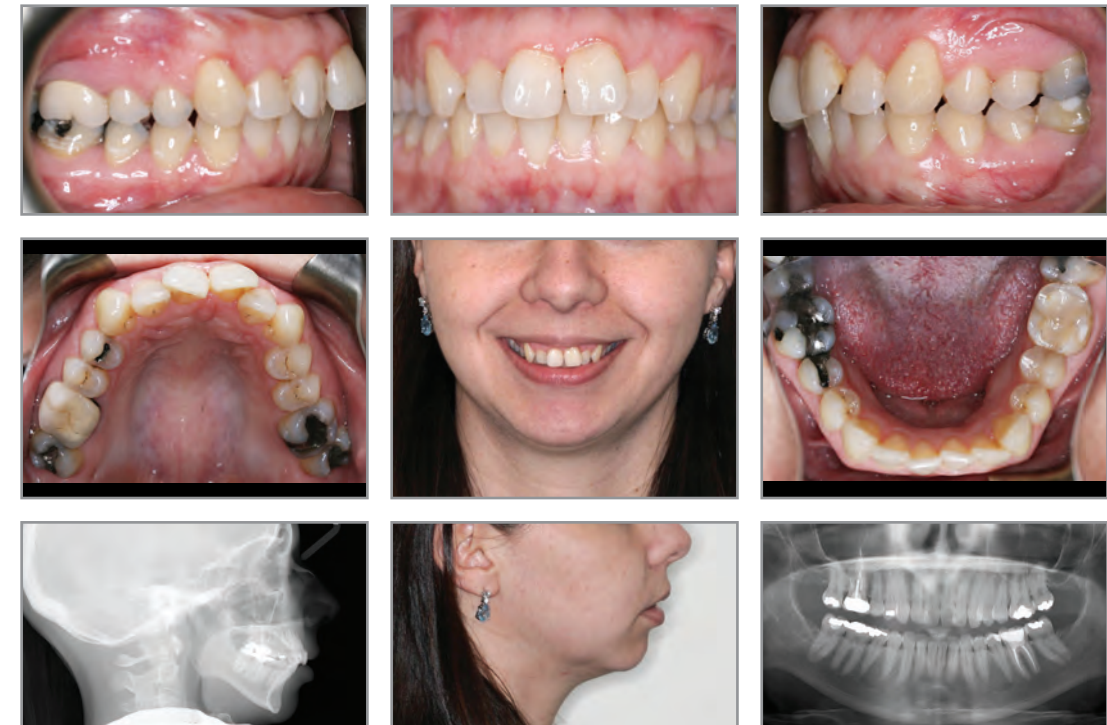
Division 1 malocclusion. Hyperdivergent skeletal pattern with retrognathic mandible. Proclined mandibular incisors. Upright maxillary incisors.

LENGTH OF TREATMENT 36 months

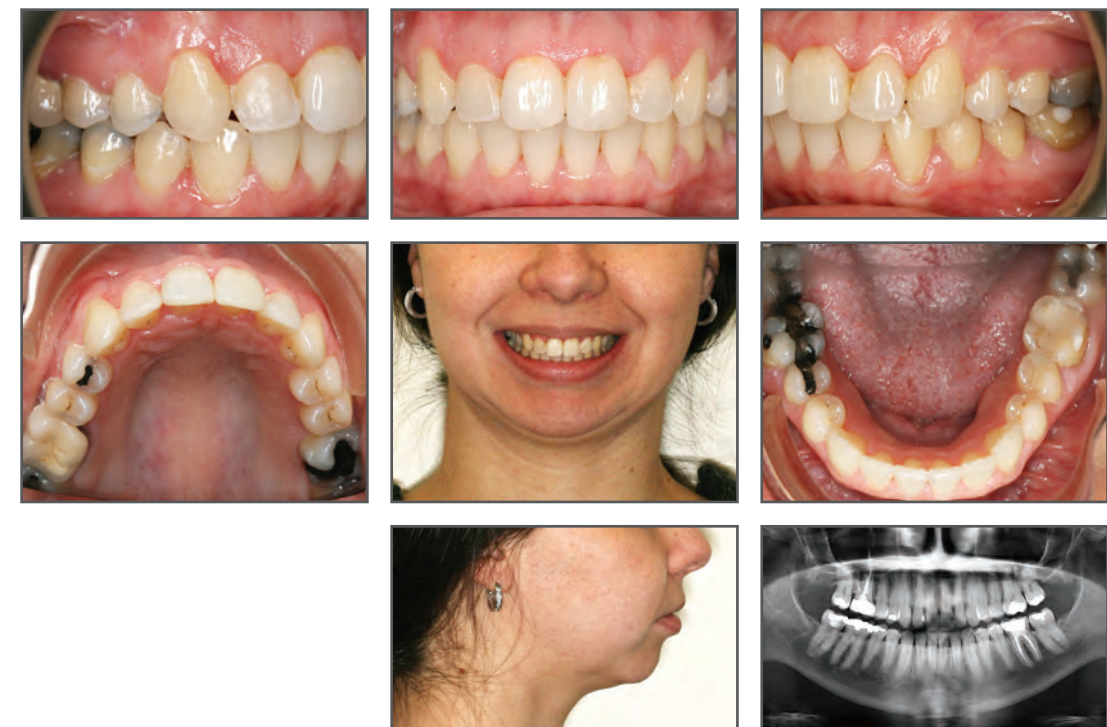OF ALIGNERS USED
Upper: 26 + 24 + 11 + 22
Lower: 26 + 24 + 11 + 22

ADDITIONAL TREATMENT Class II elastics worn for the duration of treatment after the first refinement, with hooks cut into the aligners near the upper canines, and buttons bonded to the lower first molars.

RETENTION
Upper: Last aligner during the day, Hawley at night
Lower: Last aligner during the day, Hawley at night



BEFORE



AFTER



Dr. Jasmine Gorton
Gorton & Schmohl Orthodontics
Larkspur, CA

www.asmileisforever.net

TREATMENT SUMMARY

PATIENT 13-year-old male

CHIEF CONCERN "I have an overbite" (excess overjet).

DIAGNOSIS
Right: Class II
Left: Class II

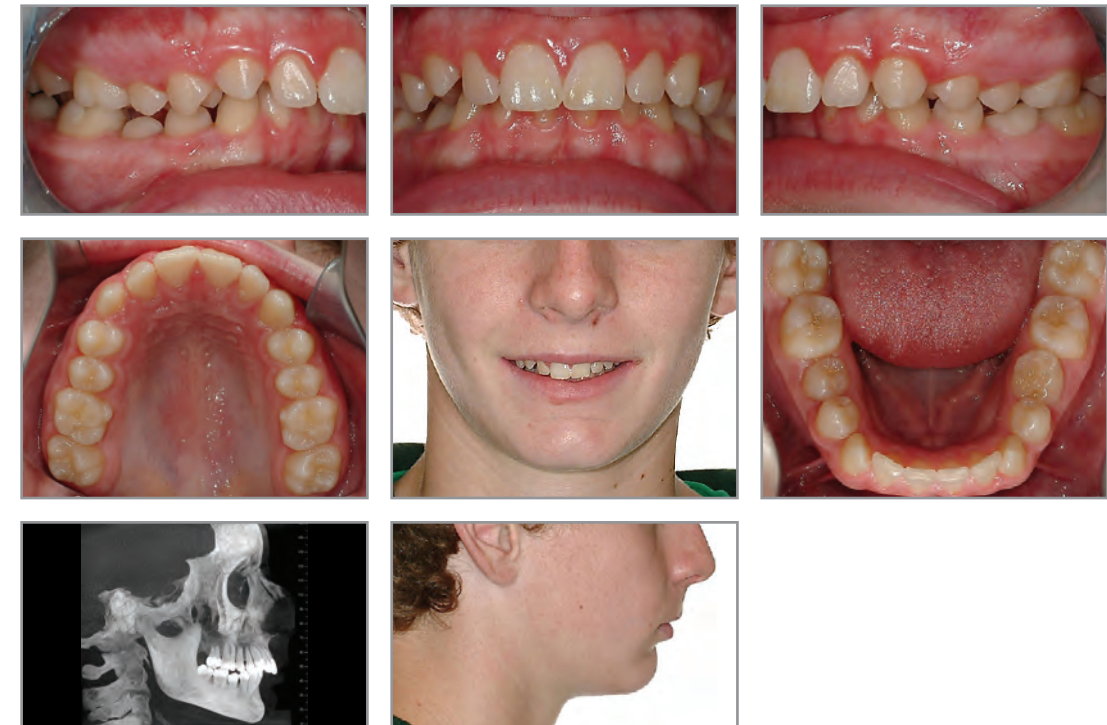
Division 2 malocclusion. 9 mm overjet and 90% deep impinging bite. Mild upper spacing, moderate lower crowding. Incisal wear of the lower anterior teeth. Submerged lower left primary second molar.

LENGTH OF TREATMENT 13 months Phase I treatment + 15 months Phase II Invisalign treatment

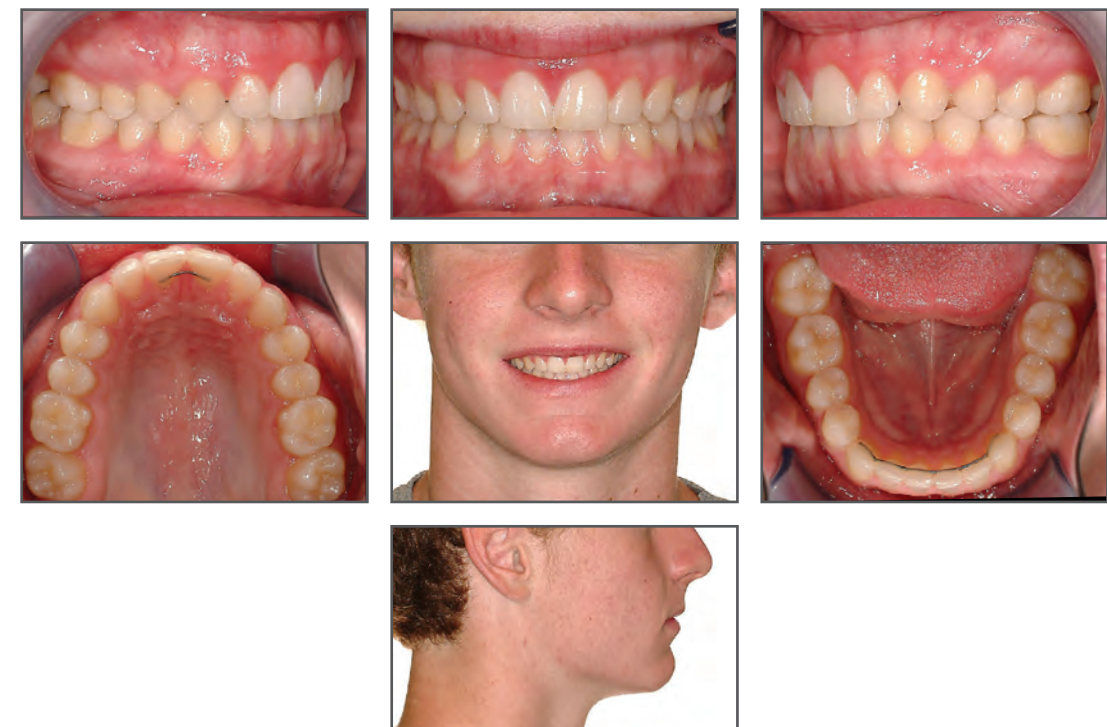OF ALIGNERS USED
Upper: 27
Lower: 27

ADDITIONAL TREATMENT Herbst appliance used for 13 months prior to Invisalign treatment. Class II elastics were used full-time for 3 months, then only at night for 10 months, with clear buttons on the upper canines and metal hooks on the lower first molars.

RETENTION
Upper: Other clear over bonded lingual
Lower: Other clear over bonded lingual



BEFORE



AFTER



Dr. Sean Holliday
Holliday Orthodontics
Pearl City, HI

www.dochollidaybraces.com

TREATMENT SUMMARY

PATIENT 12-year-old male

CHIEF CONCERN Crooked teeth and a metal allergy that might prevent him from getting fixed braces.

DIAGNOSIS
Right: Class II
Left: Class II

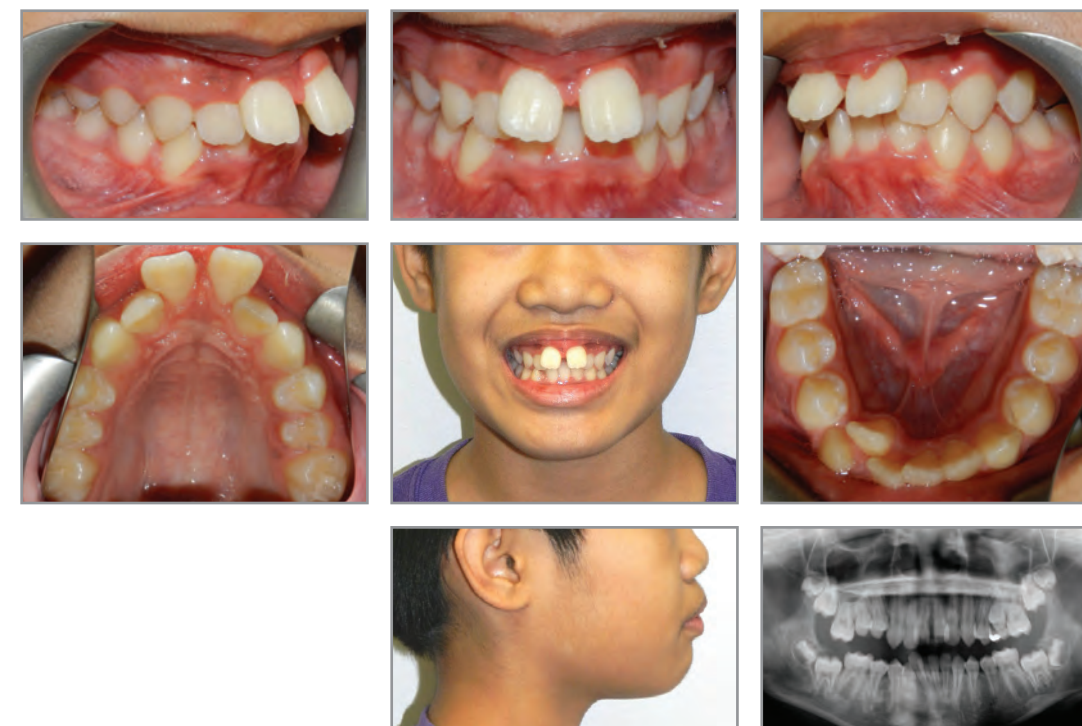Division 1 malocclusion. Upper diastema and severe lower crowding. Low maxillary frenum attachment. 11 mm overjet, 90% overbite. Lower incisors impinging on palate. Severe curve of Spee. Protruded and proclined upper incisors. Lip strain on closure. Allergy to nickel.

LENGTH OF TREATMENT 22 months

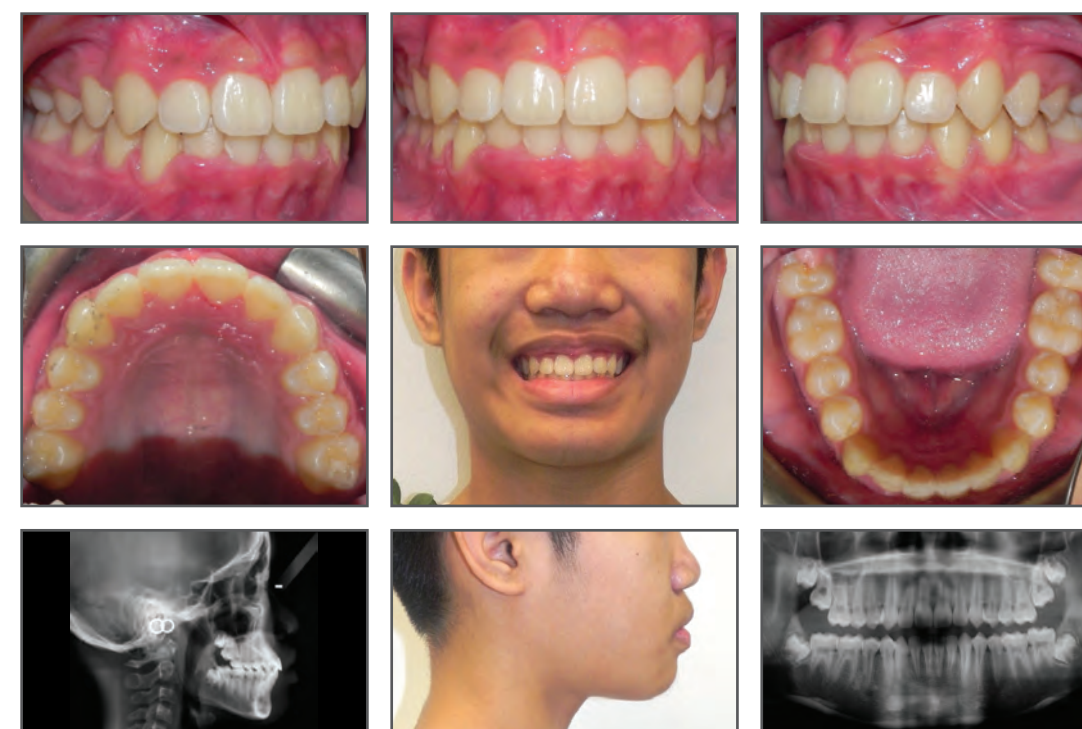OF ALIGNERS USED
Upper: 26 + 18
Lower: 26 + 18

ADDITIONAL TREATMENT Class II elastics were used for 8 months, with hooks cut into the aligners near the upper 4's and lower 6's.

RETENTION
Upper: Invisalign® retainer
Lower: Invisalign® retainer



BEFORE



AFTER



Dr. Sean Holliday
Holliday Orthodontics
Pearl City, HI

www.dochollidaybraces.com

TREATMENT SUMMARY

PATIENT 14-year-old male

CHIEF CONCERN "I want to fix my overbite" (overjet).

DIAGNOSIS
Right: Class II
Left: Class II

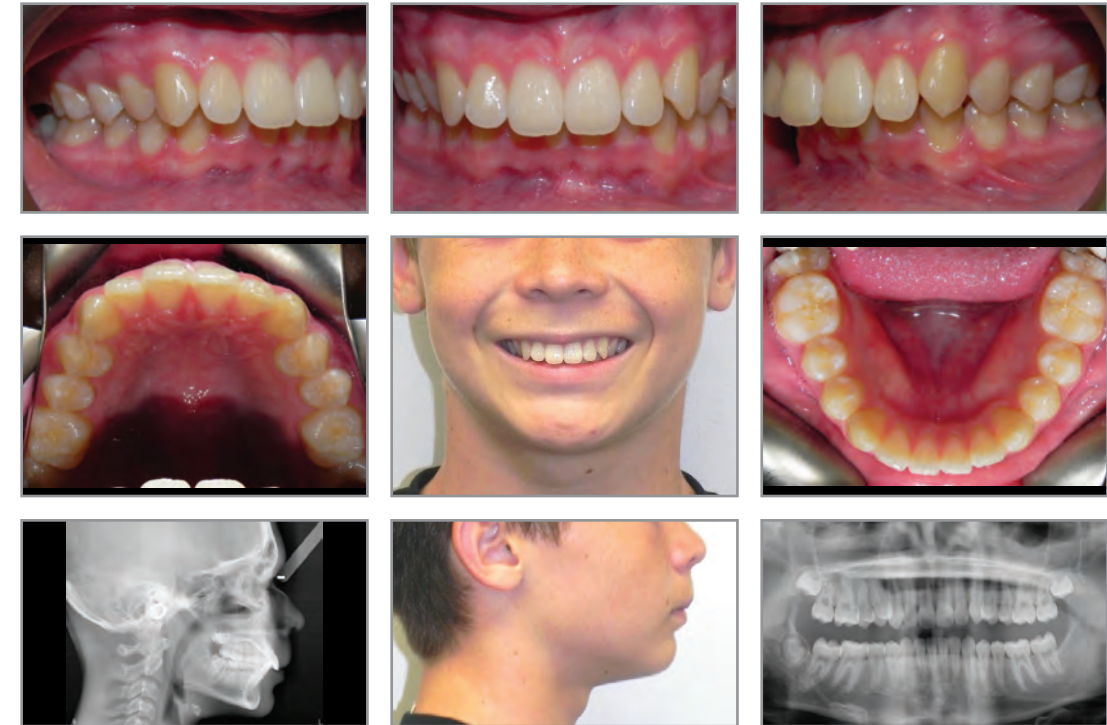
Division 1 malocclusion. 7 mm overjet and 50% overbite. Proclined upper incisors. Midline deviation.

LENGTH OF TREATMENT 15 months

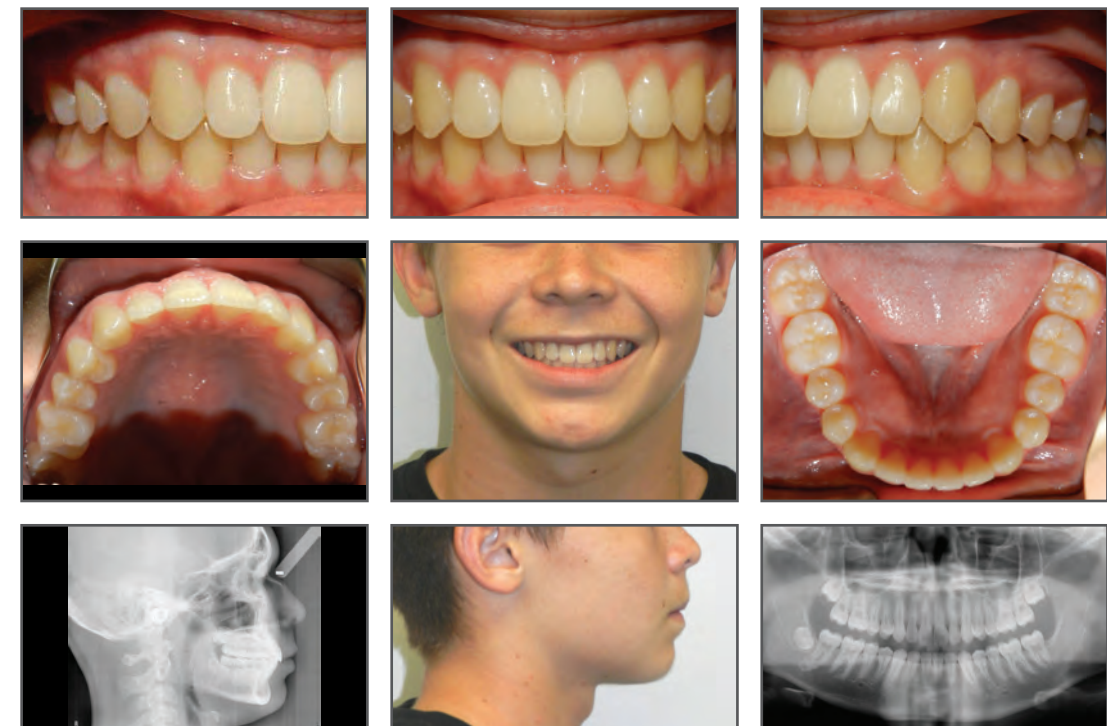
OF ALIGNERS USED
Upper: 17 + 15
Lower: 17 + 15

ADDITIONAL TREATMENT Class II elastics were used for 13 months, with hooks cut into the aligners near the upper 4's and lower 7's.

RETENTION
Upper: Vivera®
Lower: Vivera®



BEFORE



AFTER



Dr. Kraig Kottemann
Kottemann Orthodontics
Maple Grove, MN

www.kottemannortho.com

TREATMENT SUMMARY

PATIENT 33-year-old female

CHIEF CONCERN "I don't like how my front teeth stick out."

DIAGNOSIS
Right: Class II
Left: Class II

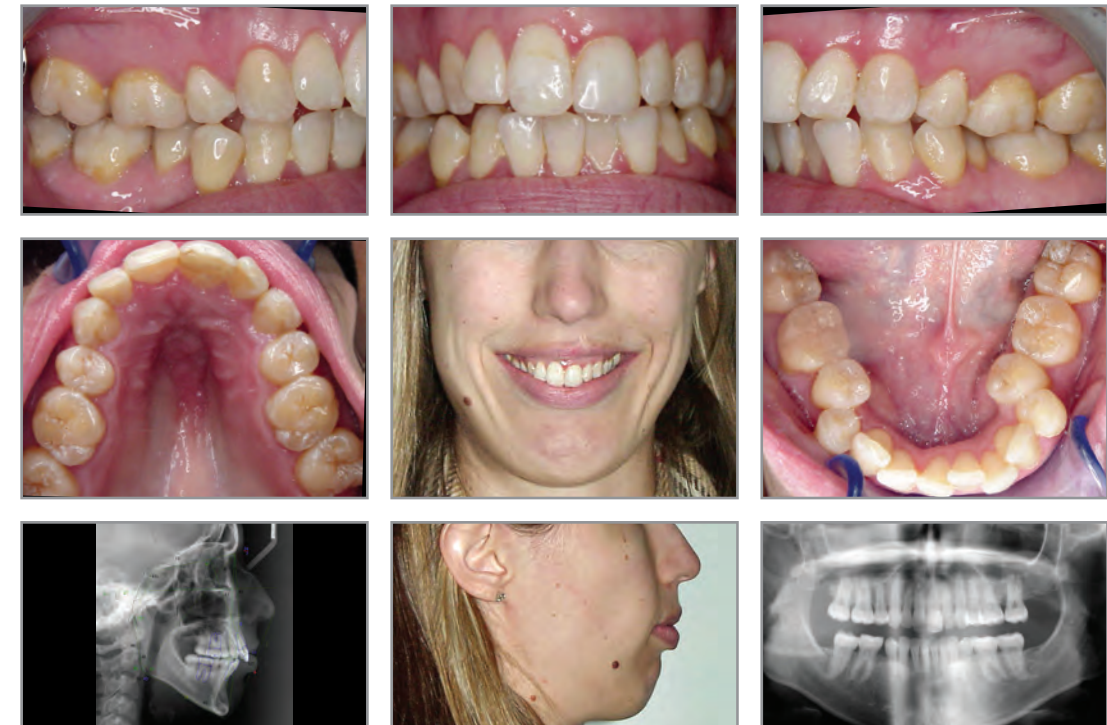
Previous partial orthodontic treatment by her general dentist, with upper 2nd bicuspid extracted. Excessive overjet, minimal overbite, and long lower face height. Moderate upper crowding and severe lower crowding. Proclined lower incisors. History of bruxism.

LENGTH OF TREATMENT 20 months

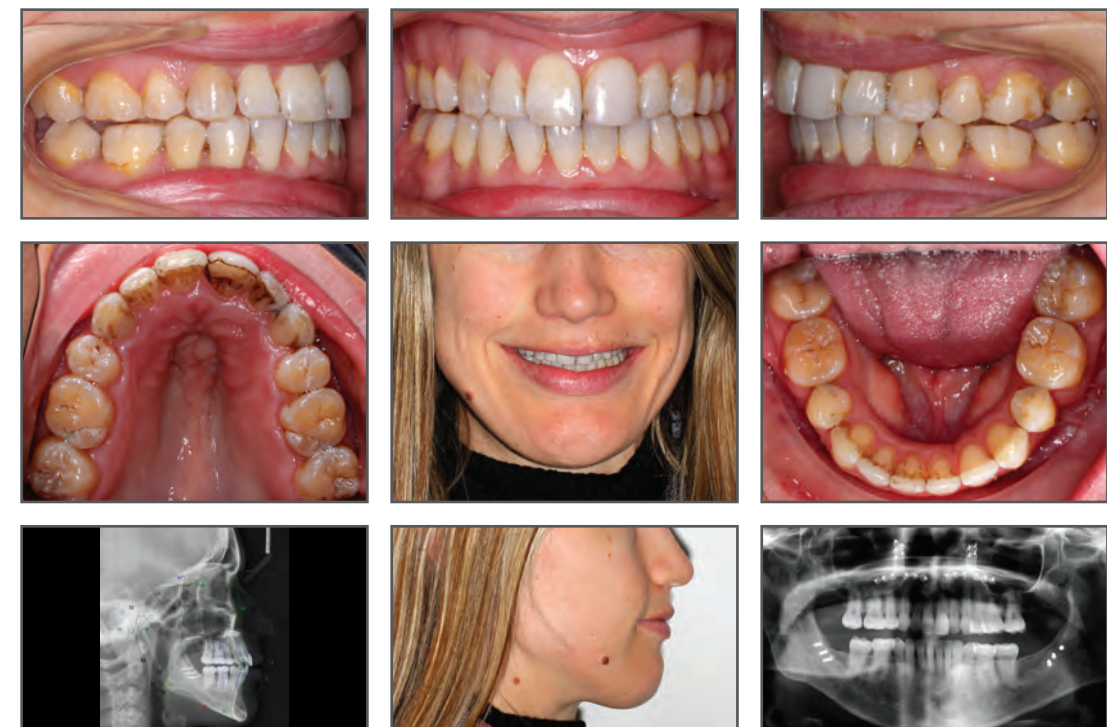OF ALIGNERS USED
Upper: 36
Lower: 36

ADDITIONAL TREATMENT Extracted the lower 2nd bicuspid. Sectional braces were used on the lower 4's and 6's for 3 months during space closure to upright the roots. Maxillary impaction/advancement with asymmetric mandibular advancement. Bonded metal buttons for surgical splint and IMF elastics were also used.

RETENTION
Upper: Vivera®
Lower: Vivera®



BEFORE



AFTER



Dr. Edwin Lee
Berman and Lee Orthodontics
Falls Church, VA

www.bermanandlee.com

TREATMENT SUMMARY

PATIENT 15-year-old female

CHIEF CONCERN "I don't like how my teeth look, especially my upper canines."

DIAGNOSIS
Right: Class II
Left: Class II

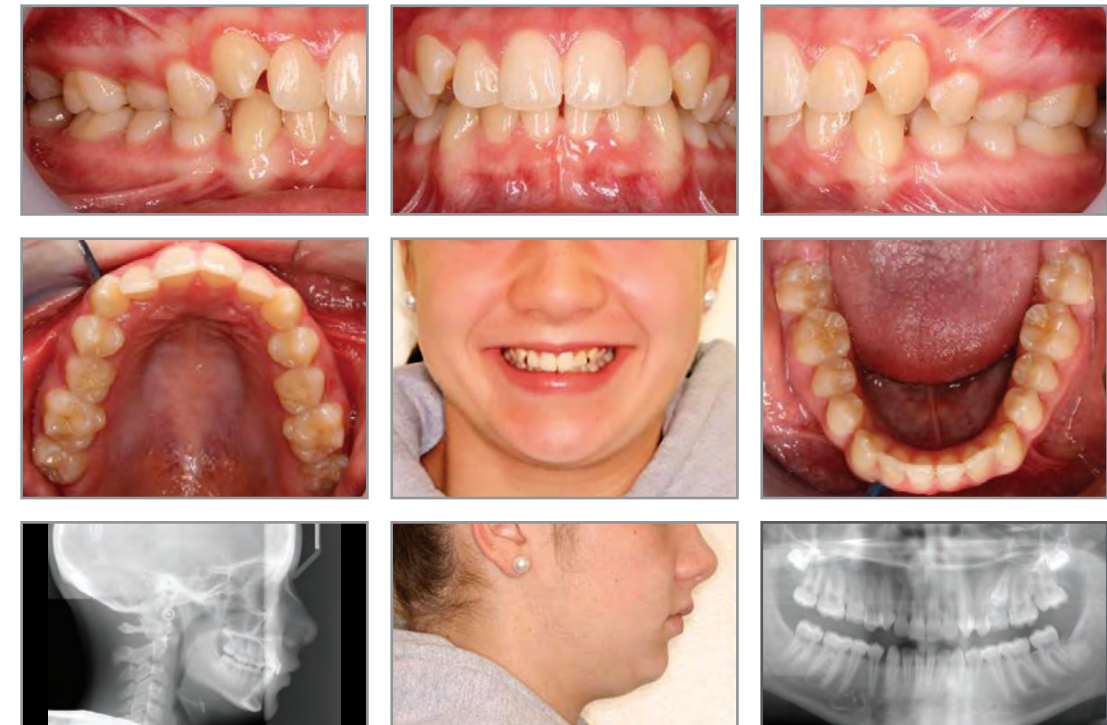
Division 1 malocclusion with retrognathic mandible. Obtuse nasolabial angle. Increased overbite and overjet. Upper crowding and lower spacing. No lower third molars present. Congenitally missing UR5. The UL5 was impacted and showed poor root development.

LENGTH OF TREATMENT 26 months Invisalign treatment + 9 months sectional braces

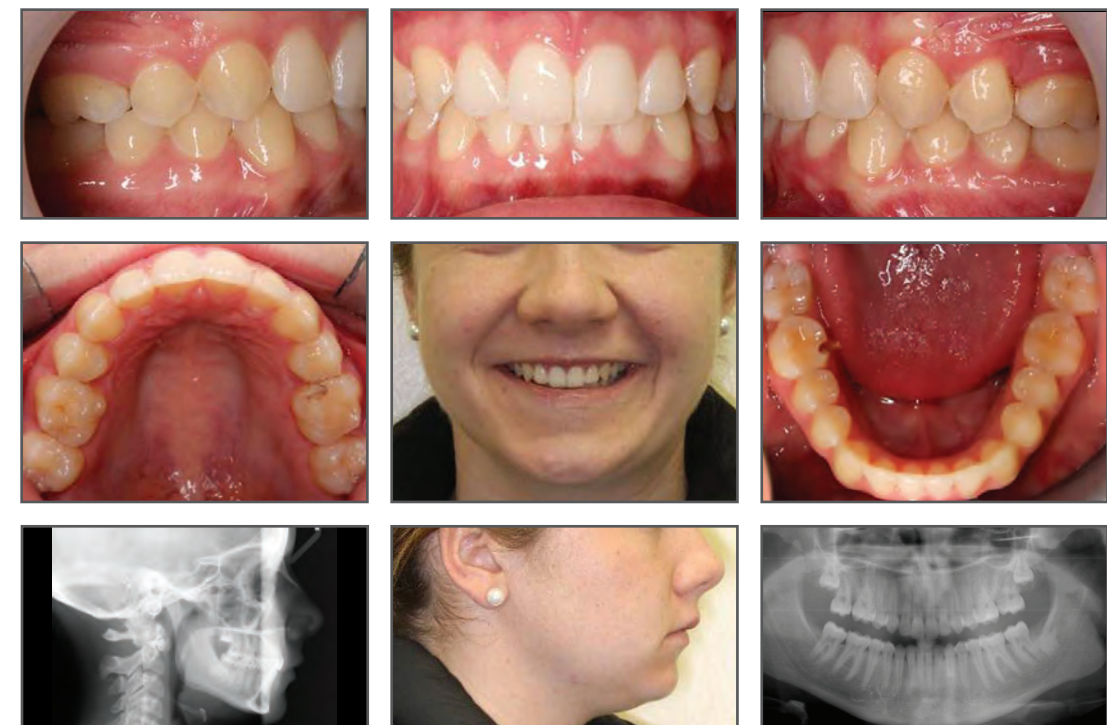
OF ALIGNERS USED
Upper: 32 + 19
Lower: 21 + 5

ADDITIONAL TREATMENT Extraction of UR5 and UL5. Sectional braces were used from the upper first bicuspid to the second molars during the last 9 months of treatment to upright the molar roots. A lingual retainer was bonded from UR4 to UL4 for maximum anterior anchorage during mesialization of the posterior teeth.

RETENTION
Upper: Hawley
Lower: Other clear



BEFORE



AFTER



Dr. Mark Lowe
Mark Lowe, DDS
Fresno, CA

www.drloweortho.com

TREATMENT SUMMARY

PATIENT 14-year-old female

CHIEF CONCERN The patient has crowding and excessive overjet.

DIAGNOSIS
Right: Class II
Left: Class II

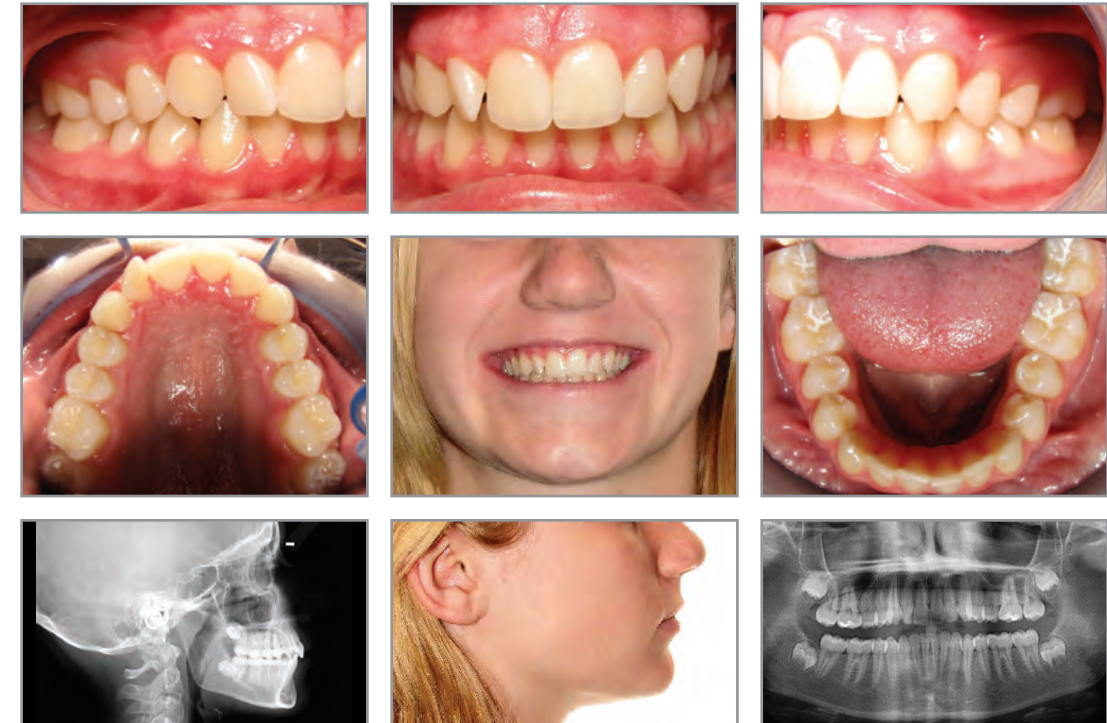
3 mm overjet and moderate deep overbite. Mild mandibular crowding and moderate maxillary crowding. Unerupted third molars.

LENGTH OF TREATMENT 20 months

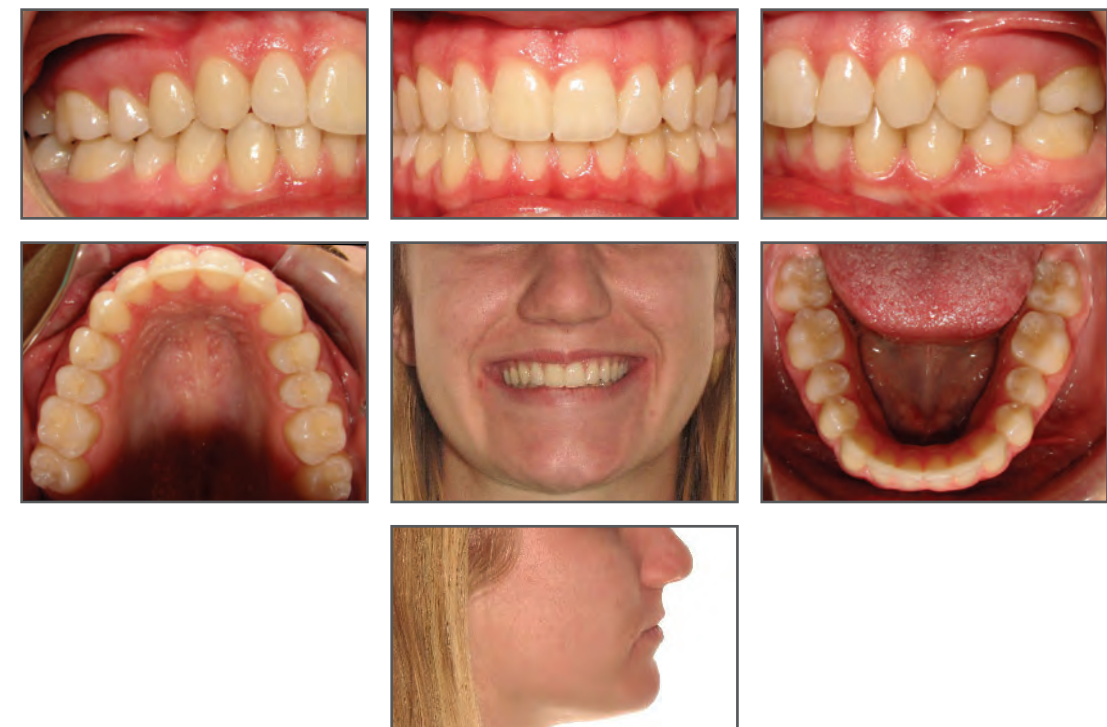OF ALIGNERS USED
Upper: 19 + 14
Lower: 12 + 12

ADDITIONAL TREATMENT Class II elastics were used for 10 months, with hooks cut into the aligners near the upper cuspids and buttons bonded to the lower first molars.

RETENTION
Upper: Last aligner
Lower: Last aligner



BEFORE



AFTER



Dr. Ramtin Nassiri
Solano Smile Dental Specialty Group
Albany, CA

www.solanosmile.com

TREATMENT SUMMARY

PATIENT 59-year-old female

CHIEF CONCERN "My bite has opened up in the last 2 to 3 years. It is hard to bite into food and my speech has been affected."

DIAGNOSIS
Right: Class I
Left: Class II

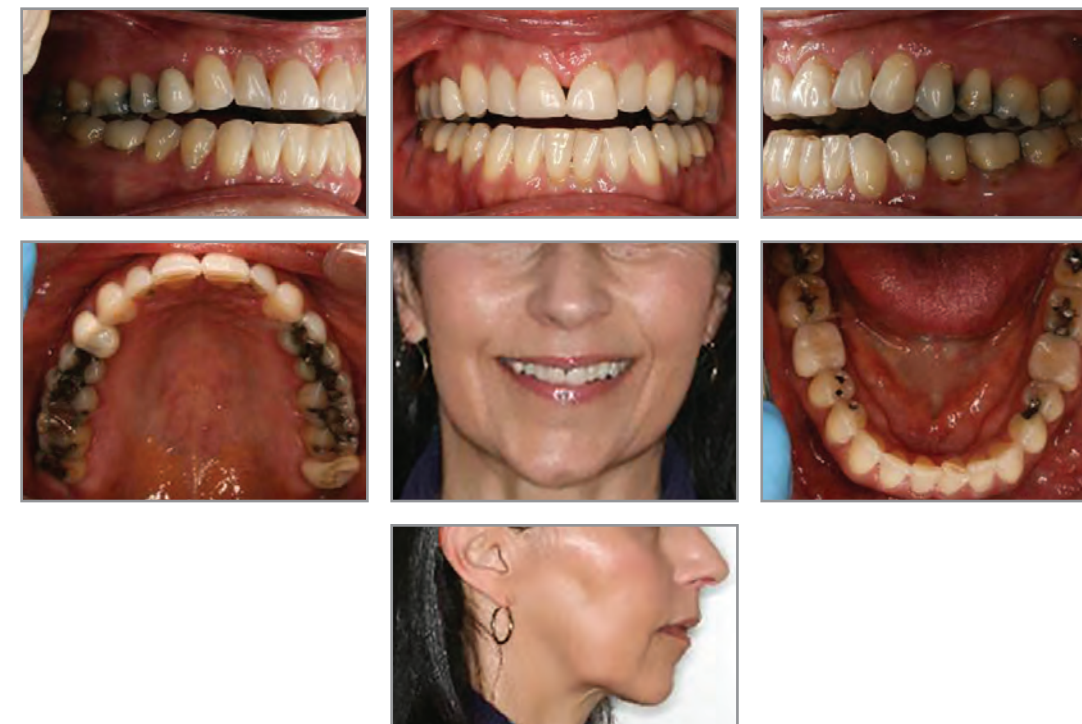4-5 mm anterior open bite and bilateral posterior open bite (sudden onset ~2.5 years ago). Severe osteoarthritis of both condyles, with a history of severe bruxism and pain of the TMJ (but asymptomatic for the past 18 months). Upper midline shifted to the right by 2 mm. Excessive overjet of 4 mm. Mild crowding in both arches.

LENGTH OF TREATMENT 17 months

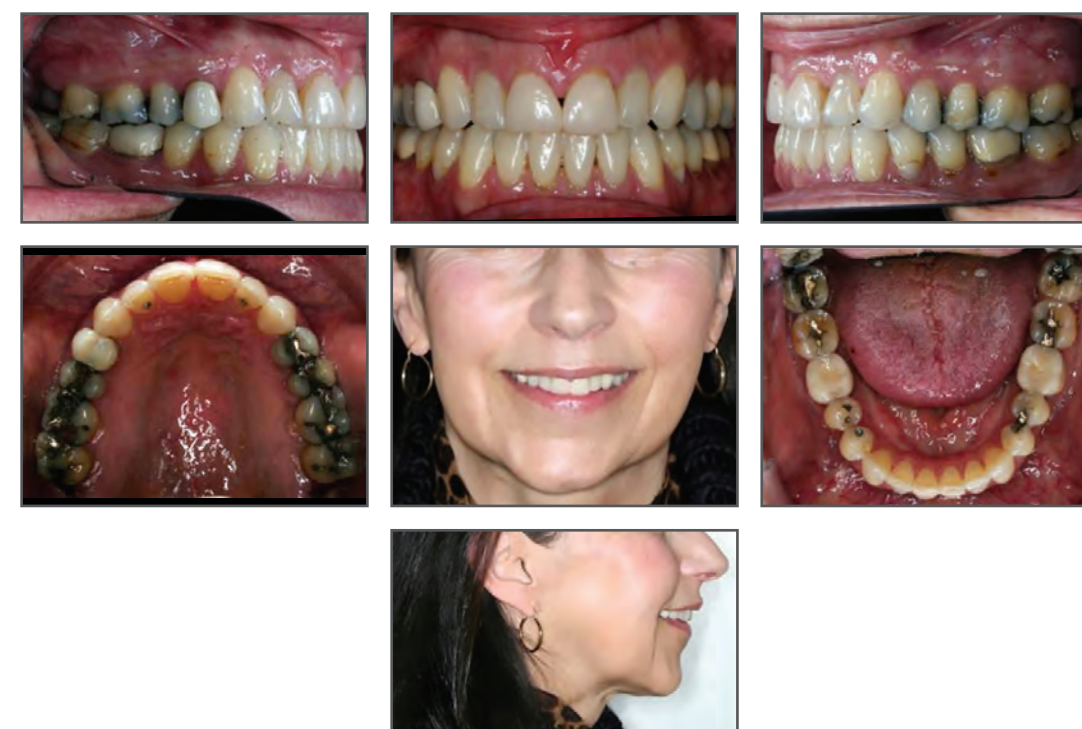OF ALIGNERS USED
Upper: 51
Lower: 51

ADDITIONAL TREATMENT TADs (4) were placed between U5's and U6's lingually, and U6's and U7's buccally. Sling elastics were worn for 6 months to intrude the maxillary molars. Class II elastics were used for 9 months on the left side, with a metal button bonded to the LL6 and a hook cut into the aligner near the UL3. Patient declined anterior attachments for extrusion. U8's were extracted after the completion of Invisalign treatment.

RETENTION
Upper: Essix® for 6 months, followed by Vivera®
Lower: Essix® for 6 months, followed by Vivera®



BEFORE



AFTER



Dr. Michelle Fogg Neal
Michelle Fogg Neal, DDS
Kirkland, WA

www.nealsmiles.com

TREATMENT SUMMARY

PATIENT 11-year-old female

CHIEF CONCERN The patient was concerned about her crowded teeth.

DIAGNOSIS
Right: Class II
Left: Class II

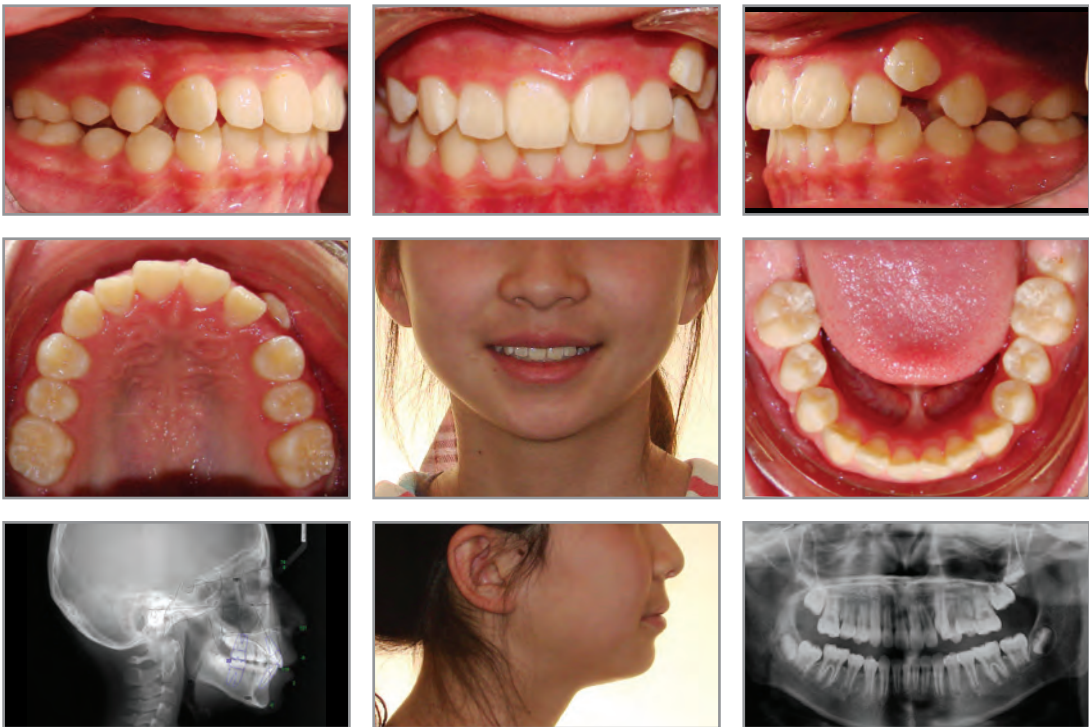Blocked-out and ectopically-erupting upper left canine. Mild upper and lower incisor crowding. Excessive overbite. Upper midline is deviated to the left. Upper and lower incisor root apices appear blunted on the initial panoramic film.

LENGTH OF TREATMENT 4 months Phase I treatment + 20 months Phase II Invisalign treatment

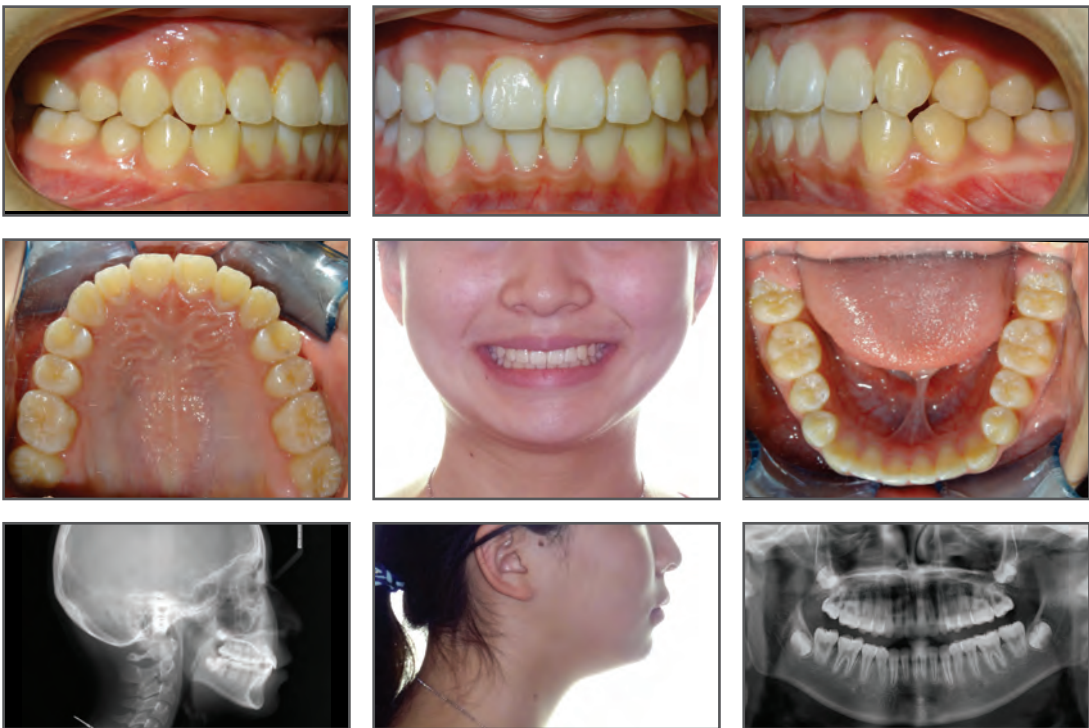OF ALIGNERS USED
Upper: 23 + 29
Lower: 20 + 29

ADDITIONAL TREATMENT Carriere® distalizer and lower lingual arch was used with Class II elastics for 4 months before Invisalign treatment. Class II elastics were used with the aligners for 12 months, with hooks cut into the aligners near the U3's and buttons bonded to the lower 6's.

RETENTION
Upper: Vivera®
Lower: Bonded lingual



BEFORE



AFTER



Dr. Bradley Nirenblatt
Nirenblatt Orthodontics
Charleston, SC

www.drnirenblatt.com

TREATMENT SUMMARY

PATIENT 56-year-old male

CHIEF CONCERN Severe crowding and anterior crossbite. The upper left lateral incisor looked "invisible" to the patient.

DIAGNOSIS
Right: Class II
Left: Class II

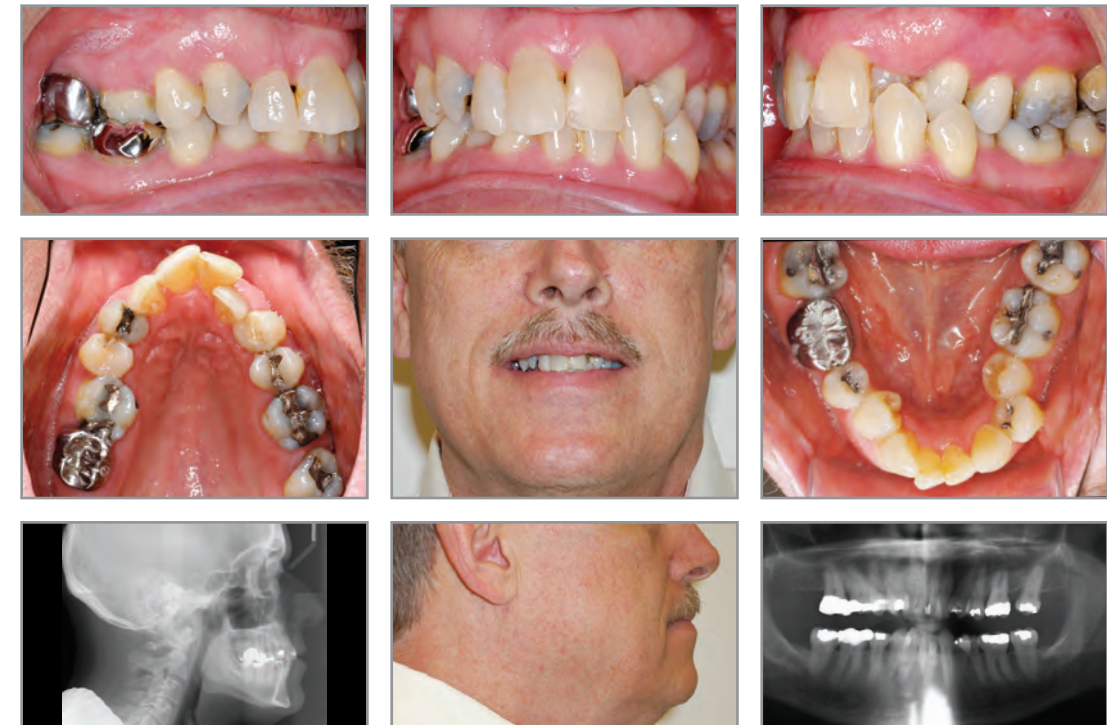Upper and lower crowding, with severe overbite and moderate overjet. Dental crossbite of #3, 10, 12. Missing teeth: #6, 11, 15, 23, and 26. Lower midline shifted to the left. Large restorations and mild localized gingival recession. Fair oral hygiene, with periodontium within normal limits.

LENGTH OF TREATMENT 15 months

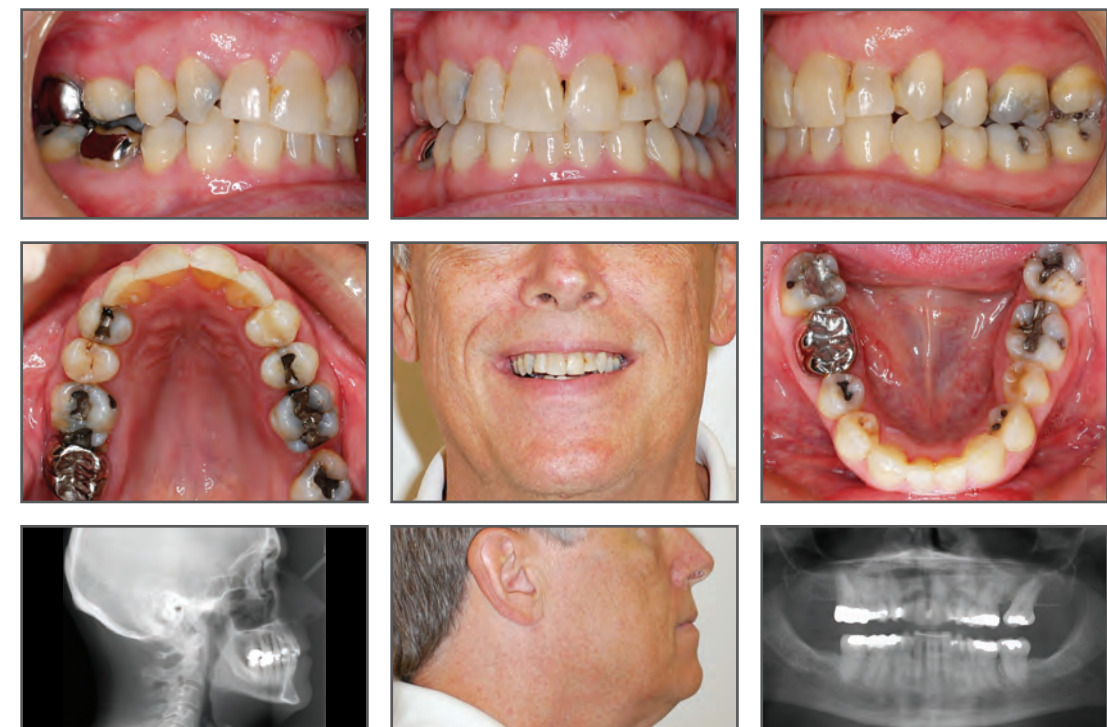OF ALIGNERS USED
Upper: 25 + 7
Lower: 26 + 8

ADDITIONAL TREATMENT None. The patient decided not to proceed with tooth whitening, veneers, or crown replacement after his orthodontic treatment was completed.

RETENTION
Upper: Other clear
Lower: Bonded lingual



BEFORE



AFTER



Dr. Bradley Nirenblatt
Nirenblatt Orthodontics
Charleston, SC

www.drnirenblatt.com

TREATMENT SUMMARY

PATIENT 26-year-old female

CHIEF CONCERN The patient has crowding, a deep bite, and uneven upper gingival margin heights.

DIAGNOSIS
Right: Class II
Left: Class II

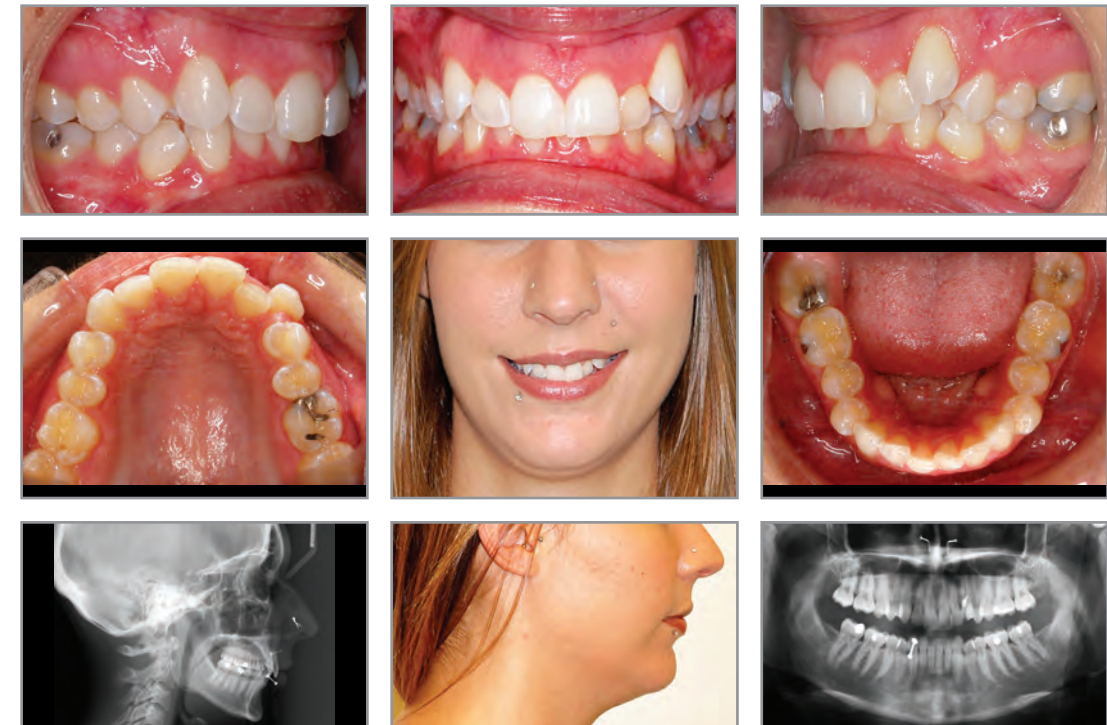
Severe overbite and moderate overjet, with retrognathic mandible, but no sign of TMJ problems. Upper and lower crowding, with upper midline shifted to the left and lower midline shifted to the right. Fair oral hygiene, with periodontal health within normal limits. Third molars not present.

LENGTH OF TREATMENT 17 months

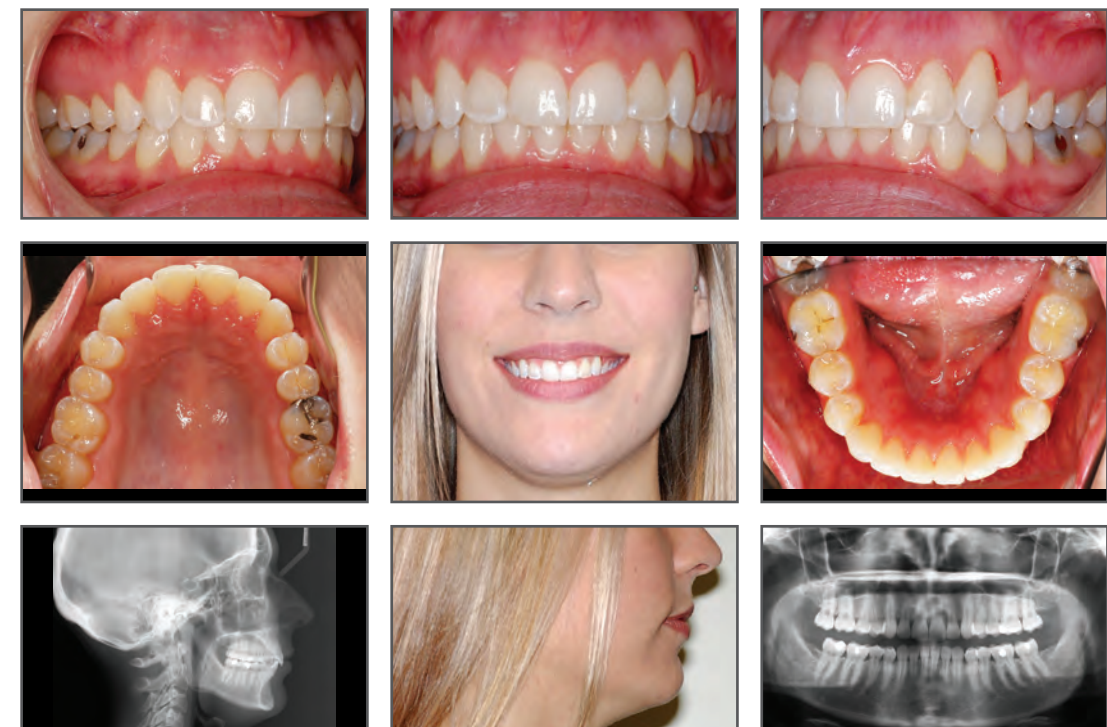
OF ALIGNERS USED
Upper: 39
Lower: 24

ADDITIONAL TREATMENT Vertical elastics were used for 5 months, with clear buttons bonded to the buccal of UL2 and UL3, and elastic hooks cut into the lingual area of the aligners.

RETENTION
Upper: Essix® retainer
Lower: Bonded lingual



BEFORE



AFTER



Drs. Robert and James Passamano
Passamano Orthodontics
Irvine, CA

www.youbraces.com

TREATMENT SUMMARY

PATIENT 13-year-old male

CHIEF CONCERN "I want to straighten my teeth without [fixed] braces, since my older sister had braces."

DIAGNOSIS
Right: Class II
Left: Class II

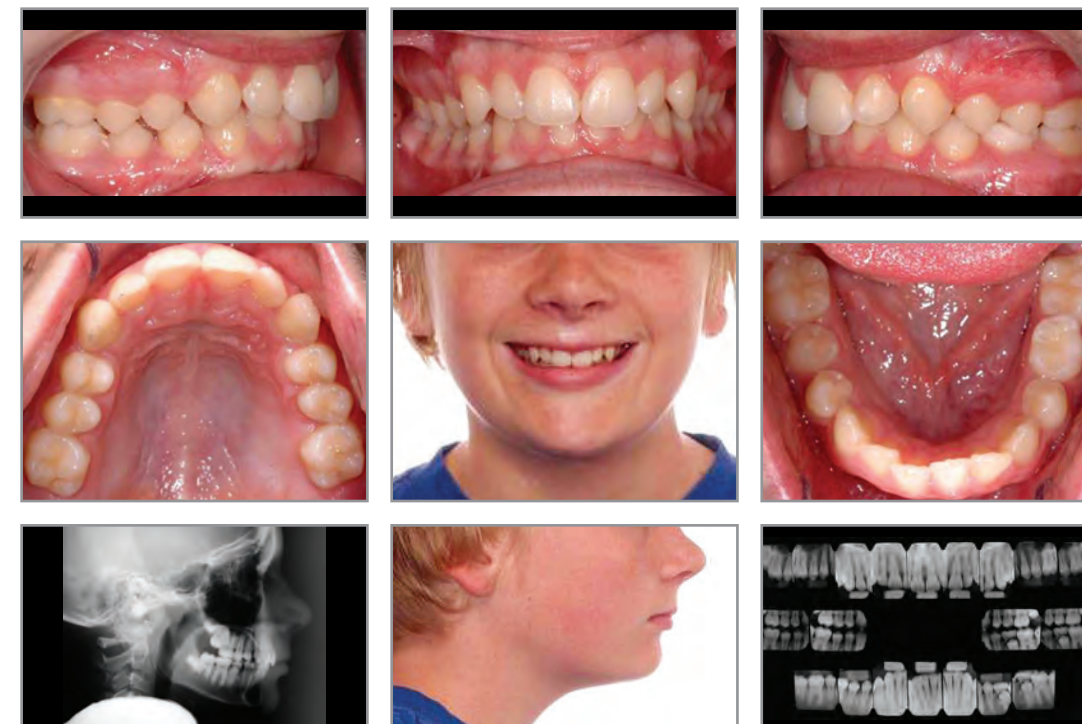
Convex facial profile. Mild upper and lower crowding. Lower dental midline shifted 0.75 mm to the left of the upper midline. 5 mm vertical overlap of the anterior teeth. The retained lower left deciduous second molar has an unresorbed root. The permanent 2nd bicuspid is present.

LENGTH OF TREATMENT 24 months

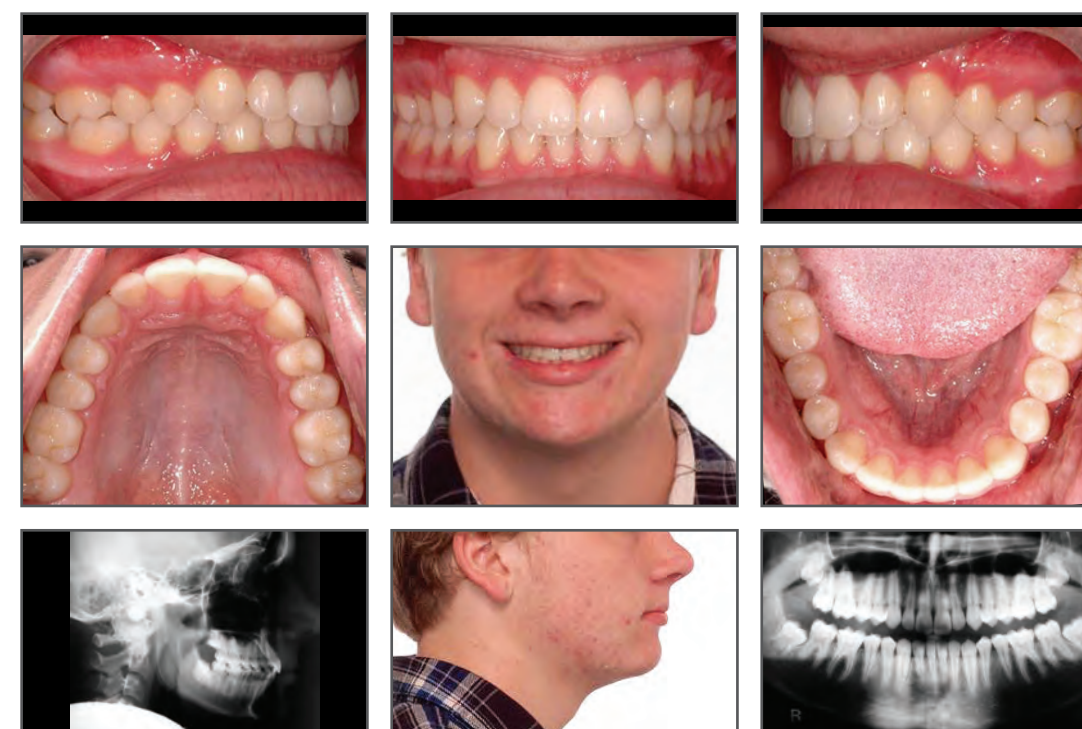
OF ALIGNERS USED
Upper: 17 + 13 + 18
Lower: 17 + 13 + 18

ADDITIONAL TREATMENT Class II elastics were used for 12 months, with hooks cut into the aligners near the upper canines and metal buttons bonded to #19 and #31.

RETENTION
Upper: Vivera®
Lower: Vivera®



BEFORE



AFTER



Drs. Robert and James Passamano
Passamano Orthodontics
Irvine, CA

www.youbraces.com

TREATMENT SUMMARY

PATIENT 12-year-old female

CHIEF CONCERN "I want to close all of my spaces."

DIAGNOSIS
Right: Class II
Left: Class II

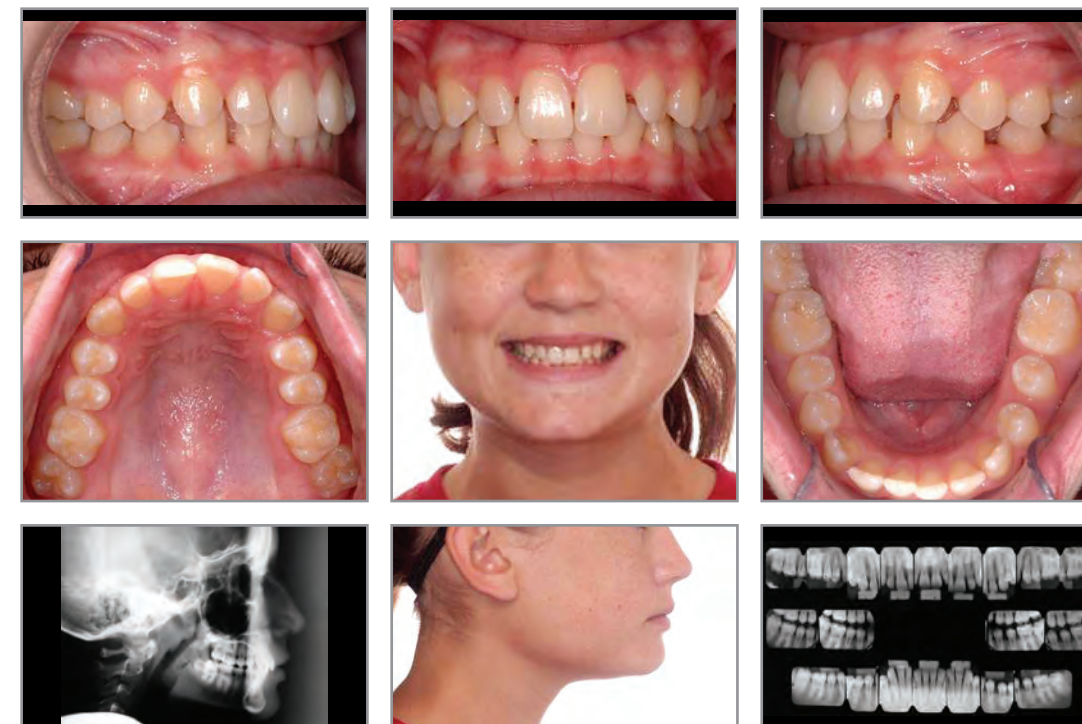Slightly convex facial profile. Moderate upper and lower spacing (~5 mm per arch). 3.5 mm vertical overlap of the anterior teeth. Bolton discrepancy of 3.8 mm mandibular excess. Upper and lower left second molars are in crossbite.

LENGTH OF TREATMENT 37 months

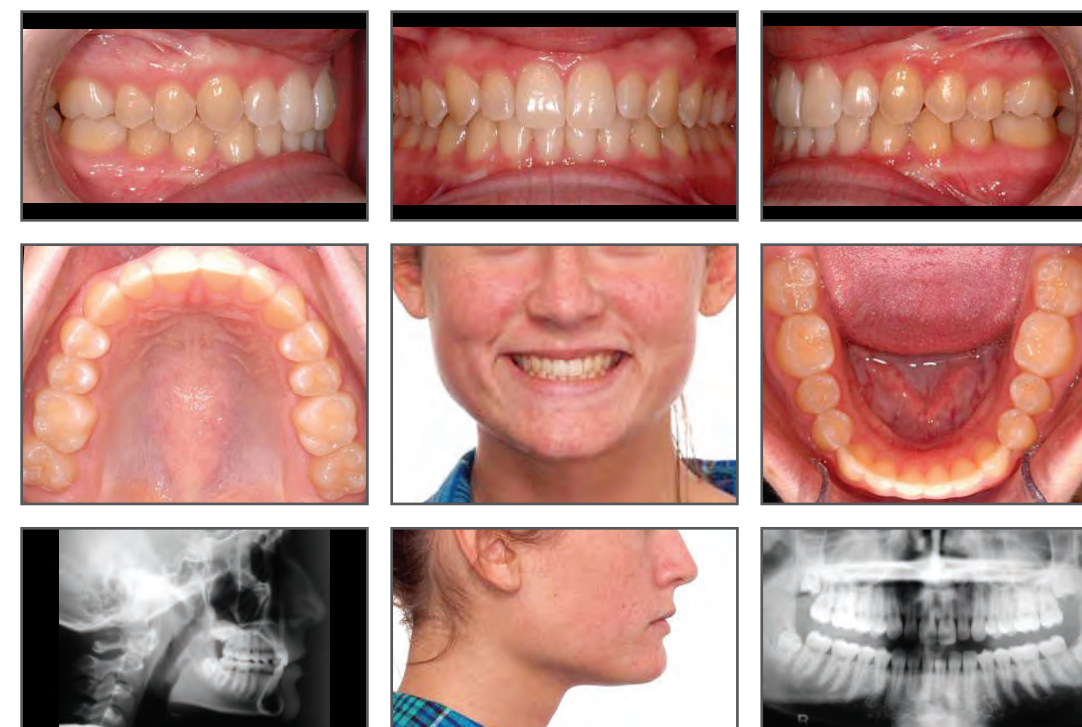
OF ALIGNERS USED
Upper: 22 + 12 + 12 + 13
Lower: 22 + 10 + 13 + 11

ADDITIONAL TREATMENT Class II elastics were used on and off for 18 months, with hooks cut into the upper aligners near the cuspids and metal buttons bonded to #19 and #31.

RETENTION
Upper: Vivera®
Lower: Vivera®



BEFORE



AFTER



Dr. Luis Piedade
Ritebite Orthodontics
Listowel, ON, Canada

www.ritebite.ca

TREATMENT SUMMARY

PATIENT 15-year-old male

CHIEF CONCERN "My teeth are not straight."

DIAGNOSIS
Right: Class II
Left: Class II

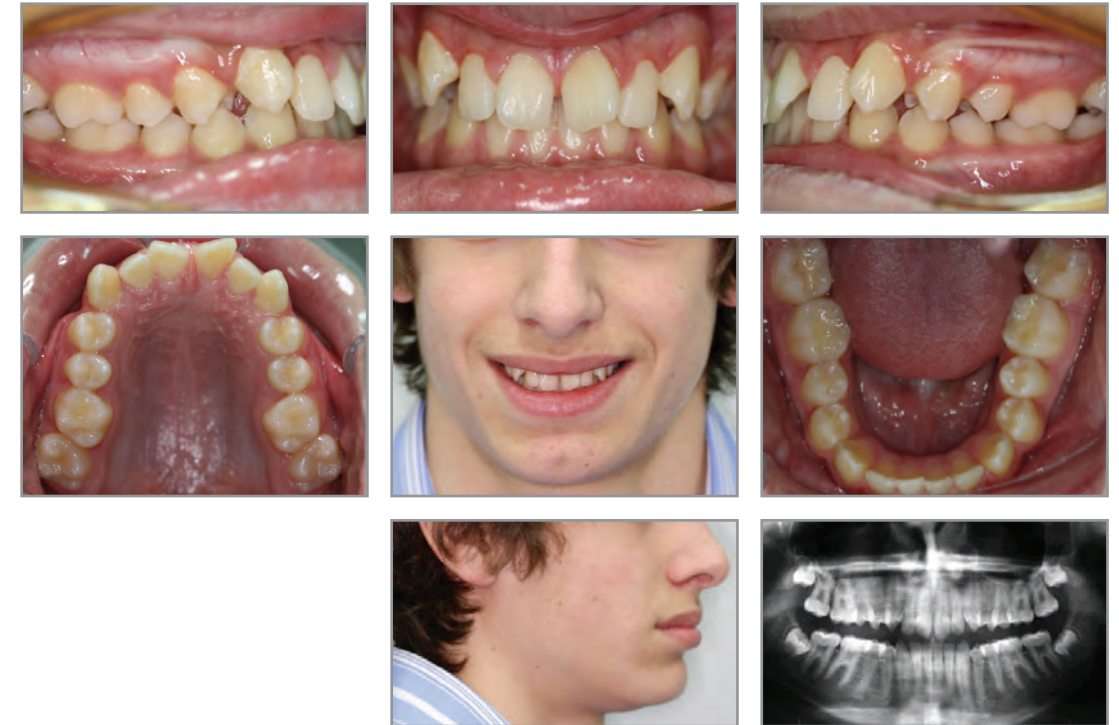Constricted maxillary arch with spaces and high canines, crowded lower arch, and a deep overbite.

LENGTH OF TREATMENT 17 months

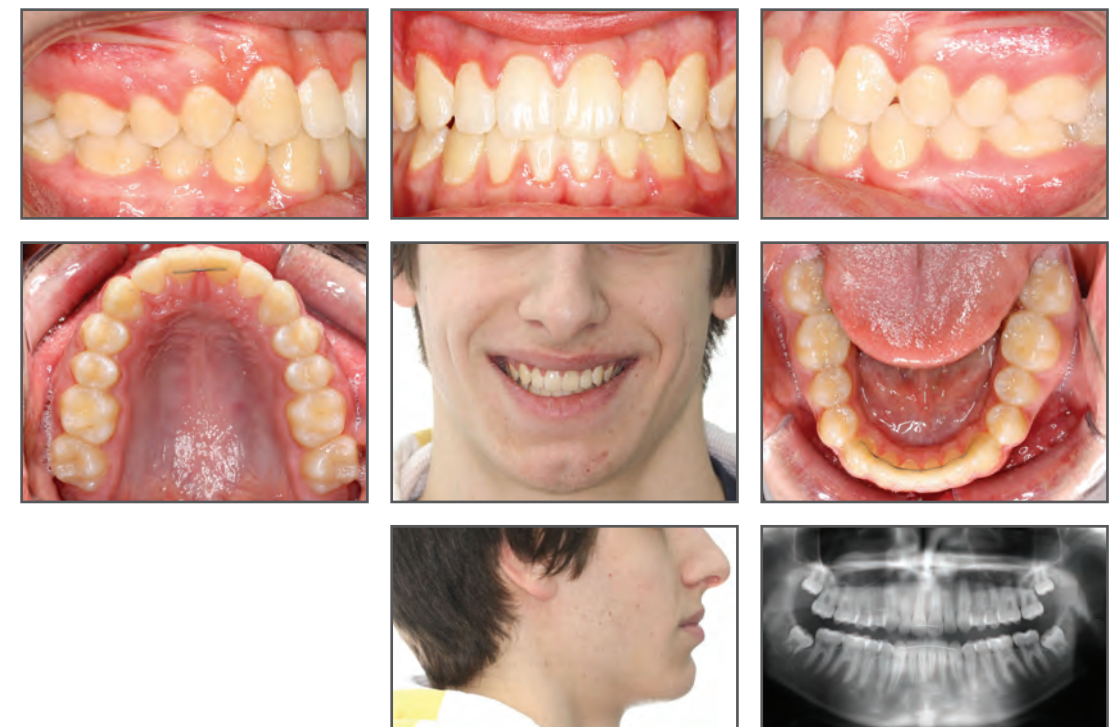OF ALIGNERS USED
Upper: 21 + 13
Lower: 21 + 12

ADDITIONAL TREATMENT Class II elastics were used for 17 months, with hooks cut into the aligners near the upper canines and lower first molars.

RETENTION
Upper: Essix® over bonded lingual
Lower: Bonded lingual



BEFORE



AFTER



Dr. Gregory Ross
Ross Orthodontics, Ltd.
Forest Lake, MN

www.rossodontics.com

TREATMENT SUMMARY

PATIENT 11-year-old female

CHIEF CONCERN The patient's main concern was her crowded top teeth.

DIAGNOSIS
Right: Class II
Left: Class II

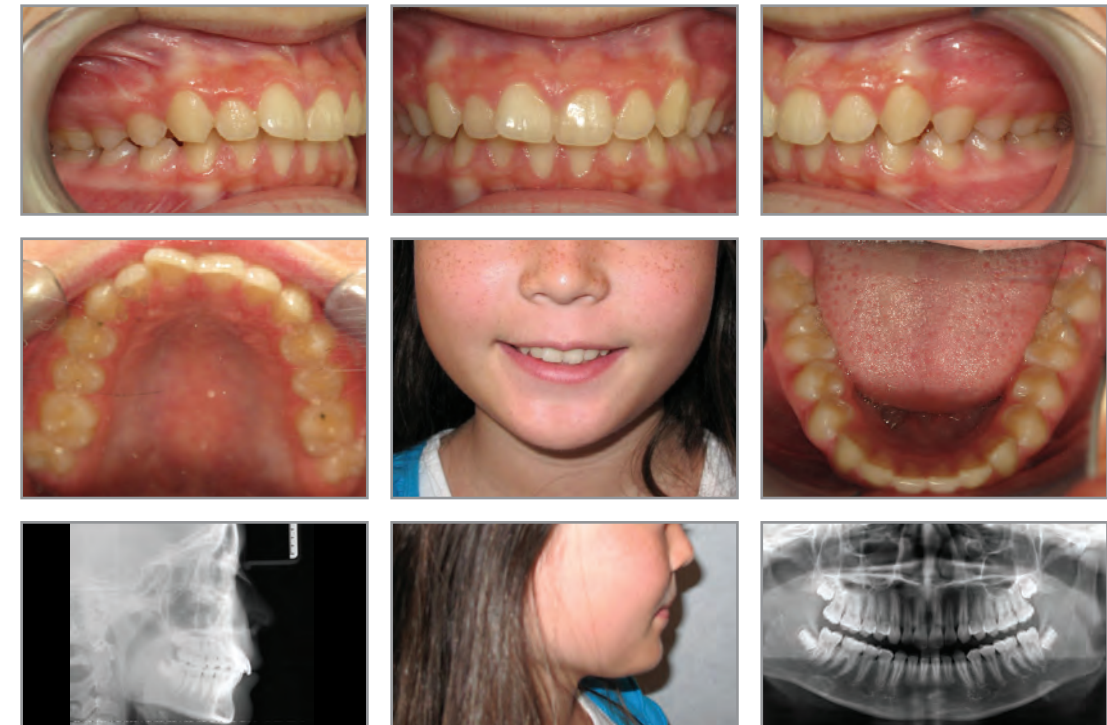
Excessive overjet and overbite. Patient has upper and lower crowding, a midline asymmetry, and a nail-biting habit.

LENGTH OF TREATMENT 11 months

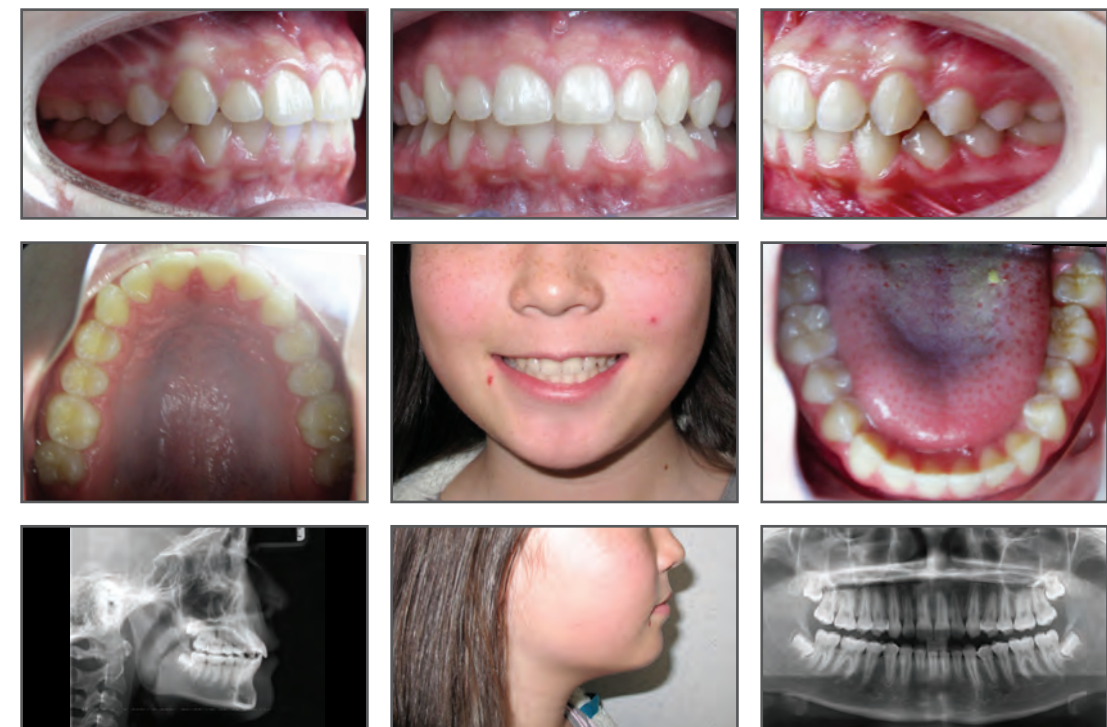
OF ALIGNERS USED
Upper: 19
Lower: 19

ADDITIONAL TREATMENT Class II elastics were used for 4 months, with hooks cut into the aligners near the upper canines and buttons bonded to the lower first molars.

RETENTION
Upper: Other clear
Lower: Other clear



BEFORE



AFTER



Dr. Vishal Sharma
Aura Orthodontics
Surrey, BC, Canada

www.auraortho.com

TREATMENT SUMMARY

PATIENT 32-year-old male

CHIEF CONCERN "I want a perfect smile for my wedding." The patient had a deep bite and flared teeth.

DIAGNOSIS Right: Class II
Left: Class II

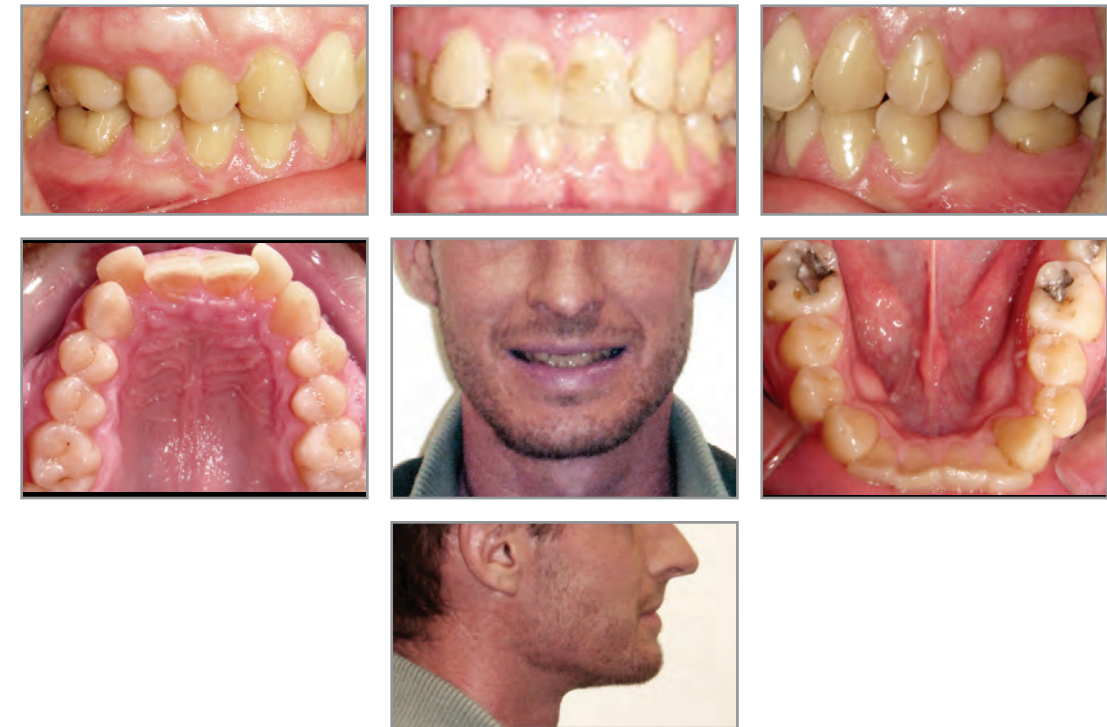Division 2 malocclusion (proclined upper lateral incisors and retroclined central incisors). Moderate upper and lower crowding. 5-6 mm overjet and 50% overbite. Obtuse nasolabial angle and shallow labiomental sulcus.

LENGTH OF TREATMENT 16 months

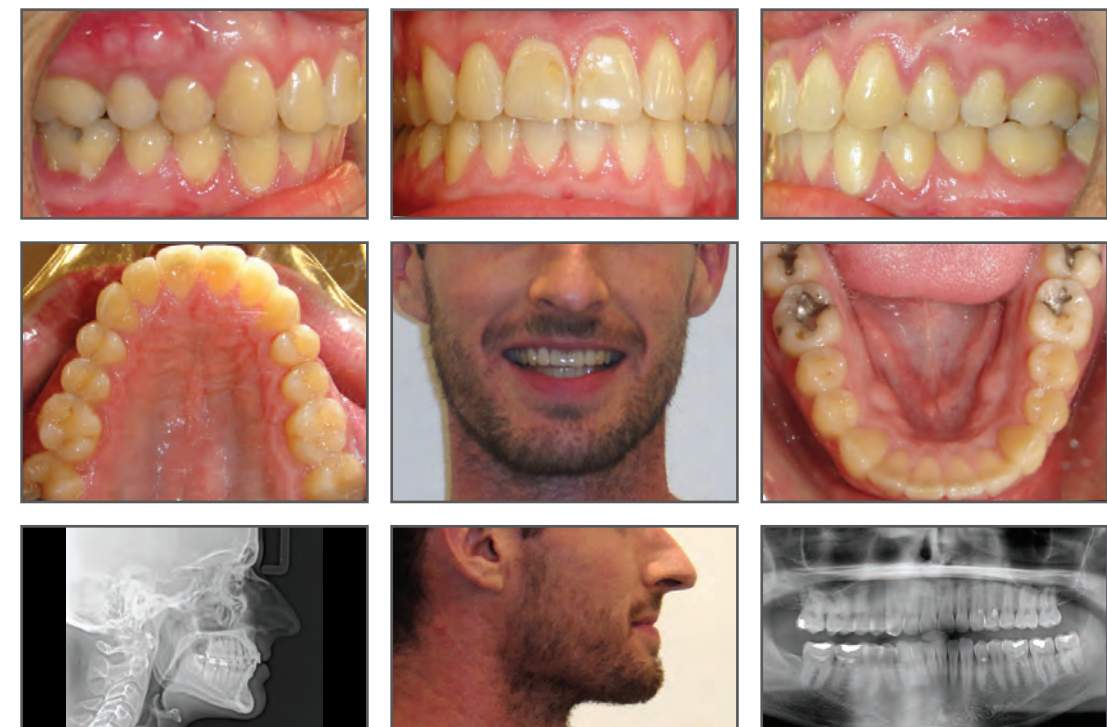OF ALIGNERS USED Upper: 33
Lower: 14

ADDITIONAL TREATMENT Class II elastics (1/4" 4.5 oz.) were worn at night for 10 months. Hooks were cut into the aligners near the upper canines and buttons were bonded to the lower first molars.

RETENTION Upper: Other clear
Lower: Other clear



BEFORE



AFTER



Dr. Kurt Silberstein
Silberstein Orthodontics
Highland Park, IL

www.silbortho.com

TREATMENT SUMMARY

PATIENT 14-year-old female

CHIEF CONCERN The main concern was her crossbite. The patient really wanted Invisalign, but her parents were very apprehensive about Invisalign treatment because another orthodontist had already told them that she was not a good candidate.

DIAGNOSIS Right: Class I
Left: Class II

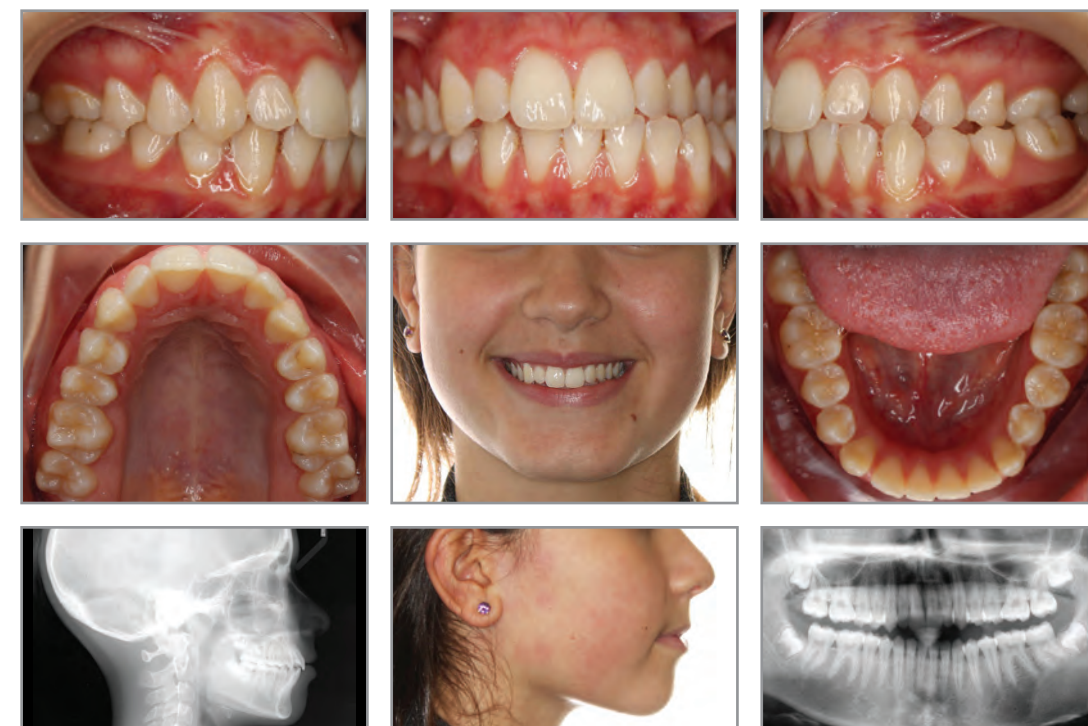Division 1, subdivision left malocclusion. Minimal overbite and overjet, with significant lower midline discrepancy towards the left. Crossbite and rotated cuspids on the left side. Lower anterior spacing. Thin lower attached gingiva.

LENGTH OF TREATMENT 3 months Phase I treatment + 12 months Phase II Invisalign treatment

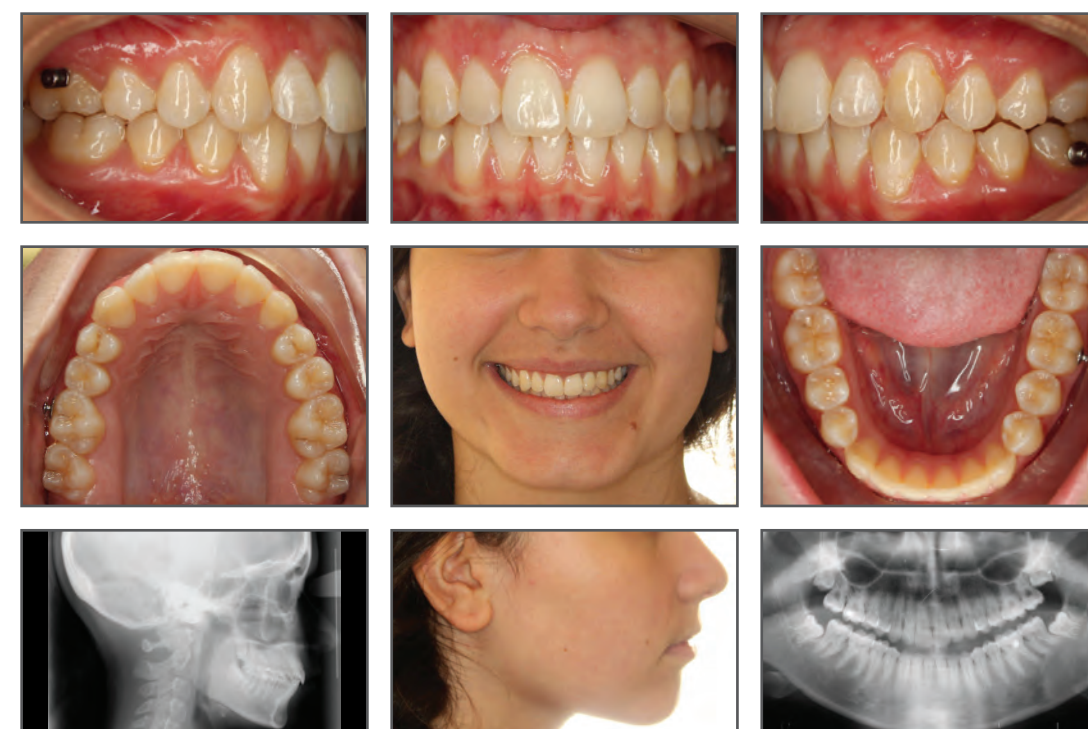OF ALIGNERS USED Upper: 17 + 4
Lower: 17 + 4

ADDITIONAL TREATMENT A rapid palatal expander (RPE) was used for 3 months prior to Invisalign treatment. Class II elastics were used on the left side, with a hook cut into the aligner near the UL3 and a button bonded to the LL6. Class III elastics were used on the right side, with a hook cut into the aligner near the LR3 and a button bonded to the UR6. Elastics were worn for 2 months.

RETENTION Upper: Vivera®
Lower: Vivera®



BEFORE



AFTER



Dr. John Sparaga
Clear Smiles Alaska
Anchorage, AK

www.clearsmilesalaska.com

TREATMENT SUMMARY

PATIENT 14-year-old female

CHIEF CONCERN The patient was concerned about her smile aesthetics and deep overbite.

DIAGNOSIS
Right: Class II
Left: Class II

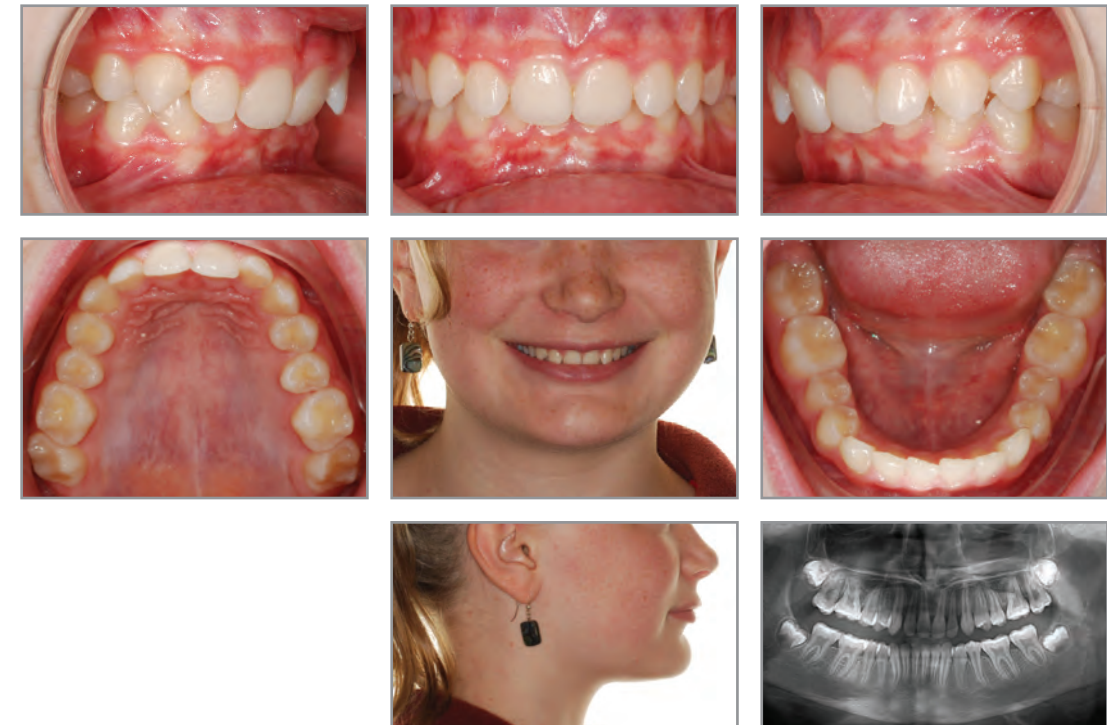Division 2 malocclusion. Deep bite, bimaxillary dental protrusion, and retruded chin.

LENGTH OF TREATMENT 7 months Phase I treatment + 16 months Phase II Invisalign treatment

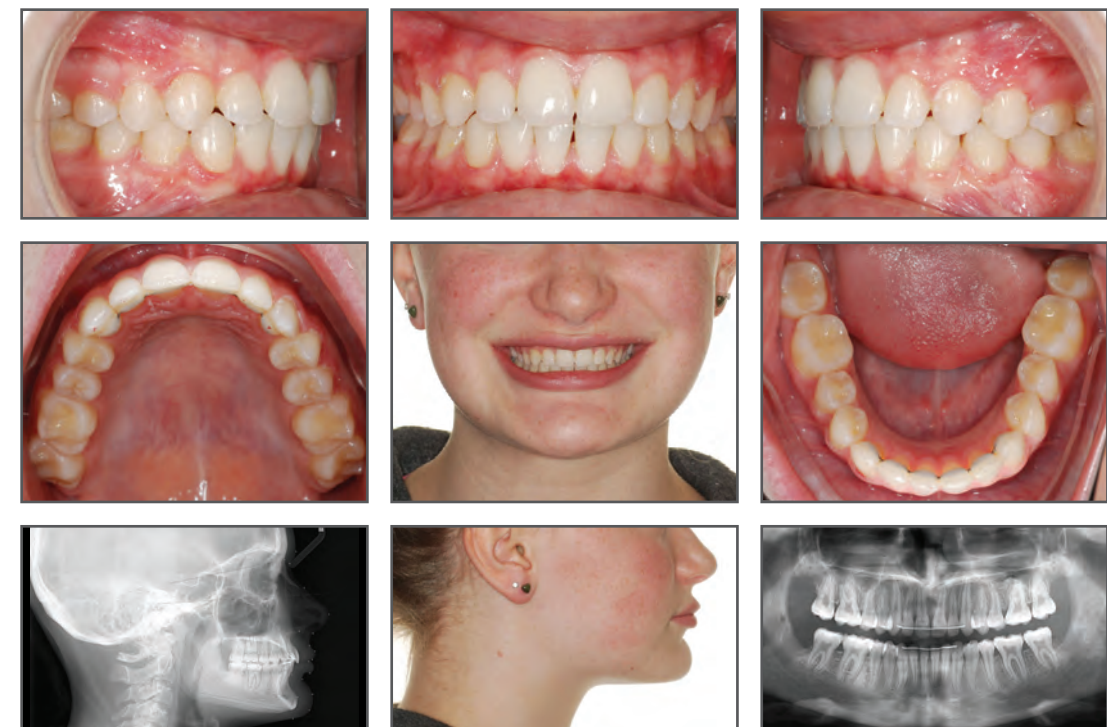
OF ALIGNERS USED
Upper: 30
Lower: 30

ADDITIONAL TREATMENT A MARA appliance was used for 7 months prior to Invisalign treatment, followed by U2-2 sectional braces for 5 months to close spaces from the MARA appliance. Class II elastics were used for 6 months, with buttons added to the aligners near the upper cuspids and lower first molars. Anterior bite ramps were bonded during retention to help open the bite.

RETENTION
Upper: Bonded lingual
Lower: Bonded lingual



BEFORE



AFTER



Dr. John Sparaga
Clear Smiles Alaska
Anchorage, AK

www.clearsmilesalaska.com

TREATMENT SUMMARY

PATIENT 35-year-old male

CHIEF CONCERN The patient's main concerns were his smile aesthetics, a deep bite, and his diastema.

DIAGNOSIS
Right: Class II
Left: Class I

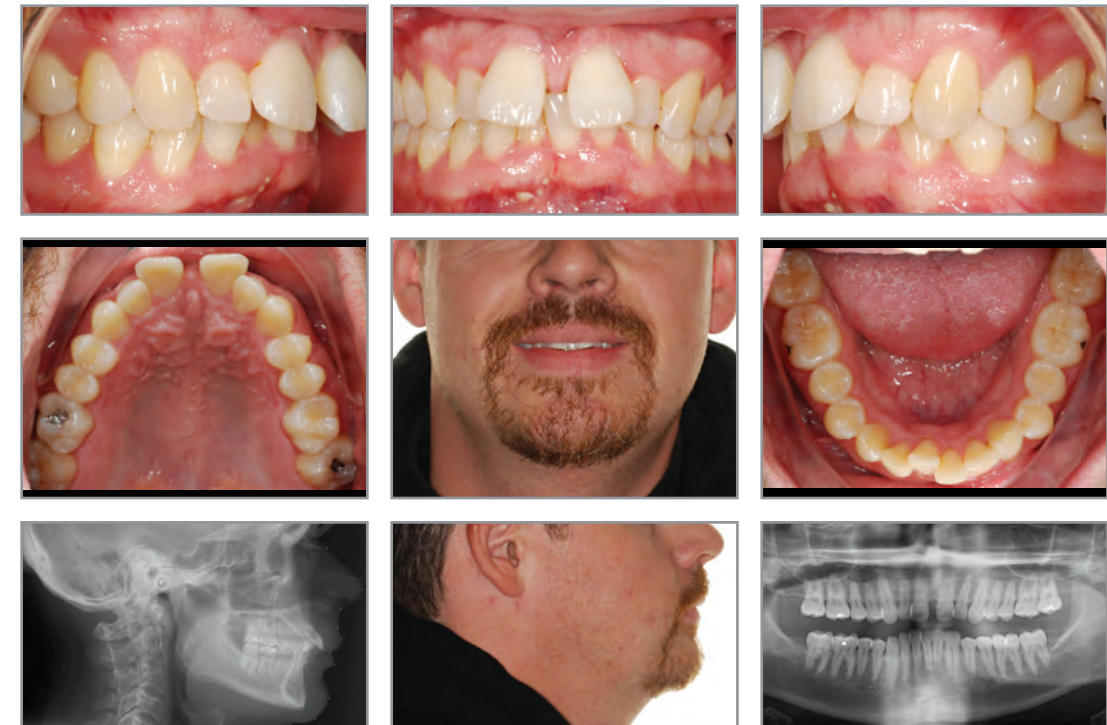Anterior deep bite. Maxillary diastema. Left side is Class I molar and Class II cuspid.

LENGTH OF TREATMENT 23 months

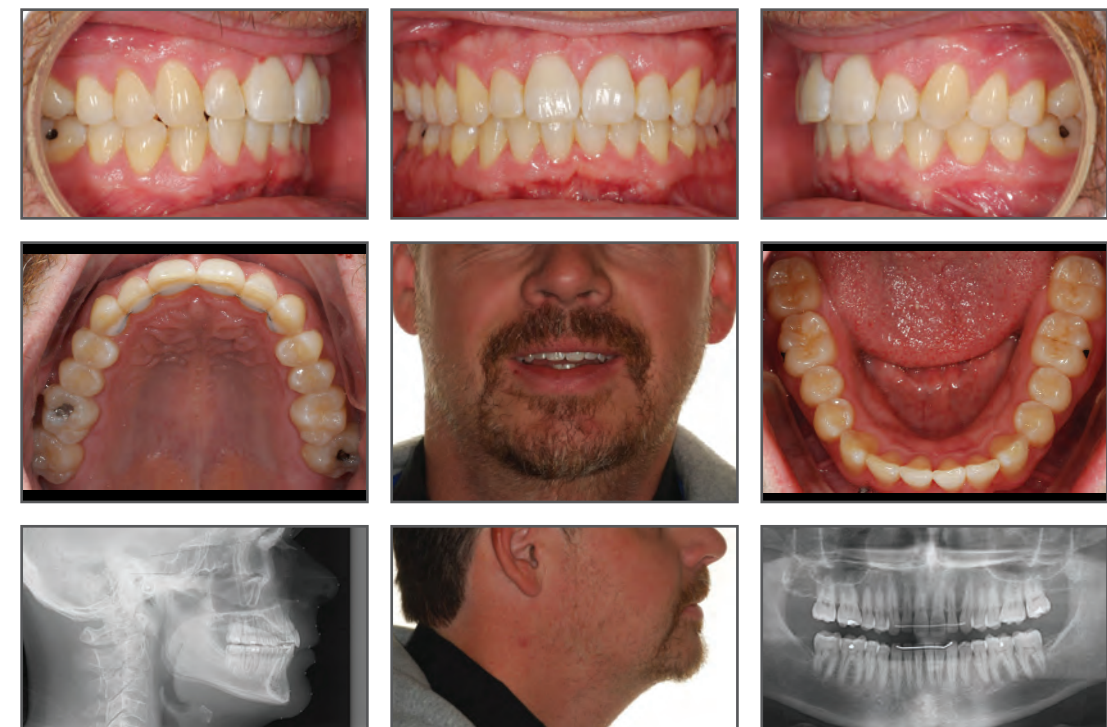OF ALIGNERS USED
Upper: 23 + 19
Lower: 22 + 19

ADDITIONAL TREATMENT Vertical elastics were used for 6 months for intrusion, with hooks cut into the aligner near teeth #23 and #26, and TADs (2) placed between #22/23 and #26/27. Class II elastics were used for 19 months at night only, with hooks cut into the upper aligners near the cuspids and buttons bonded to the lower first molars.

RETENTION
Upper: Bonded lingual
Lower: Bonded lingual



BEFORE



AFTER



Dr. Sandra Tai
Dr. Sandra Tai, Inc.
Richmond, BC, Canada

www.dr tai.com

TREATMENT SUMMARY

PATIENT 16-year-old female

CHIEF CONCERN The patient was concerned about her tipped-back front teeth, flared-out lateral incisors, and deep overbite.

DIAGNOSIS
Right: Class II
Left: Class II

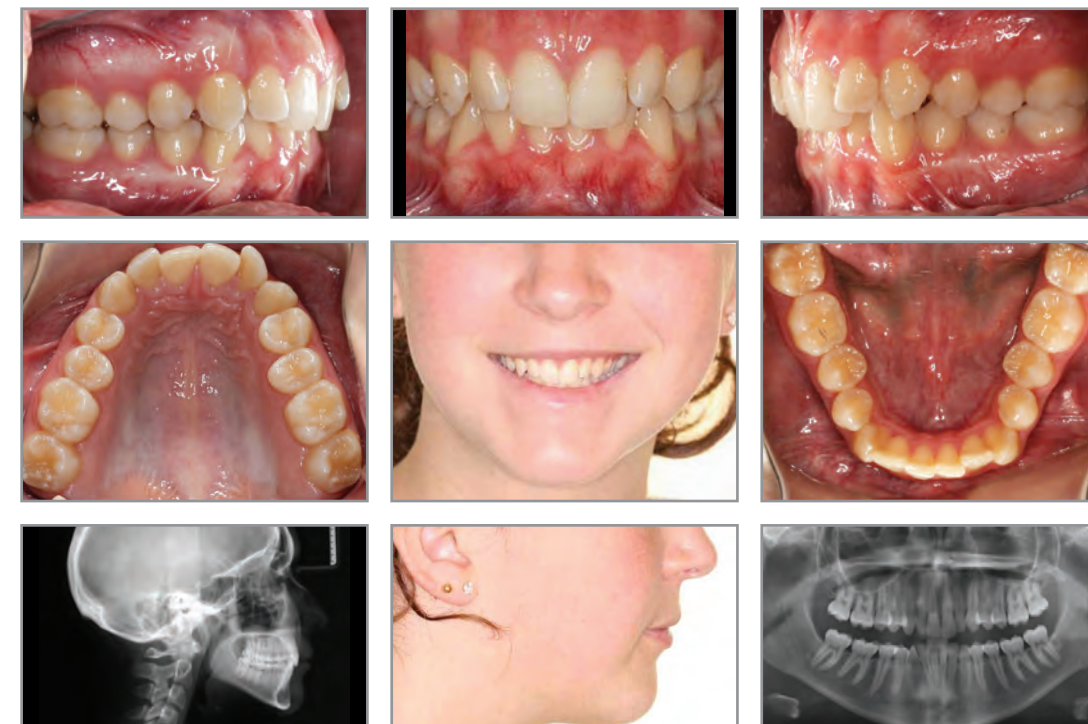
Class II skeletal tendency (ANB = +4 degrees), with Division 2 malocclusion, deep overbite (90%), and 2 mm overjet. Mild crowding in both arches, with retruded upper and lower incisors, and increased interincisal angle. Upper left canine is rotated 45 degrees. Lower dental midline is shifted 2 mm to the right.

LENGTH OF TREATMENT 17 months

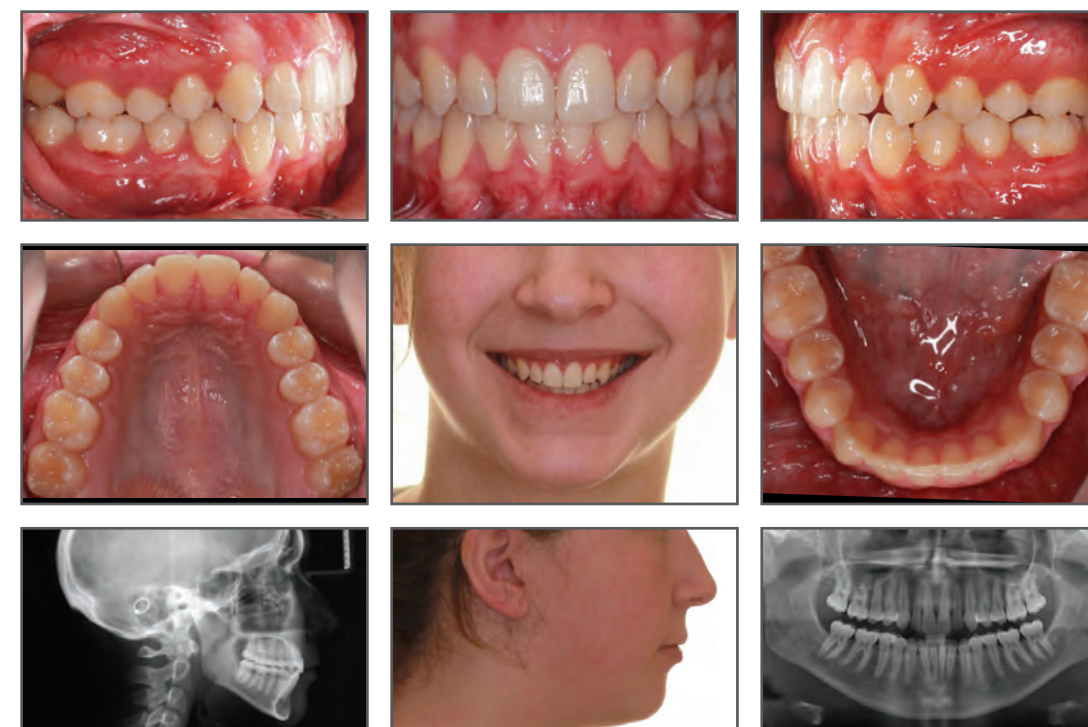
OF ALIGNERS USED
Upper: 41
Lower: 20

ADDITIONAL TREATMENT To support sequential distalization, Class II elastics were used full-time for 12 months followed by night-time wear for 6 months, with hooks cut into the aligners near the upper first premolars and the lower first molars. Elastics were also used for extrusion for 3.5 months, with buccal/lingual buttons bonded to both upper lateral incisors.

RETENTION
Upper: Other clear
Lower: Other clear over bonded lingual



BEFORE



AFTER



Dr. Samie Thabet
Thabet Orthodontics
Germantown, MD

www.thabetorthodontics.com

TREATMENT SUMMARY

PATIENT 12-year-old female

CHIEF CONCERN The patient was concerned about her crowded teeth, and the canines being out of proper arch alignment and not fully erupted.

DIAGNOSIS
Right: Class II
Left: Class II

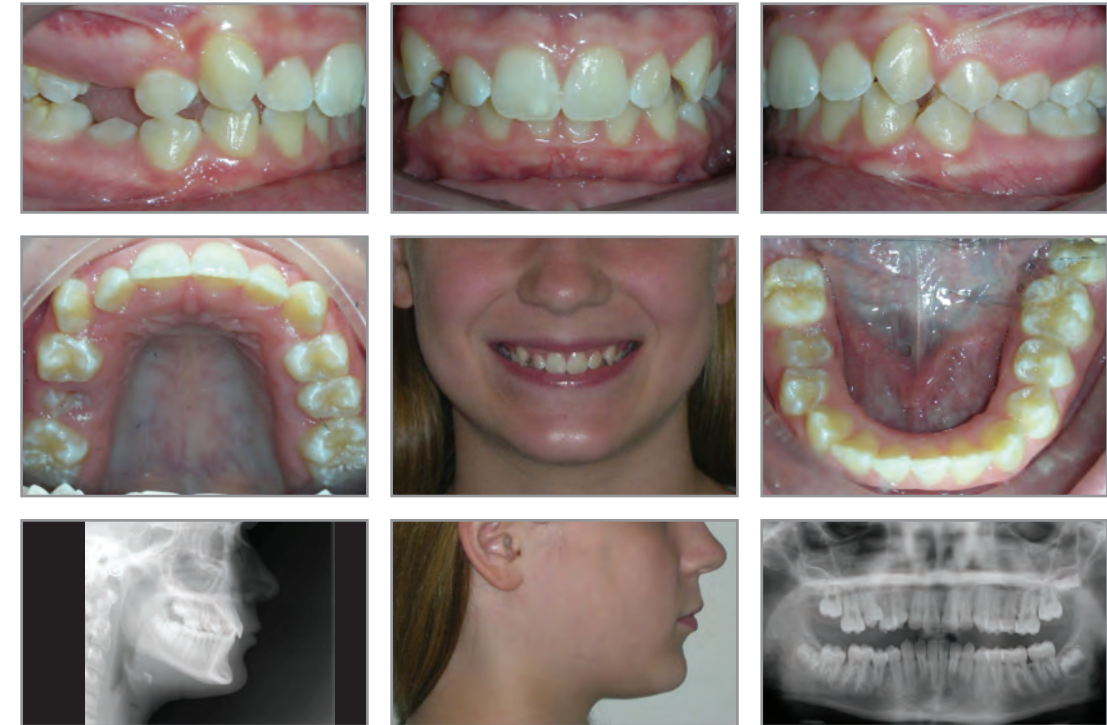
Mild overjet and moderate overbite. Moderate crowding in the upper arch and mild crowding in the lower arch. Excessive gingival display on smiling.

LENGTH OF TREATMENT 26 months

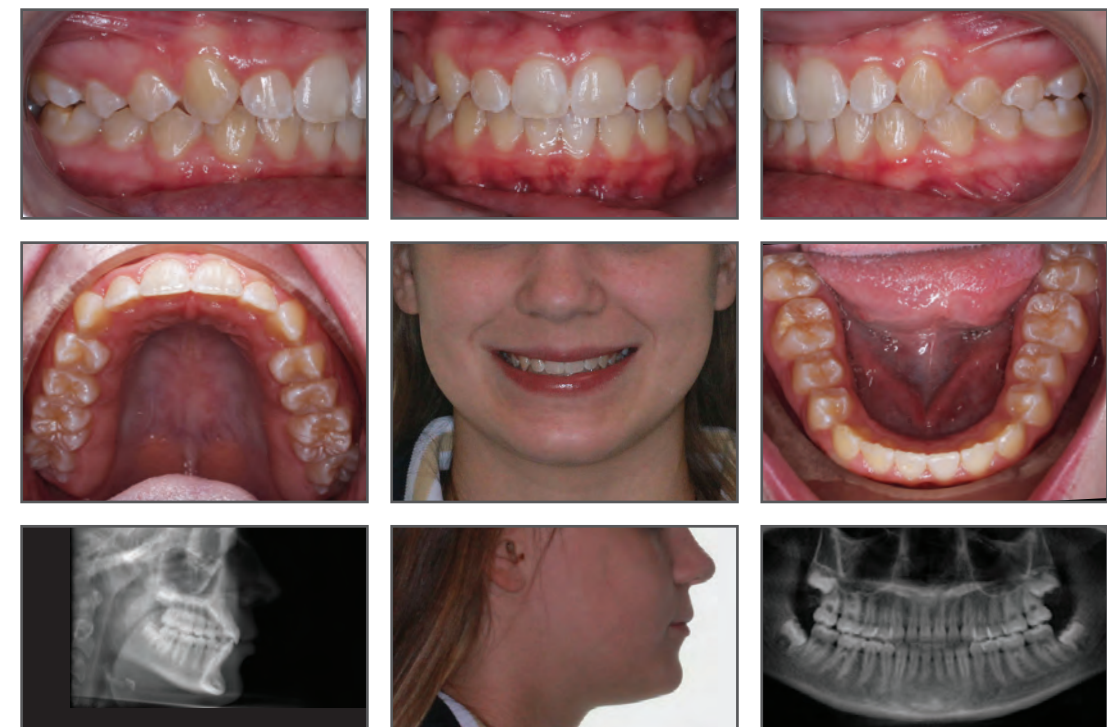
OF ALIGNERS USED
Upper: 34 + 12
Lower: 34 + 11

ADDITIONAL TREATMENT Class II elastics were used for 15 months, with hooks cut into the aligners near the upper cuspids and lower first molars.

RETENTION
Upper: Vivera®
Lower: Vivera®



BEFORE



AFTER



Dr. Maureen Valley
Valley Orthodontics
San Rafael, CA

www.valleyorthodontics.net

TREATMENT SUMMARY

PATIENT 15-year-old female

CHIEF CONCERN "Crooked teeth" (ectopic maxillary canines).

DIAGNOSIS
Right: Class II
Left: Class II

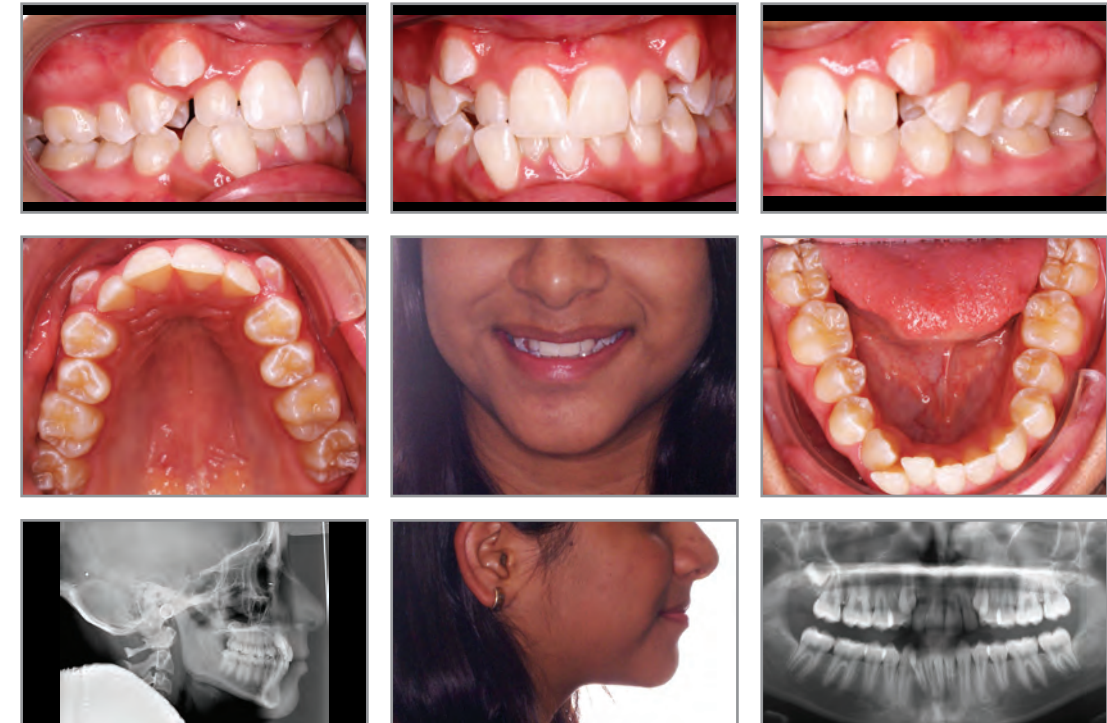
Skeletal Class II with Class II molar and canine relationship. 3 mm overbite and 2 mm overjet. Crossbite of tooth #7 with #26. Lower midline shifted to the right by 4 mm. Severe upper and lower crowding with constricted arches. Ectopic eruption of #6 and #11. Mild gingival recession around #26. Moderately short roots for #5, 7, 8, 10, and 12. Tooth #9 has a severely short root.

LENGTH OF TREATMENT 38 months

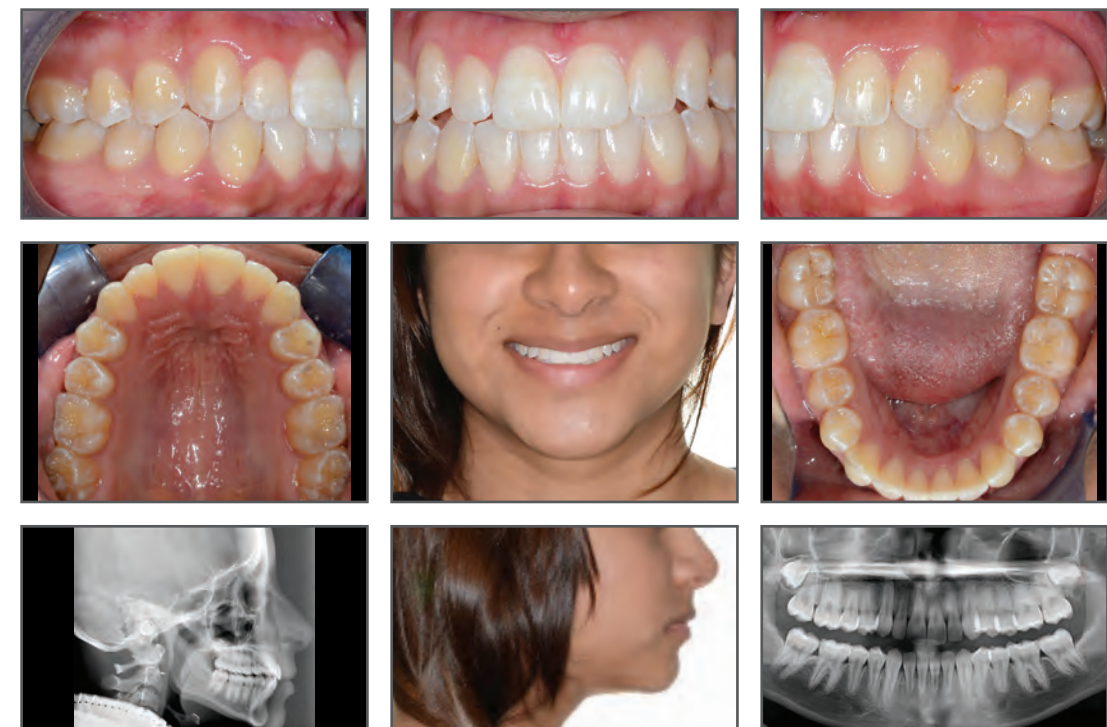
OF ALIGNERS USED
Upper: 13 + 24 + 18
Lower: 13 + 24 + 18

ADDITIONAL TREATMENT Class II elastics were worn full-time during the initial aligner series, with buttons bonded to the U4's and L7's. During the first refinement, Class II elastics were worn full-time, with buttons bonded to the U4's and L7's. Triangular elastics were also used, with buttons bonded to the U3's and L3/4's. The use of aligner Chewies™ was encouraged throughout treatment, but they were only used sporadically.


RETENTION
Upper: Other clear
Lower: Other clear



BEFORE



AFTER



Dr. Jenny Zhu
Manhattan Bridge Orthodontics
New York, NY

www.manhattanbridgeortho.com

TREATMENT SUMMARY

PATIENT 23-year-old female

CHIEF CONCERN The patient wanted to straighten her teeth, but avoid extractions if possible. Two other doctors had recommended braces with extraction of two upper bicuspids.

DIAGNOSIS Right: Class II
Left: Class II

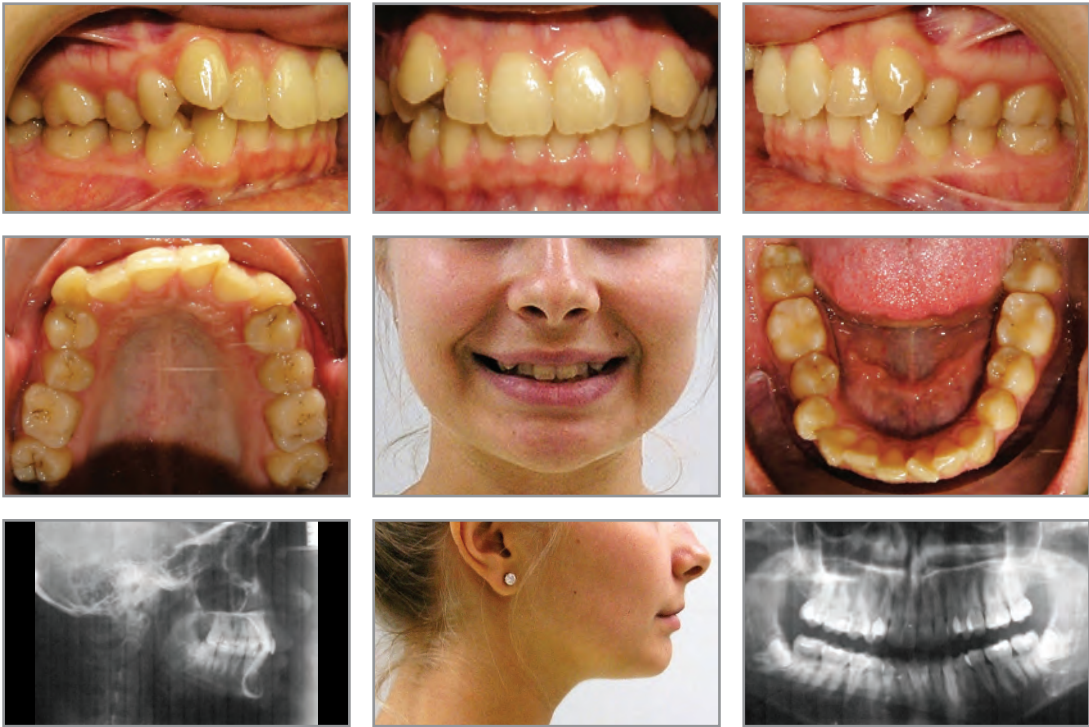Division 2 malocclusion. Moderate deep overbite (~70%). Severe maxillary crowding and moderate mandibular crowding.

LENGTH OF TREATMENT 20 months

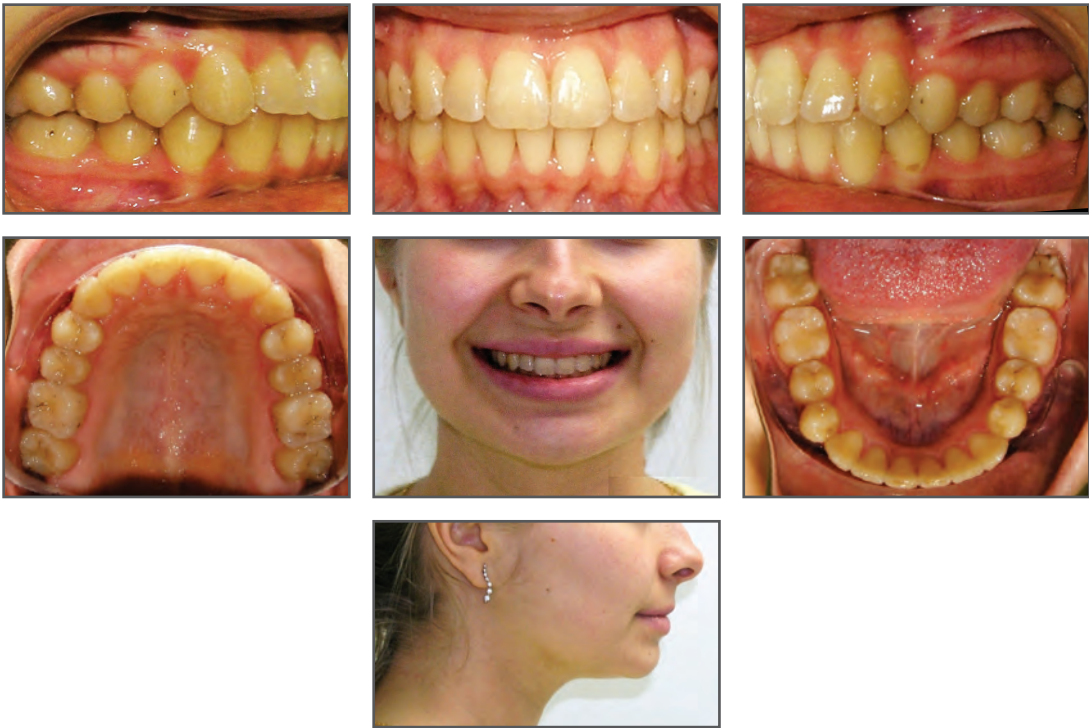OF ALIGNERS USED Upper: 44
Lower: 44

ADDITIONAL TREATMENT Class II elastics were used for 16 months, with hooks cut into the upper aligners near the cuspids, and buttons bonded to the lower second molars. To facilitate rotation of the UL3, a button was later bonded for elastics.

RETENTION Upper: Vivera®
Lower: Vivera®



BEFORE



AFTER



Dr. Ray Zoka
Zoka Orthodontics
Camarillo, CA

www.drzoka.com

TREATMENT SUMMARY

PATIENT 32-year-old male

CHIEF CONCERN The patient was concerned about his upper and lower crowding. Another doctor had recommended 4-bicuspid extraction orthodontic treatment.

DIAGNOSIS Right: Class I
Left: Class II

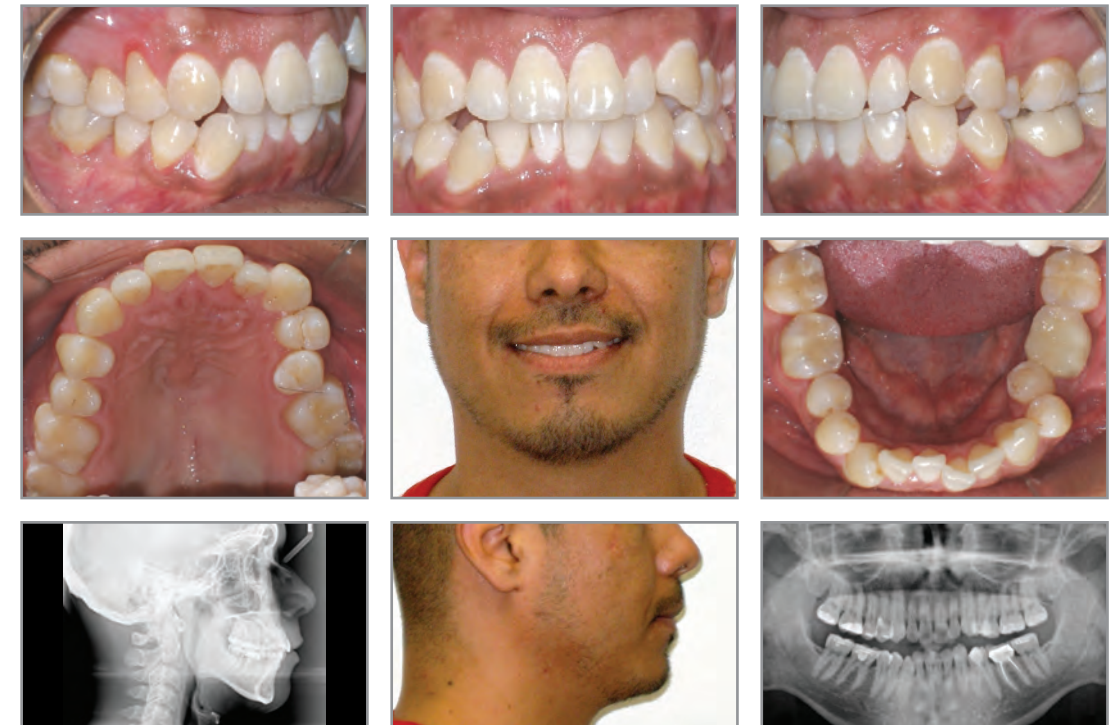Crowding and rotations in both arches. Upper and lower midline discrepancy (both dental midlines shifted to the right). Upper left second premolar is in crossbite. Gingival recession is present around all first premolars.

LENGTH OF TREATMENT 31 months

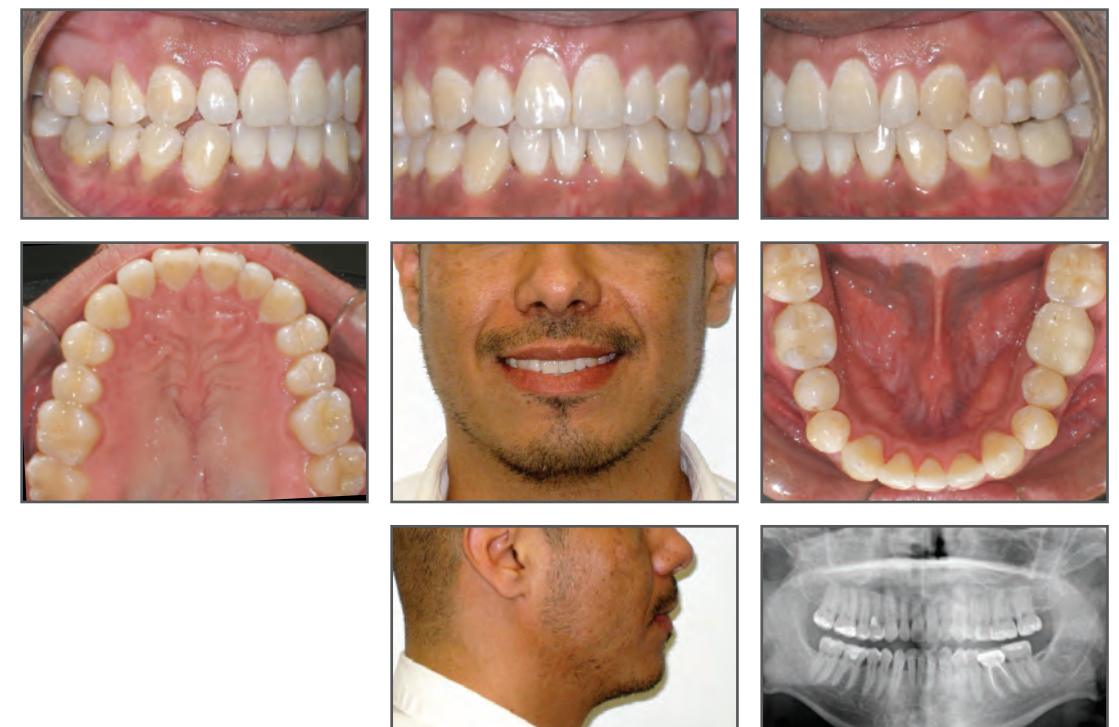
OF ALIGNERS USED Upper: 28 + 18
Lower: 37 + 18 + 8

ADDITIONAL TREATMENT Lower incisor #24 was extracted as part of his orthodontic treatment.

RETENTION Upper: Other clear
Lower: Other clear




BEFORE



AFTER

CLASS III TREATMENTS





Dr. Nahal Ashouri
Nahal Ashouri, DDS, MS
Mountain View, CA

www.DrAshouri.com

TREATMENT SUMMARY

PATIENT 56-year-old male

CHIEF CONCERN The patient did not like his crooked upper front teeth.

DIAGNOSIS
Right: Class III
Left: Class III

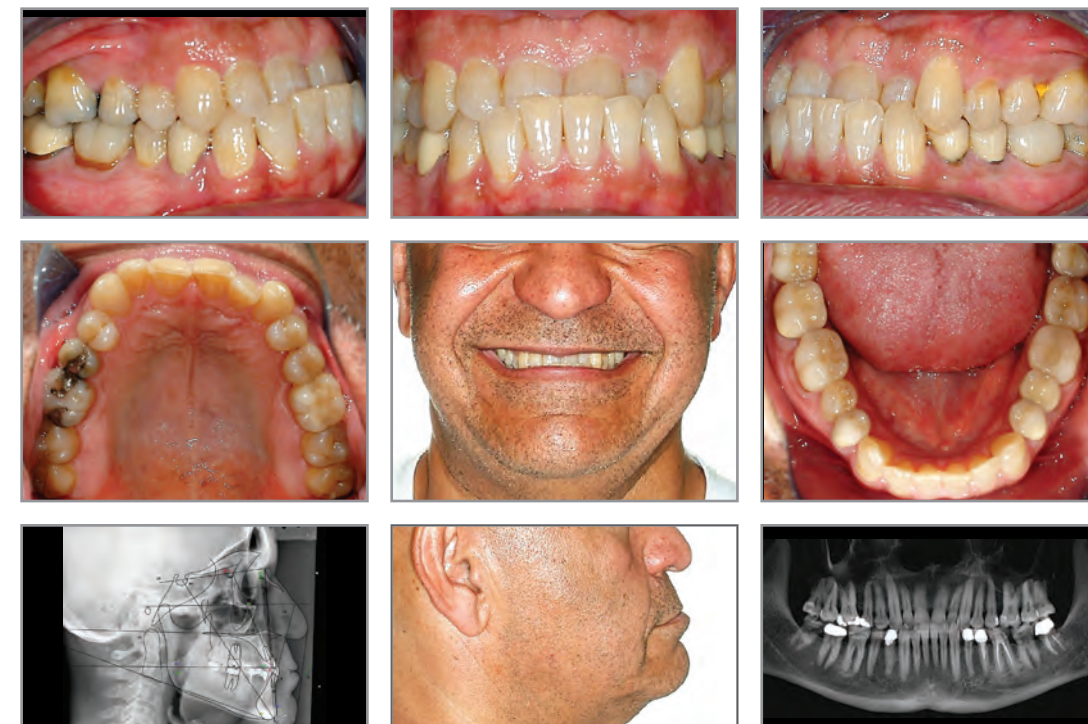Moderate upper crowding and mild lower crowding, with anterior crossbite and excessive overbite.

LENGTH OF TREATMENT 28 months

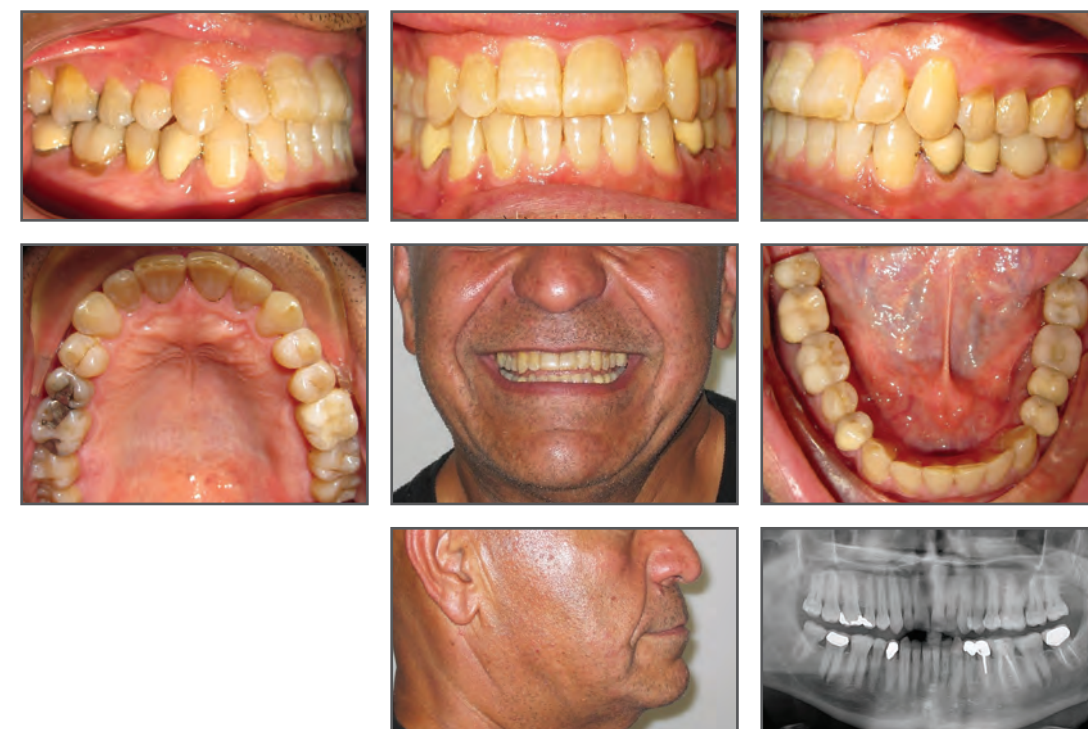OF ALIGNERS USED
Upper: 20 + 21 + 10
Lower: 20 + 21 + 10

ADDITIONAL TREATMENT Class III elastics throughout the duration of treatment, with buttons bonded to the upper first molars and hooks cut into the lower aligners near the first premolars.

RETENTION
Upper: Vivera®
Lower: Vivera®



BEFORE



AFTER



Dr. Vijay Bhagia
Space Center Orthodontics
Houston, TX

www.spacecenterortho.com

TREATMENT SUMMARY

PATIENT 18-year-old female

CHIEF CONCERN The patient was concerned about her bite.

DIAGNOSIS
Right: Class III
Left: Class III

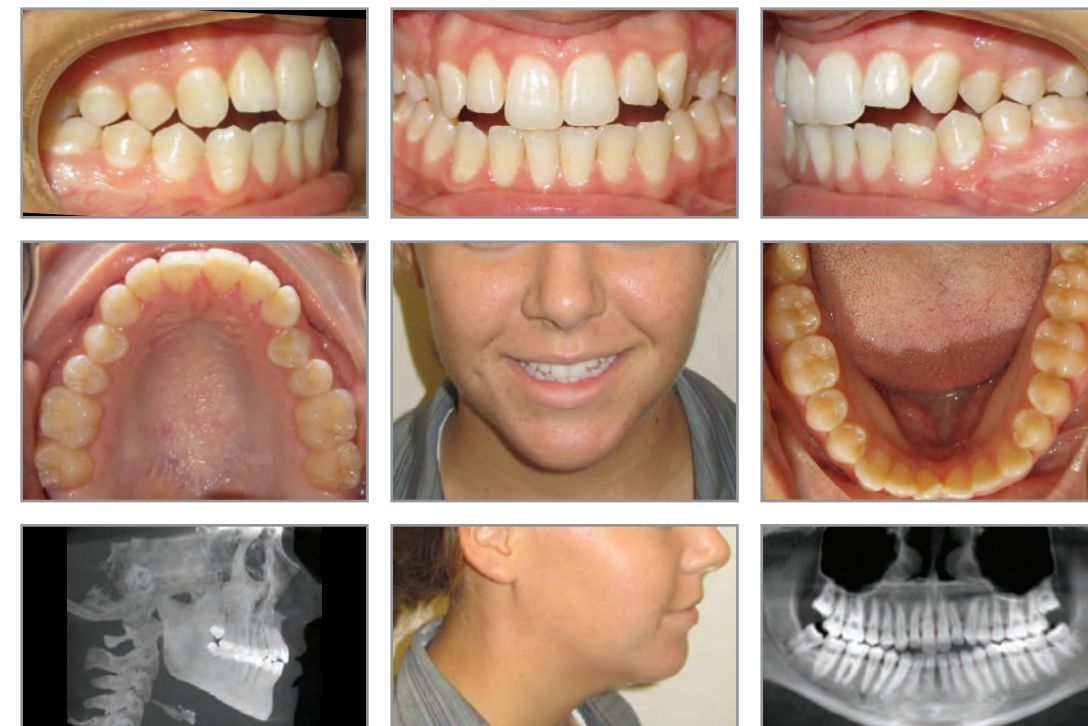Mild Class III with an anterior open bite, narrow maxilla, and bilateral posterior crossbite. Only the molars are in occlusal contact, and the temporomandibular joint clicks. Mild to moderate crowding in both arches.

LENGTH OF TREATMENT 4 months Phase I treatment + 16 months Phase II Invisalign treatment

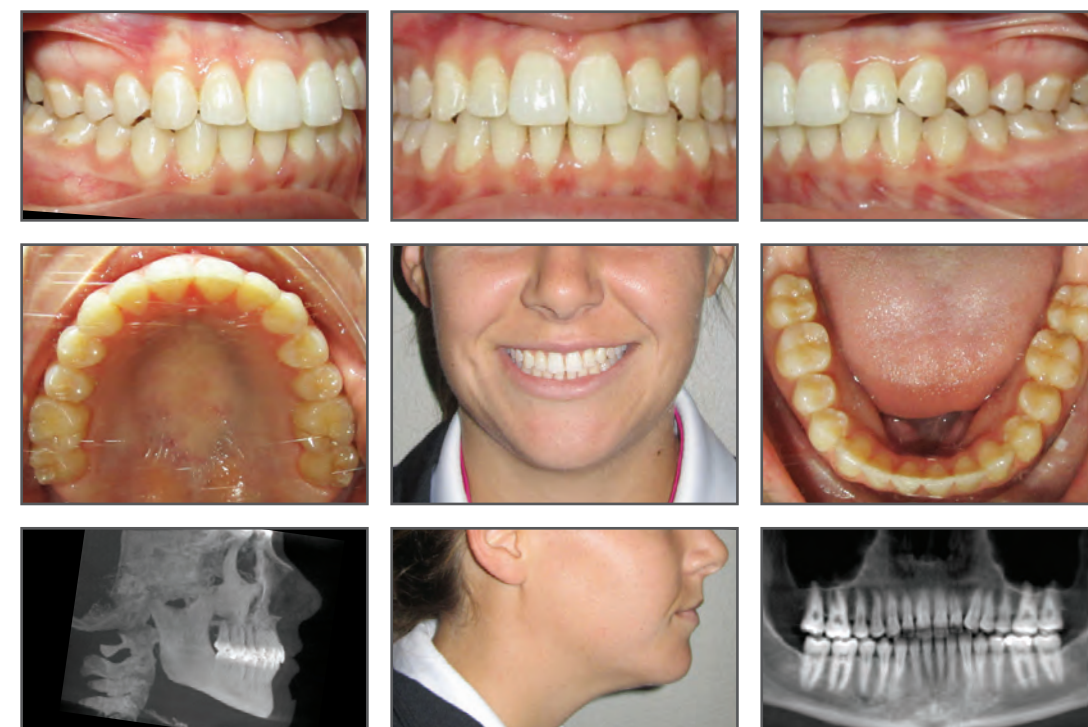
OF ALIGNERS USED
Upper: 30
Lower: 30

ADDITIONAL TREATMENT A rapid palatal expander (RPE) was used for 4 months, with one activation every four days. Triangular elastics were used for 4 months, with buttons bonded to the cuspids and lower first premolars.

RETENTION
Upper: Other clear
Lower: Other clear



BEFORE



AFTER



Dr. Gary Brigham
Brigham Orthodontics
Scottsdale, AZ

www.drgrbrigham.com

TREATMENT SUMMARY

PATIENT 17-year-old female

CHIEF CONCERN The patient did not like the appearance of her teeth. She was also concerned about the gingival health of her lower canines, having already undergone periodontal grafting around her lower centrals.

DIAGNOSIS Right: Class III
Left: Class III

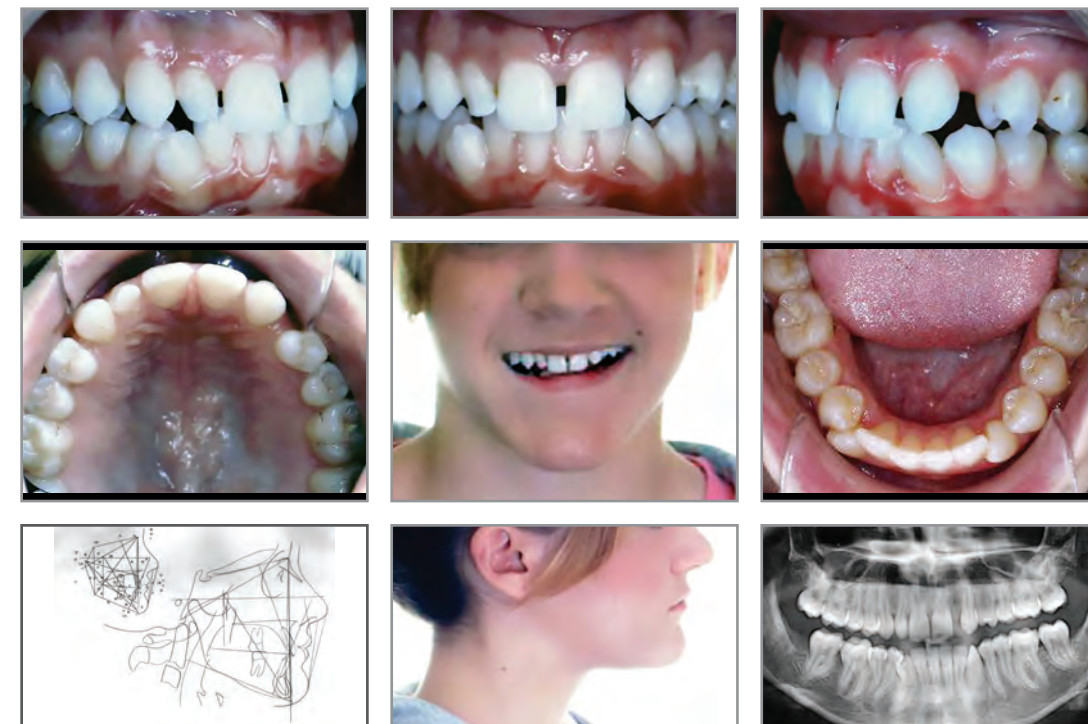
Missing upper left lateral incisor. Peg-shaped upper right lateral incisor. 1.5 mm diastema between the maxillary central incisors. 1 mm overjet and 45% overbite. Ectopic displacement of the mandibular canines with gingival recession present. Periodontal grafts present around the mandibular central incisors.

LENGTH OF TREATMENT 55 months

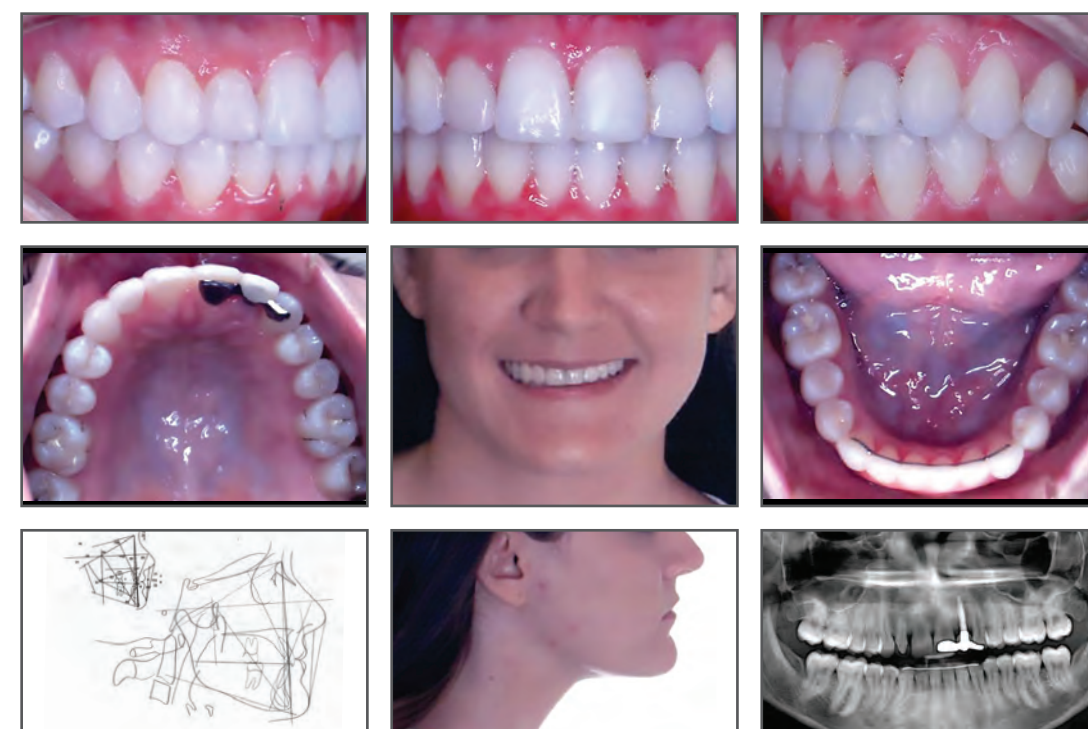
OF ALIGNERS USED Upper: 16 + 14 + 9 + 11 + 18
Lower: 16 + 14 + 16 + 11 + 18

ADDITIONAL TREATMENT Buttons were bonded to the UL3 and UL4, and an elastic chain was used to upright the root of UL3 to ensure adequate space for the UL2 implant that was placed and restored after her orthodontic treatment was completed.

RETENTION Upper: Other clear
Lower: Bonded lingual



BEFORE



AFTER



Dr. Terry Carlyle
Strathcona Orthodontics
Edmonton, AB, Canada

www.str8teeth.com

TREATMENT SUMMARY

PATIENT 20-year-old male

CHIEF CONCERN The patient wanted a second opinion regarding treatment because he was told that extractions or jaw surgery was needed "to fix my problems."

DIAGNOSIS Right: Class III
Left: Class III

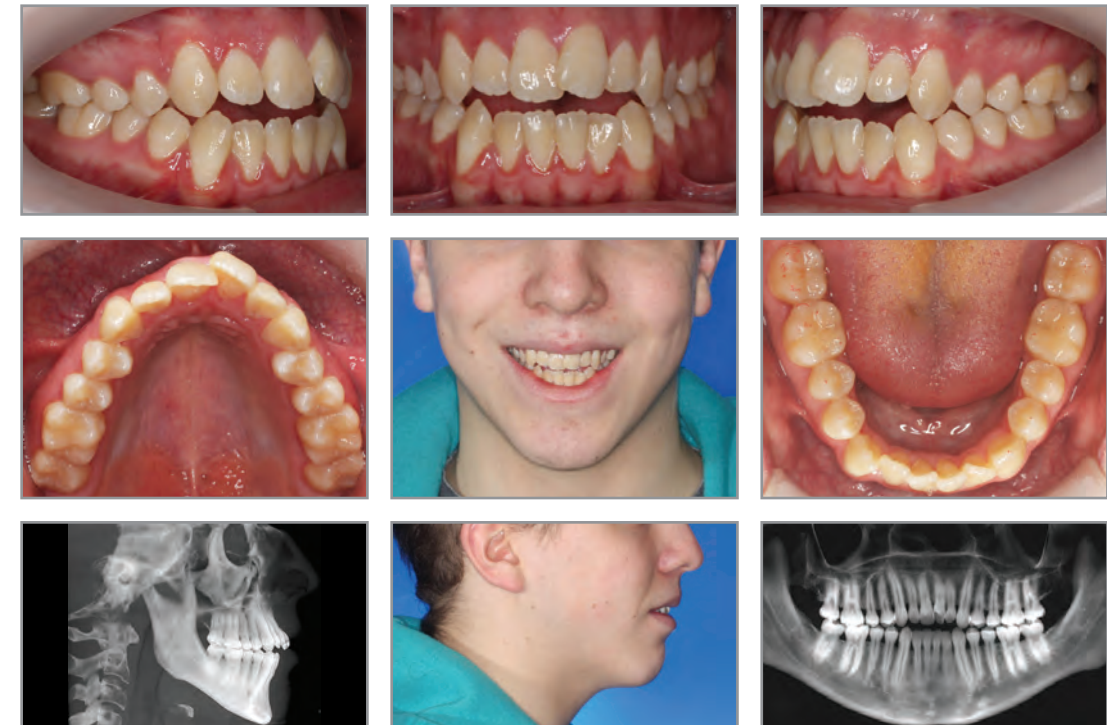
Class III tendency molar relationship. Skeletal open bite due to posterior vertical maxillary excess. Steep mandibular plane, low tongue posture, and mouth breathing. Moderate crowding of the upper and lower incisors. Narrow and tapered maxillary arch, and broad mandibular arch form.

LENGTH OF TREATMENT 28 months

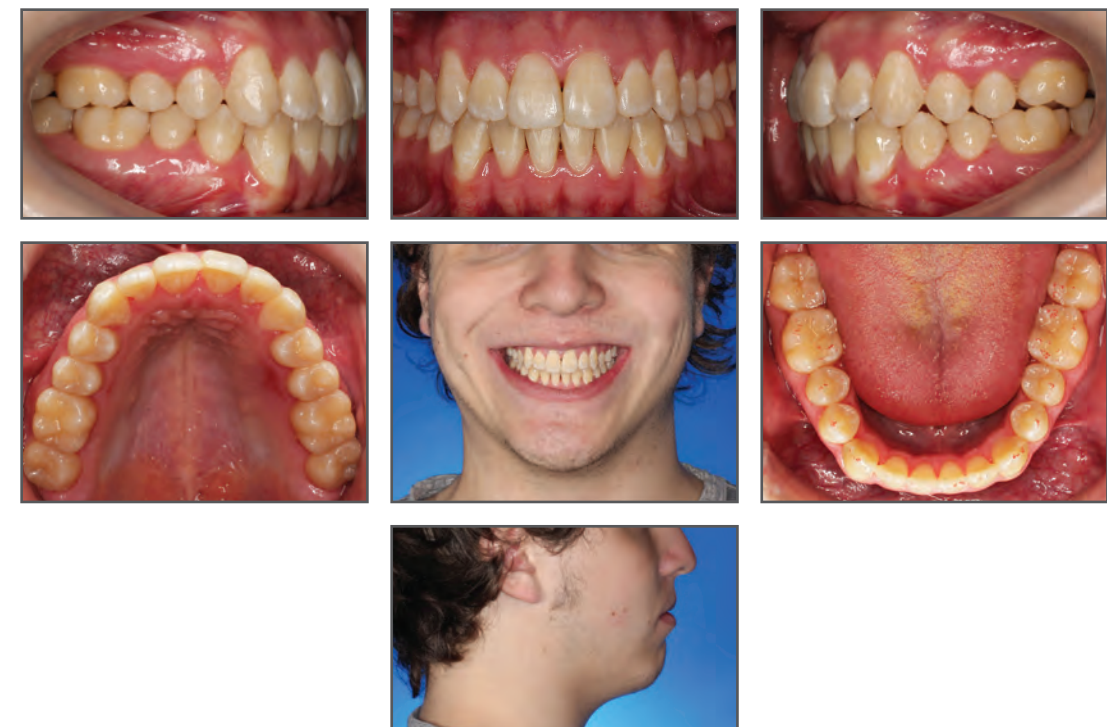
OF ALIGNERS USED Upper: 41 + 6
Lower: 41 + 6

ADDITIONAL TREATMENT Buccal/palatal TADs (4) were placed between the U5's and U6's beginning with aligner #6, with 2 oz. 3/16" sling elastics used for 3 weeks, followed by 4.5 oz. 3/16" elastics used for 19 months. Minor occlusal equilibration was done prior to refinement.

RETENTION Upper: Vivera®
Lower: Vivera®



BEFORE



AFTER



Dr. Chunni Duan
Duan Orthodontics
Seattle, WA

www.duanorthodontics.com

TREATMENT SUMMARY

PATIENT 24-year-old female

CHIEF CONCERN The patient was concerned about the alignment of her teeth and about her bite, but she wanted to avoid jaw surgery. Teeth #11, 12, and 22 appear “flattened.”

DIAGNOSIS
Right: Class III
Left: Class I

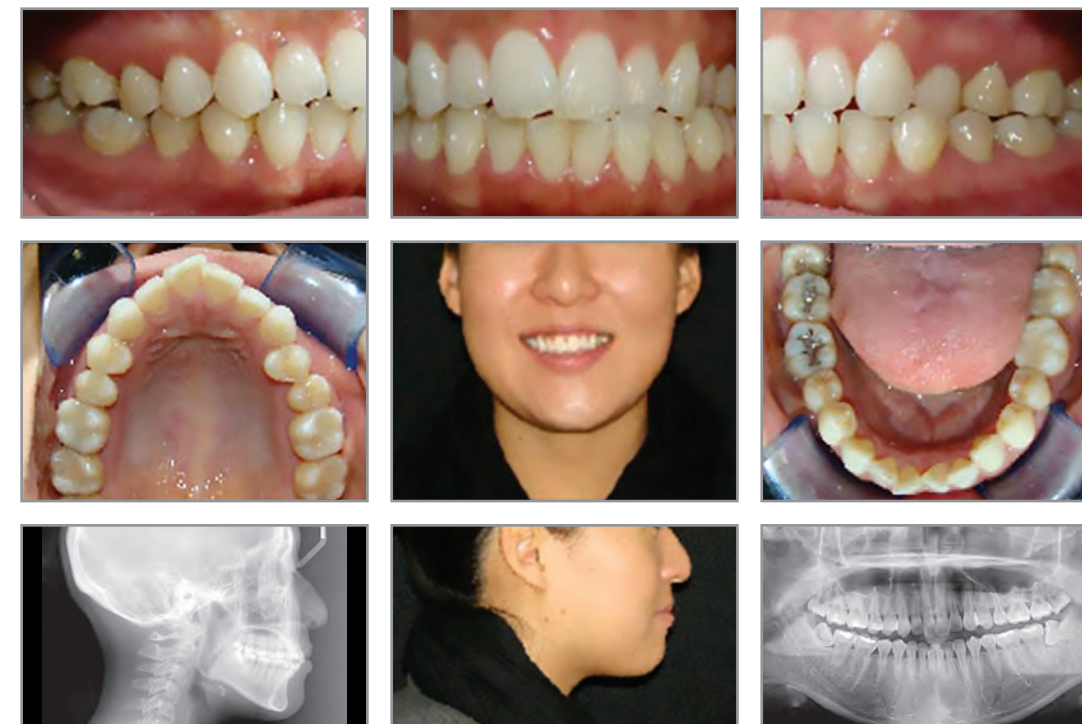Mild skeletal Class III with mandibular asymmetry and occlusal cant. Anterior open bite tendency. Lingual crossbite of #10 and #12. Moderate upper and lower crowding. The patient’s bite shifts due to the occlusal interferences from the teeth in crossbite.

LENGTH OF TREATMENT 25 months

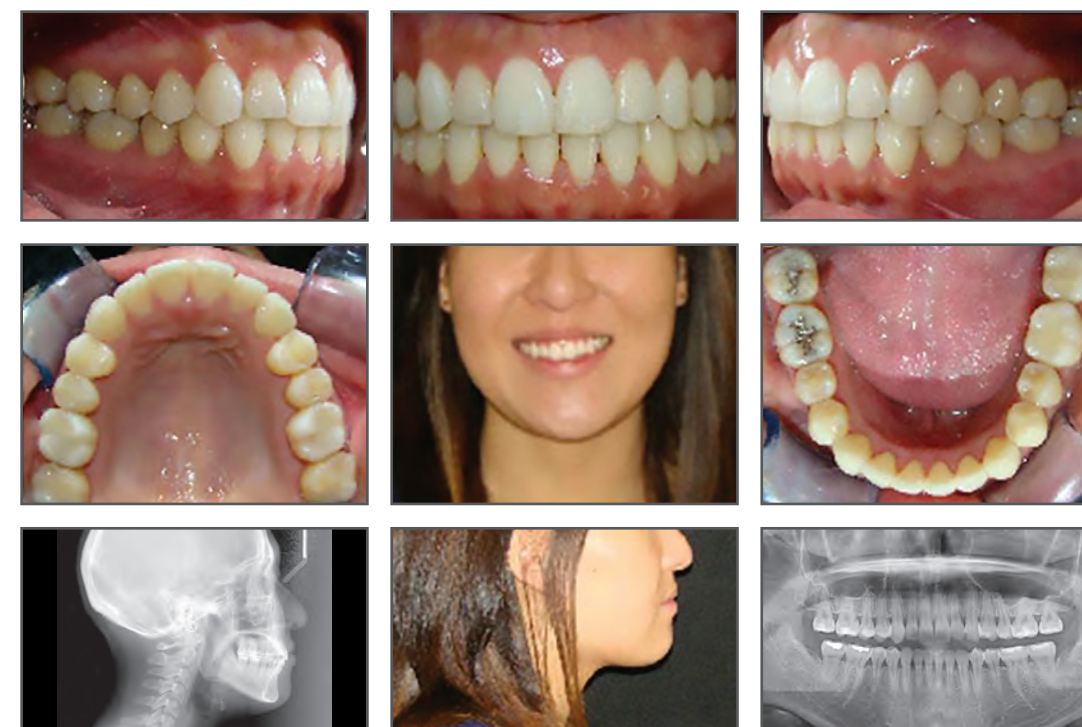OF ALIGNERS USED
Upper: 20 + 14 + 9
Lower: 20 + 19 + 9

ADDITIONAL TREATMENT Buttons were bonded to the UR and LR 6’s, with vertical elastics used for 4 months to extrude the first molars. Buttons were also bonded to the UL 4/5 (lingual) and LL 5/6 (buccal), with crossbite elastics used for 4 months.

RETENTION
Upper: Invisalign® retainer
Lower: Invisalign® retainer



BEFORE



AFTER



Dr. Donna Galante
Cater Galante Orthodontics
Rocklin, CA

www.luvmysmile.com

TREATMENT SUMMARY

PATIENT 16-year-old female

CHIEF CONCERN "My bite is changing." Previous full-braces treatment completed at another office when the patient was 13, but her lower jaw has grown more since then and is too far forward.

DIAGNOSIS Right: Class III
Left: Class III

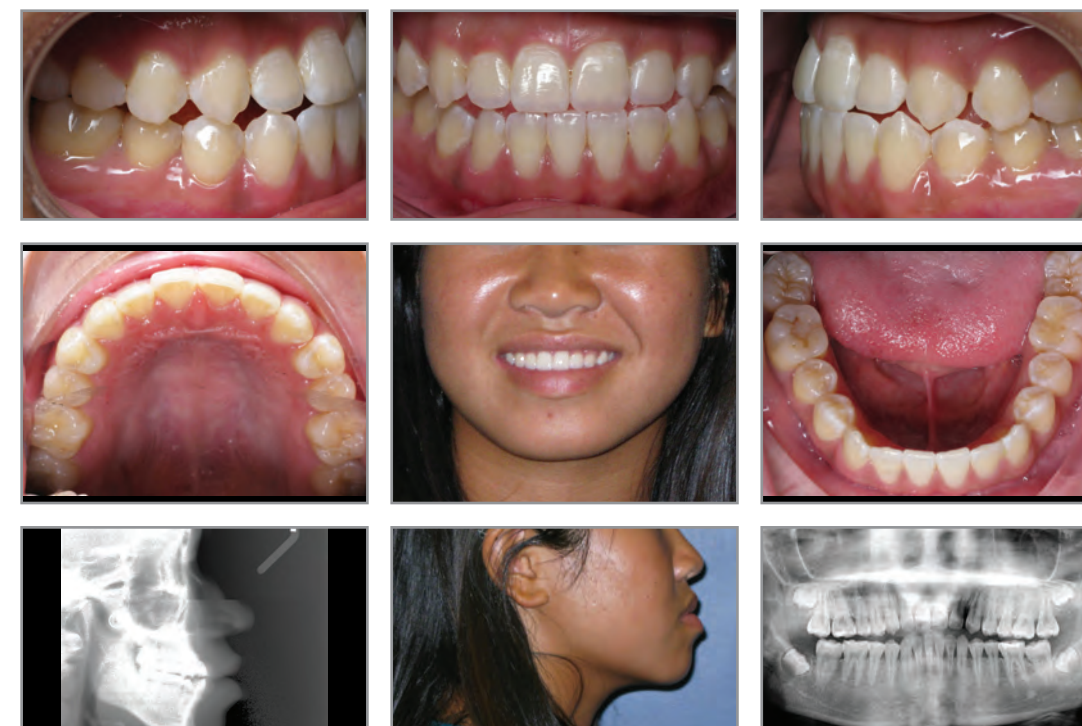Anterior open bite with an edge-to-edge incisal relationship and lower midline shifted to the left.

LENGTH OF TREATMENT 15 months

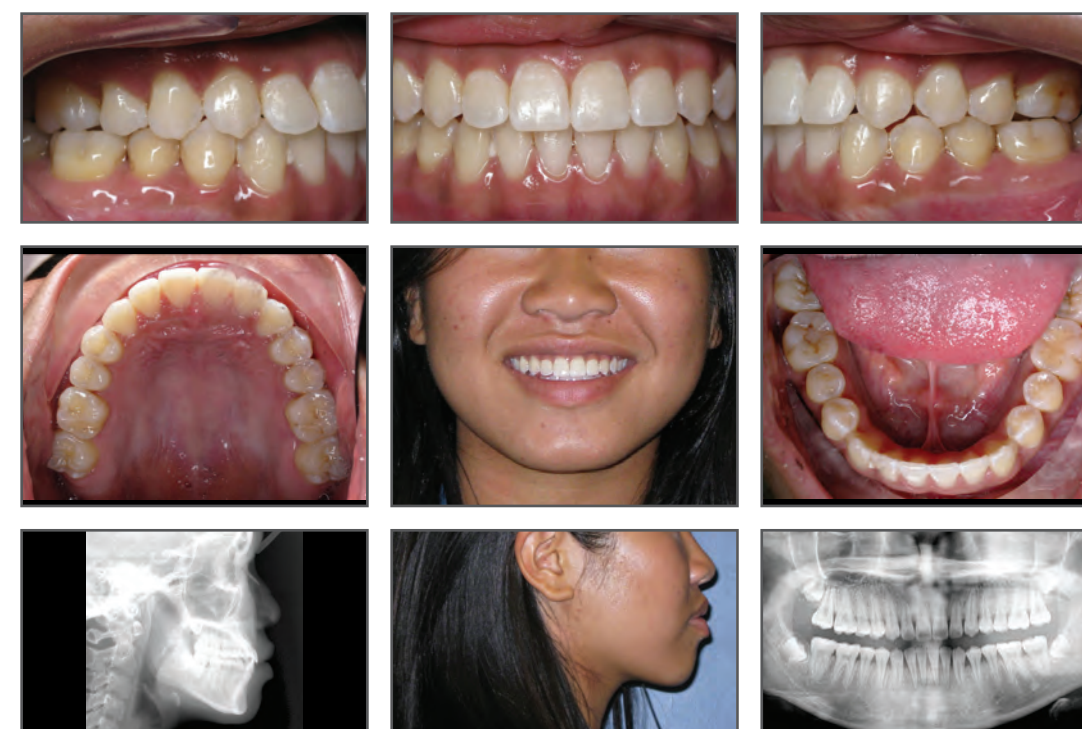
OF ALIGNERS USED Upper: 23 + 12
Lower: 23 + 12

ADDITIONAL TREATMENT Class III elastics were used for 10 months, with buttons bonded to the upper first molars and hooks cut into the lower aligners near the canines. During refinement, Class III elastics were used on the right side only for an additional 3 months.

RETENTION Upper: Other clear
Lower: Other clear



BEFORE



AFTER



Dr. Bella Shen Garnett
Bella Smile
San Francisco, CA

www.bellasmile.com

TREATMENT SUMMARY

PATIENT 12-year-old female

CHIEF CONCERN The patient was concerned about her crowded teeth.

DIAGNOSIS
Right: Class III
Left: Class I

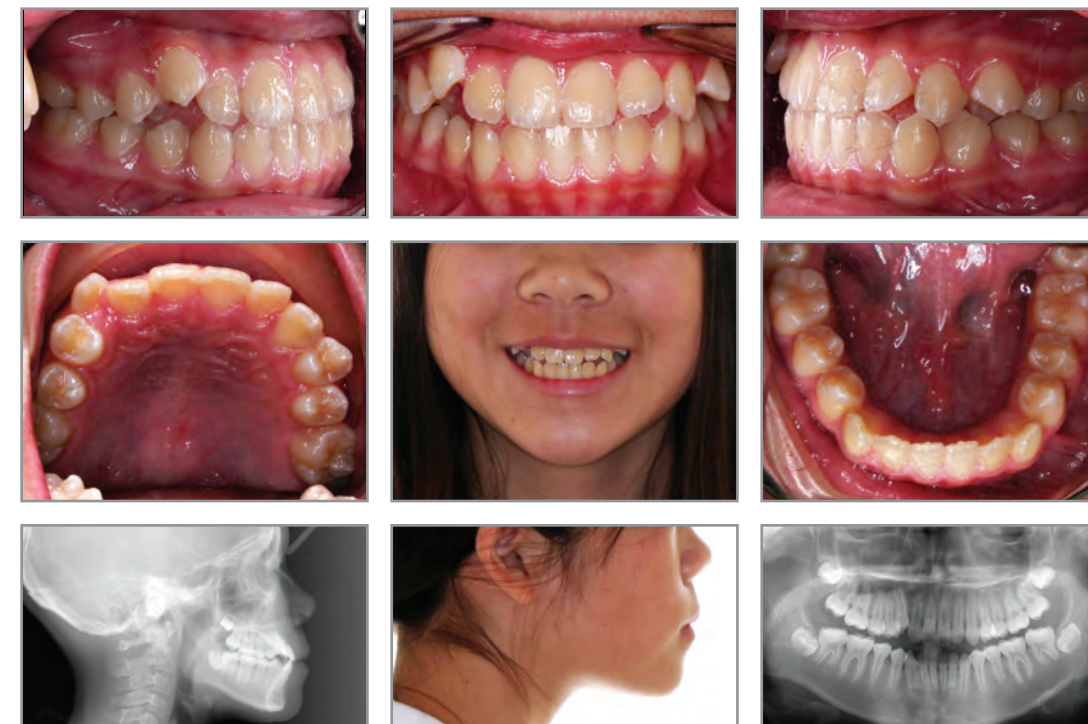Class III skeletal tendency, with a retrognathic maxilla and proclined upper incisors. Moderate upper crowding and mild lower crowding. Upper midline is shifted to the right by 1.5 mm; the lower midline is shifted to the left by 1.5 mm.

LENGTH OF TREATMENT 20 months

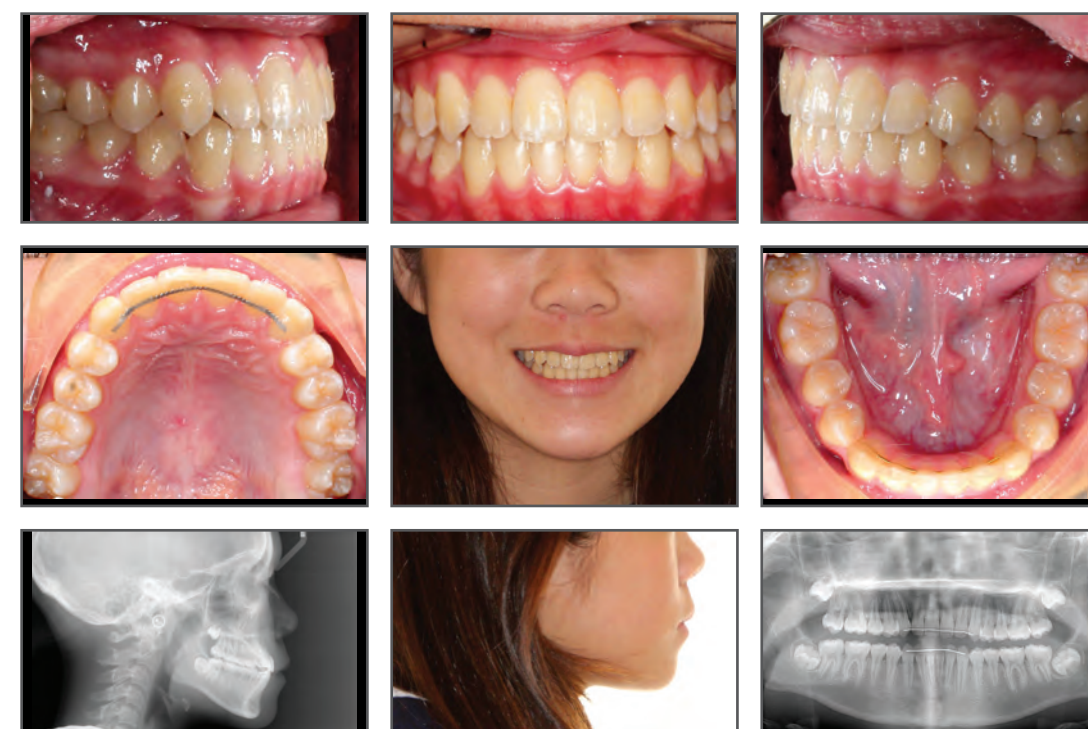
OF ALIGNERS USED
Upper: 25 + 23
Lower: 19 + 22

ADDITIONAL TREATMENT Class III elastics were used on the right side throughout the duration of treatment, with a metal button bonded to the upper first molar and a clear button bonded to the lower canine. The third molars may be extracted in the future.

RETENTION
Upper: Essix® over bonded lingual
Lower: Essix® over bonded lingual



BEFORE



AFTER



Dr. Barry Glaser
Glaser Orthodontics
Cortlandt Manor, NY

www.glaserorthodontics.com

TREATMENT SUMMARY

PATIENT 11-year-old female

CHIEF CONCERN "I have an underbite."

DIAGNOSIS
Right: Class III
Left: Class III

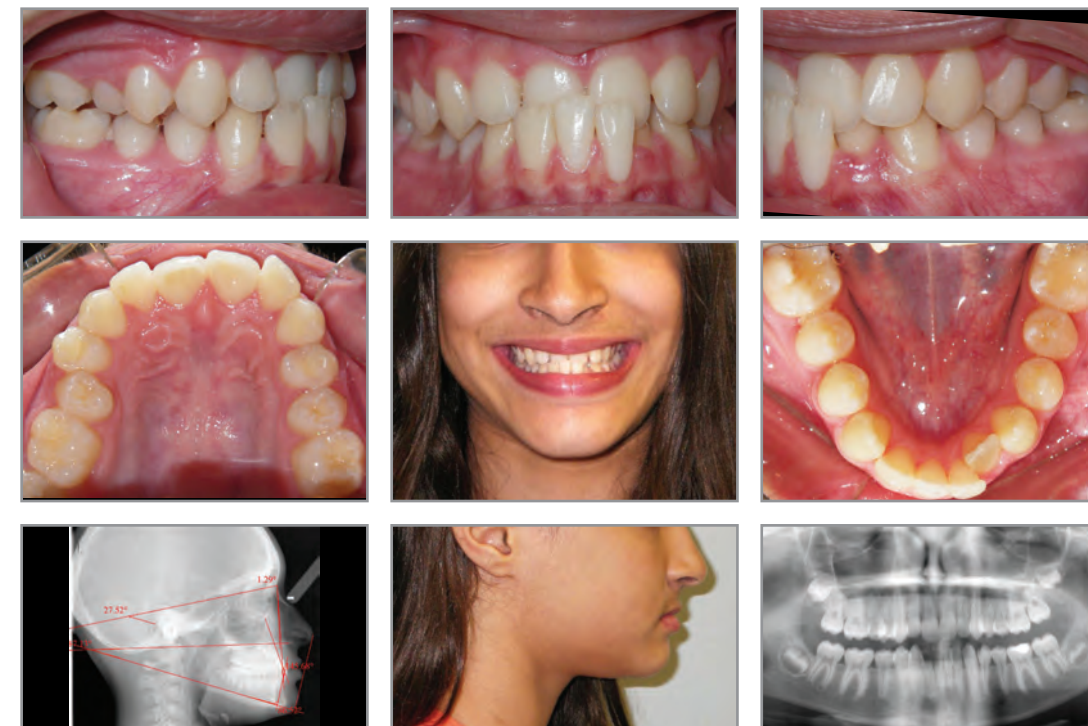
Negative overjet (anterior dental crossbite) with a deep overbite. The lower central incisors are being forced out of the arch because of the bite relationship.

LENGTH OF TREATMENT 19 months

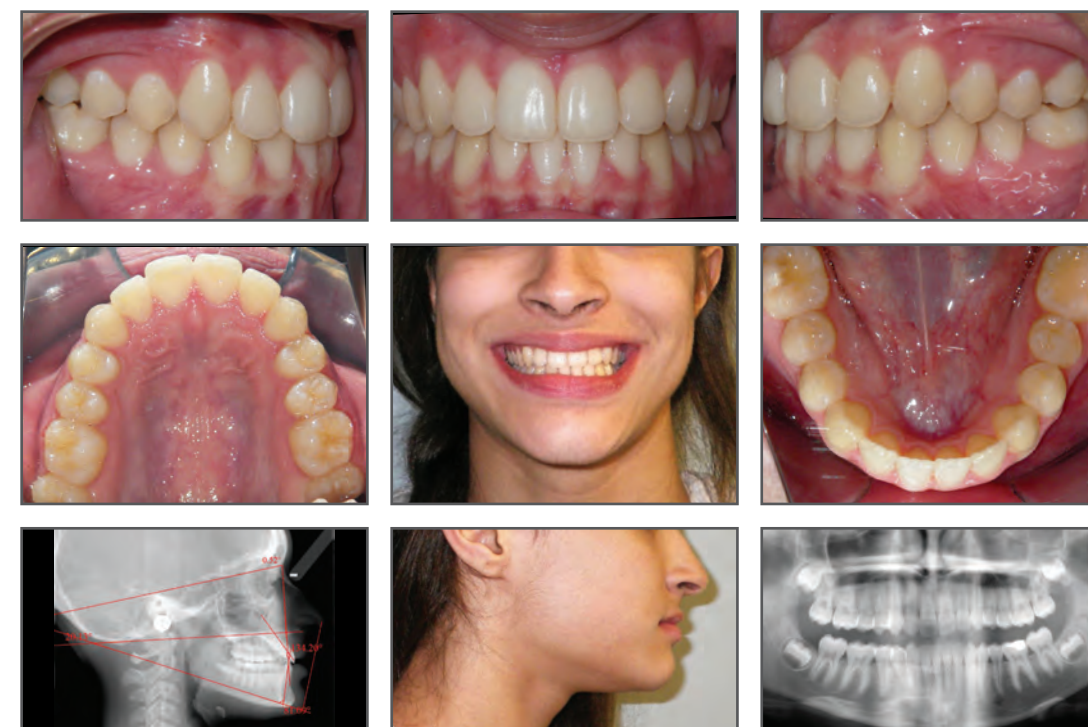OF ALIGNERS USED
Upper: 18 + 20
Lower: 18 + 20

ADDITIONAL TREATMENT None

RETENTION
Upper: Other clear
Lower: Other clear



BEFORE



AFTER



Dr. Jasmine Gorton
Gorton & Schmohl Orthodontics
Larkspur, CA

www.asmileisforever.net

TREATMENT SUMMARY

PATIENT 61-year-old female

CHIEF CONCERN The patient was referred by her general dentist because of her fractured PFM restorations.

DIAGNOSIS Right: Class III
Left: Class III

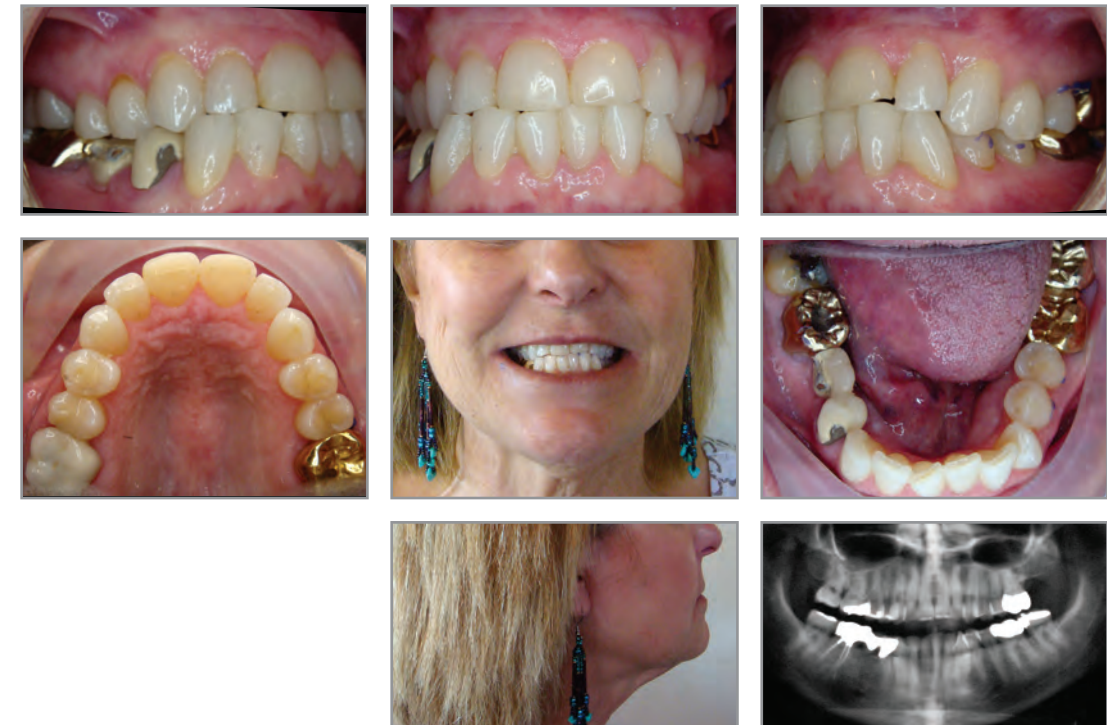Prognathic mandible with -2 mm overjet and edge-to-edge overbite. Significant wear of the incisal edges because of her bite. Anterior crossbite and right posterior crossbite. The smile arc is reversed and the upper anterior aesthetic display is suboptimal. The porcelain on the lower right bridge has fractured.

LENGTH OF TREATMENT 34 months

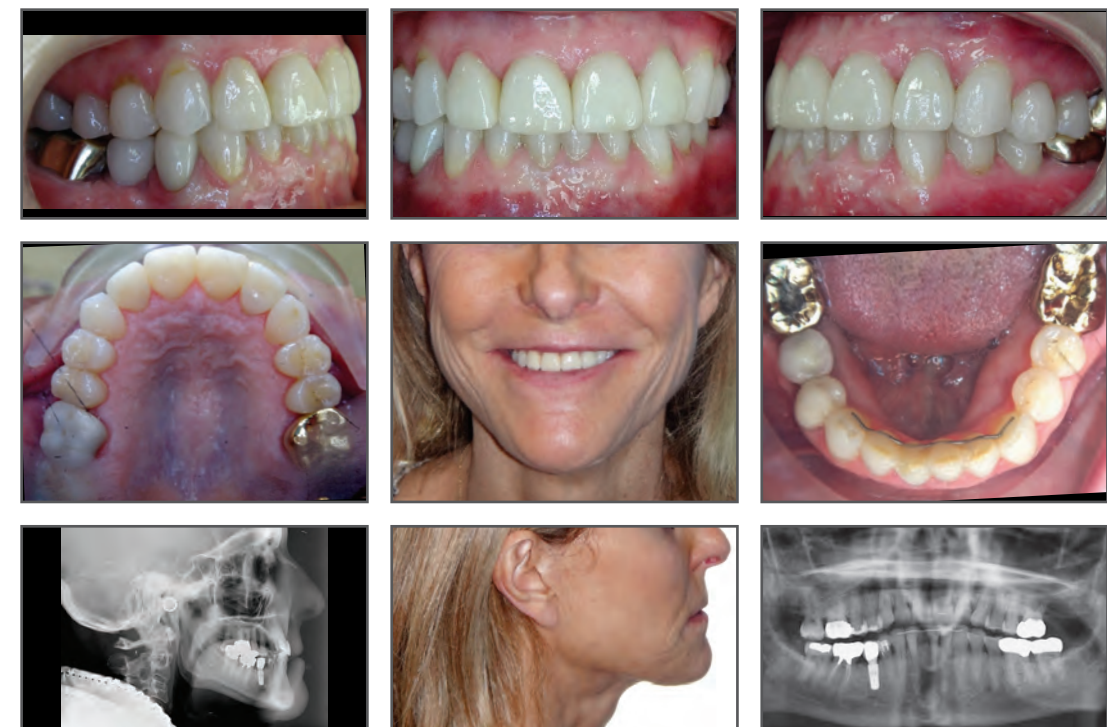OF ALIGNERS USED Upper: 29 + 20 + 10
Lower: 29 + 20 + 10

ADDITIONAL TREATMENT Class III elastics were used on the left side during the first refinement, with buttons bonded to the lower canine and upper first molar. A c-chain was used to distalize the canine and reduce the second premolar space, with buttons bonded to the lower right canine and second molar. Following orthodontic treatment, veneers, crowns, and an implant and crown for #29 were placed.

RETENTION Upper: Other clear
Lower: Bonded lingual



BEFORE



AFTER



Dr. Dudley M. Hodgkins
Hodgkins Orthodontics
Cedar Park, TX

www.10grin.com

TREATMENT SUMMARY

PATIENT 22-year-old female

CHIEF CONCERN The patient did not like her dental crowding and overjet.

DIAGNOSIS Right: Class III
Left: Class III

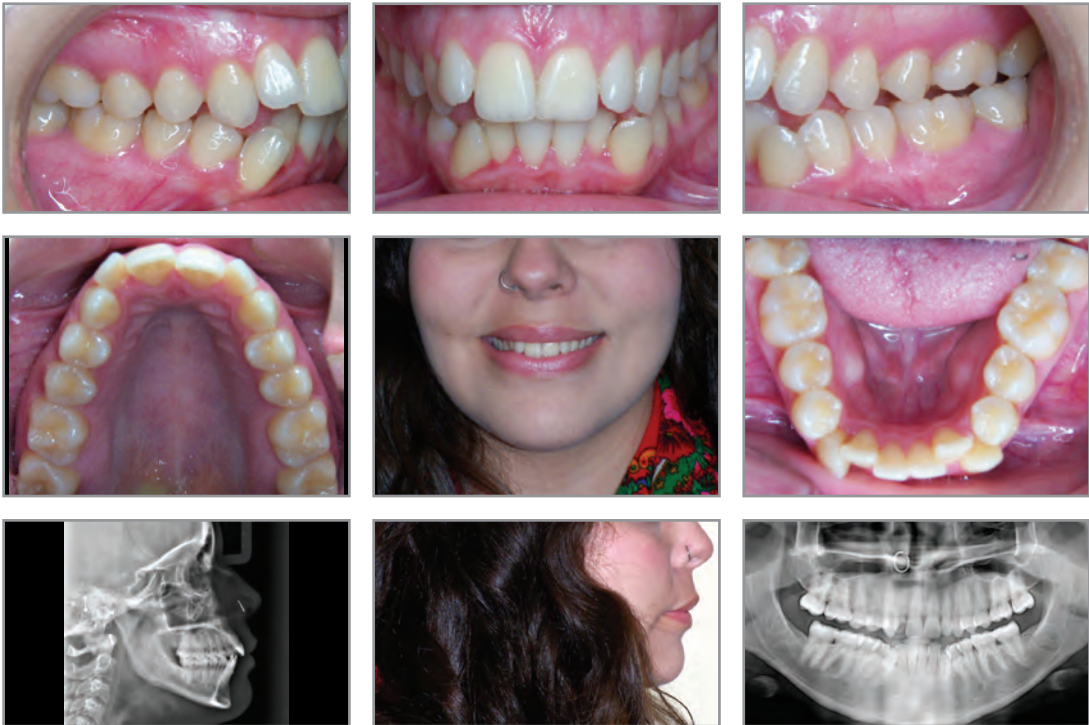
Class III dental relationship with a Class II skeletal relationship. Mesognathic facial profile. Anterior open bite and left lateral open bite. Narrow and V-shaped arches with crowding. The lower midline is shifted to the left.

LENGTH OF TREATMENT 31 months

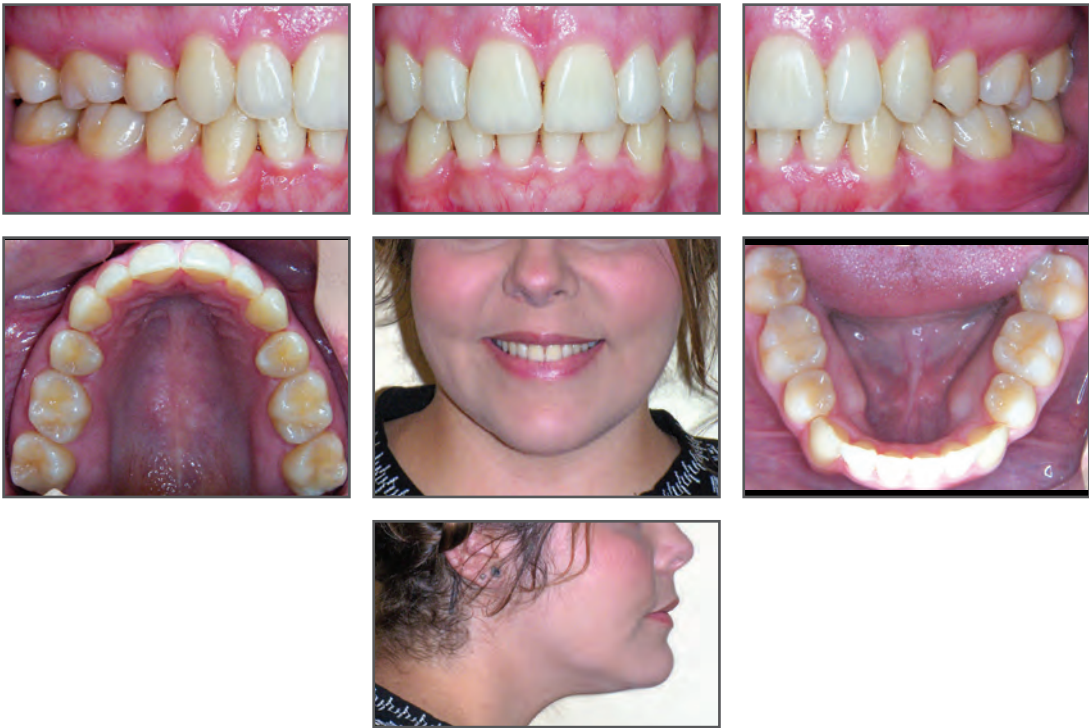OF ALIGNERS USED Upper: 34 + 20
Lower: 34 + 20

ADDITIONAL TREATMENT All four first bicuspid were extracted as part of the patient's orthodontic treatment.

RETENTION Upper: Invisalign® retainer
Lower: Invisalign® retainer



BEFORE



AFTER



Dr. Laura Low
Clear Choice Orthodontics
Omaha, NE

www.yourstraightsmile.com

TREATMENT SUMMARY

PATIENT 18-year-old male

CHIEF CONCERN The patient was referred by his general dentist for evaluation of his underbite.

DIAGNOSIS
Right: Class III
Left: Class III

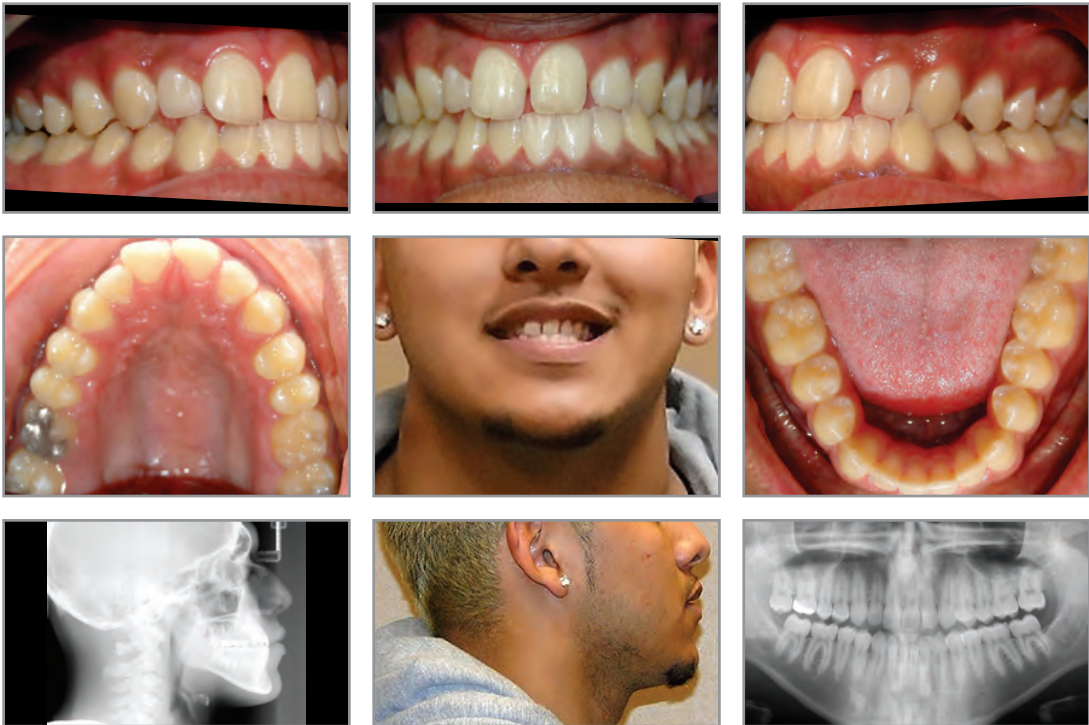Minimal overbite and overjet. The chin is deviated to the left, with the upper dental midline shifted to the right.

LENGTH OF TREATMENT 20 months

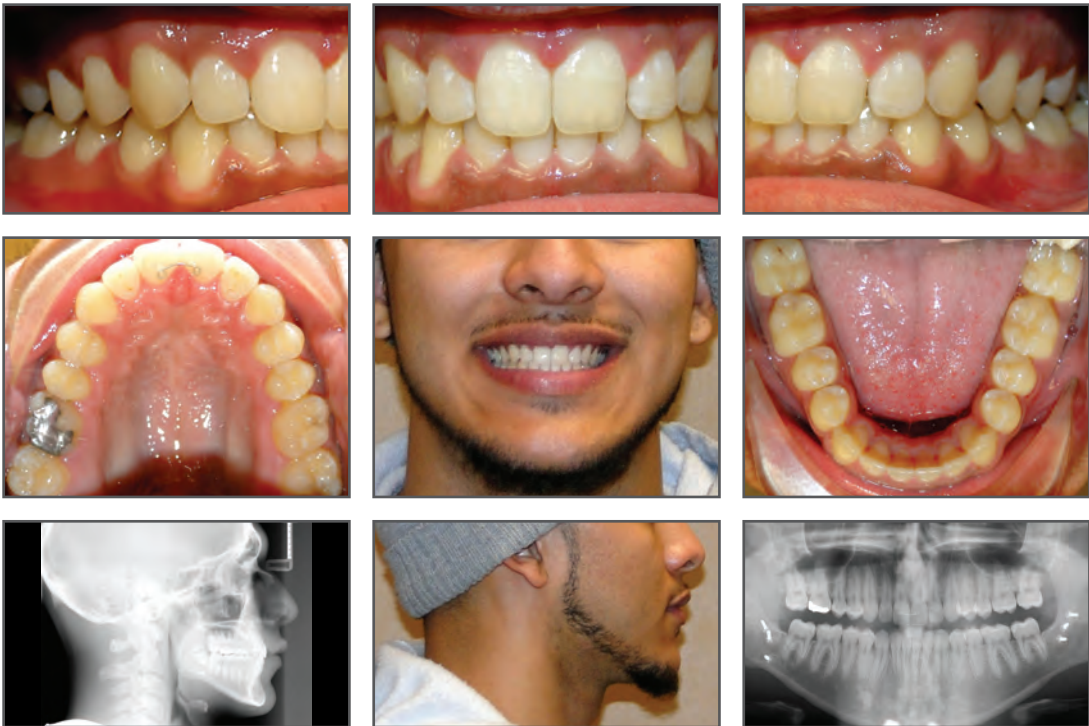
OF ALIGNERS USED
Upper: 29 + 5 + 10
Lower: 29 + 5 + 10

ADDITIONAL TREATMENT Mandibular asymmetric setback surgery, with metal buttons bonded to the 3's, 4's, and 5's per the surgeon's request. Elastics were worn for 2 months post-surgery without aligners. During the first refinement, aligners were worn for 8 hours per night without elastics. A second refinement was used for final detailing.

RETENTION
Upper: Other clear over bonded lingual
Lower: Other clear



BEFORE



AFTER



Dr. Tom Lowder
Lowder Orthodontics
Springdale, AR

www.lowderorthodontics.com

TREATMENT SUMMARY

PATIENT 28-year-old female

CHIEF CONCERN The patient was concerned about her inability to bite into food. She did not like the appearance of her teeth or her smile, and she wanted to avoid orthognathic surgery.

DIAGNOSIS Right: Class III
Left: Class III

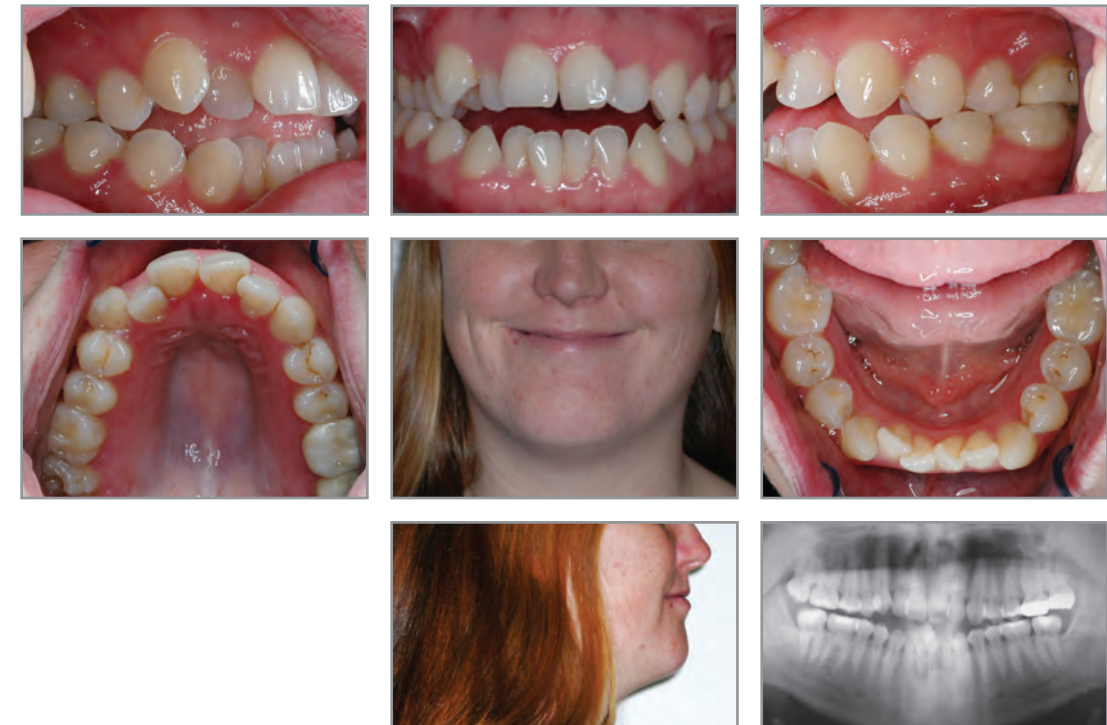Moderate to severe crowding of the upper and lower teeth, with severe anterior open bite and right buccal crossbite. Bilateral TMJ symptoms.

LENGTH OF TREATMENT 27 months

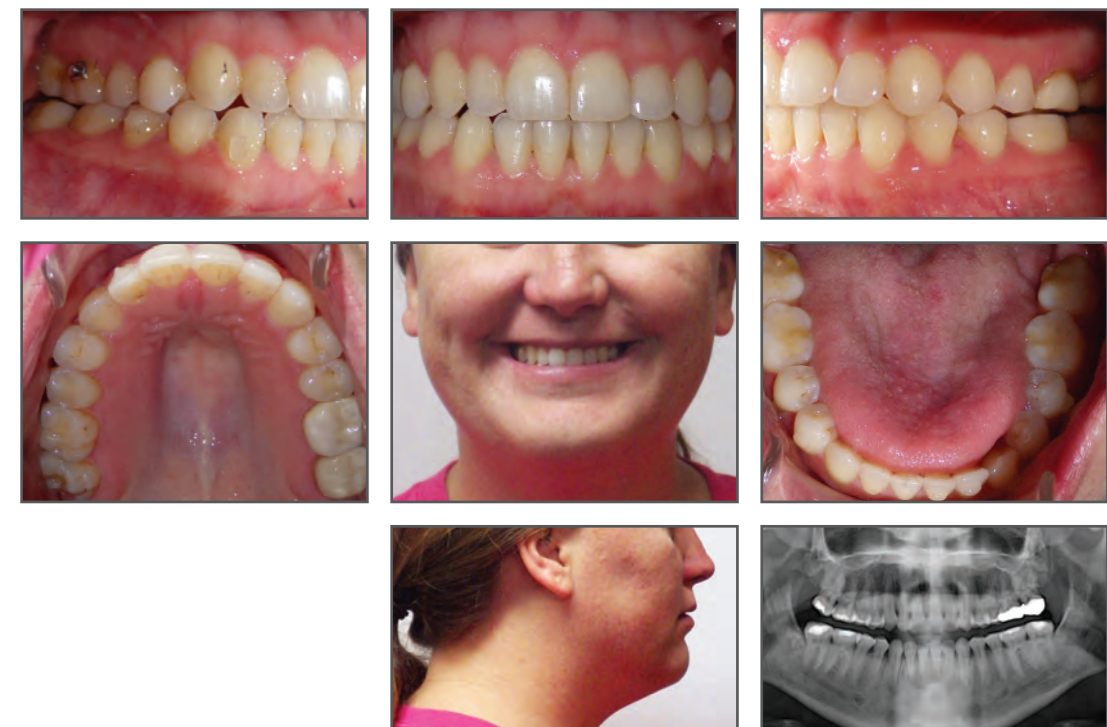OF ALIGNERS USED Upper: 26 + 23 + 9
Lower: 26 + 23 + 9

ADDITIONAL TREATMENT Elastics were used to aid the correction of the posterior crossbite and anterior open bite. Crossbite elastics with bonded buttons were used on the right side for 8 months. Class III elastics were used for 6 months on the right side and for 4 months on the left side. Triangular elastics around the upper cuspid areas were used on bonded buttons for 2 months. Occlusal molar attachments were used to help intrude the posterior buccal segments.

RETENTION Upper: Vivera®
Lower: Vivera®



BEFORE



AFTER



Dr. Luis Piedade
Ritebite Orthodontics
Cambridge, ON, Canada

www.ritebite.ca

TREATMENT SUMMARY

PATIENT 23-year-old female

CHIEF CONCERN "My bite is off." Orthognathic surgery was recommended by two other orthodontists in the past.

DIAGNOSIS
Right: Class III
Left: Class III

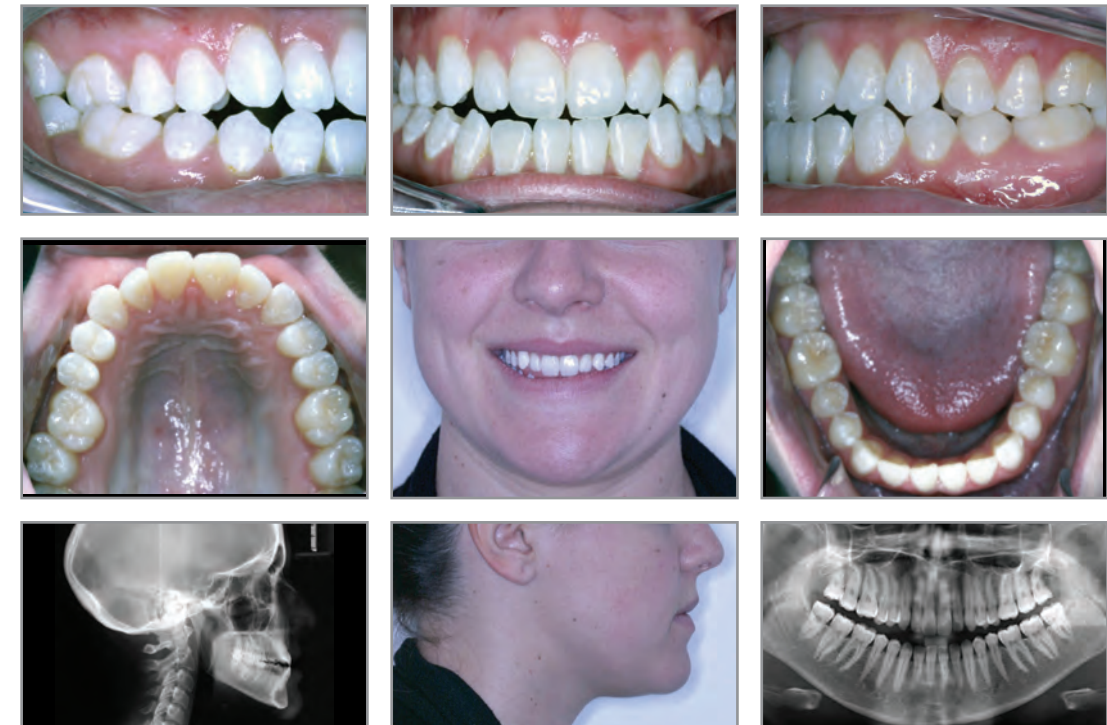
Long mandible, long lower face height, and anterior and posterior crossbites. Anterior open bite and negative overjet. Mild upper and lower crowding. Retroclined lower incisors. Dental midlines are not aligned.

LENGTH OF TREATMENT 20 months

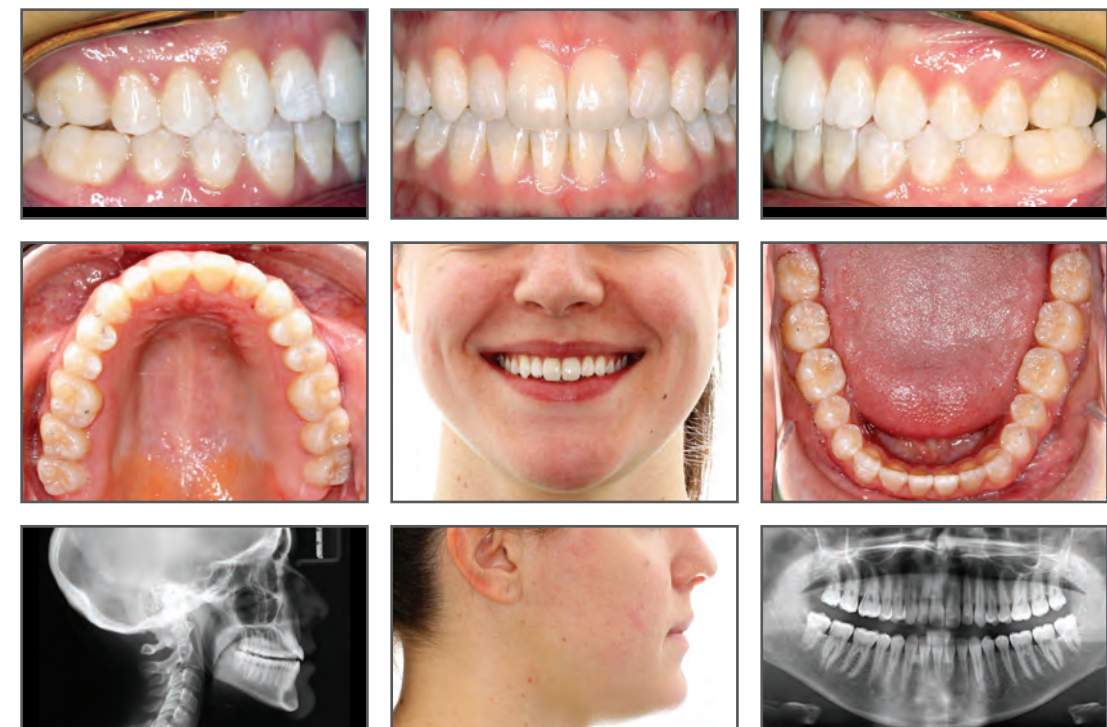OF ALIGNERS USED
Upper: 22 + 18
Lower: 22 + 18

ADDITIONAL TREATMENT Class III elastics were used for 13 months, with buttons bonded to the upper first molars and lower canines. Triangular finishing elastics were used for 6-8 weeks, with buttons bonded to UR 5/6 + LR6, UL 5/6 + LL6, and LR 4/5 + UR4.

RETENTION
Upper: Vivera®
Lower: Vivera®



BEFORE



AFTER



Dr. Kenyu Takamoto
Kenyu Takamoto, DDS, MSD
Bellevue, WA

www.drtakamoto.com



TREATMENT SUMMARY

PATIENT 19-year-old male

CHIEF CONCERN The patient cannot chew on his front teeth and also has aesthetic concerns.

DIAGNOSIS
Right: Class III
Left: Class III

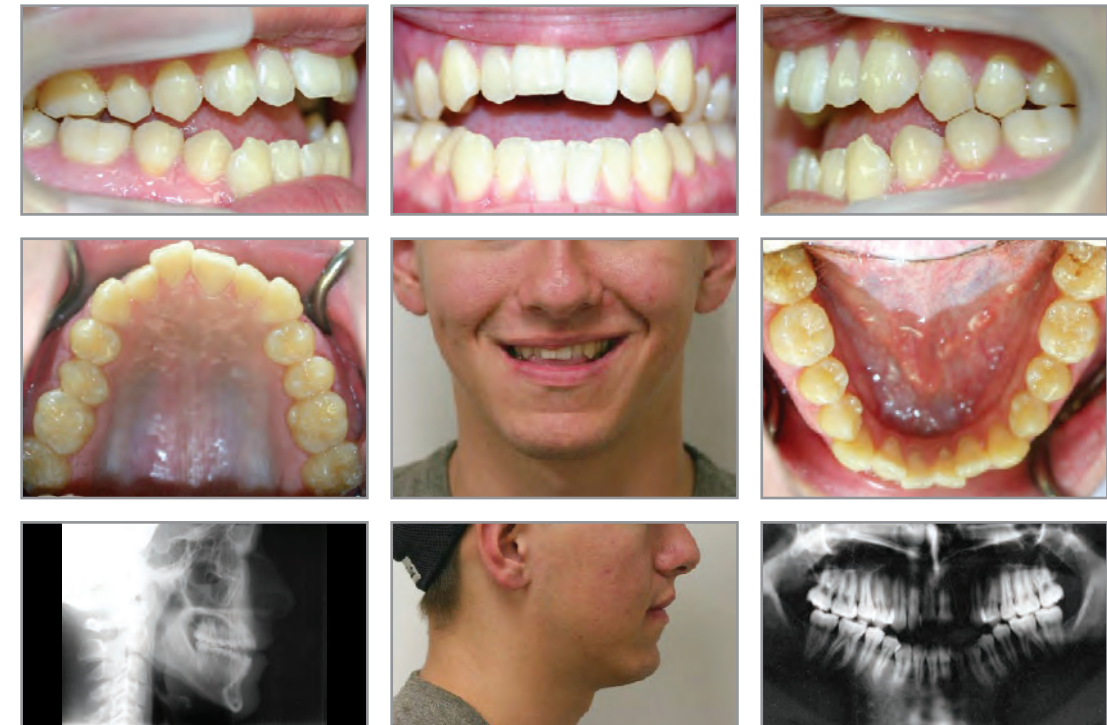Severe anterior open bite (8 mm) with bilateral Class III molar relationship. Narrow maxillary arch, with the bicuspid areas in crossbite. Tongue thrust and bruxism habit. Obstructive sleep apnea.

LENGTH OF TREATMENT 17 months

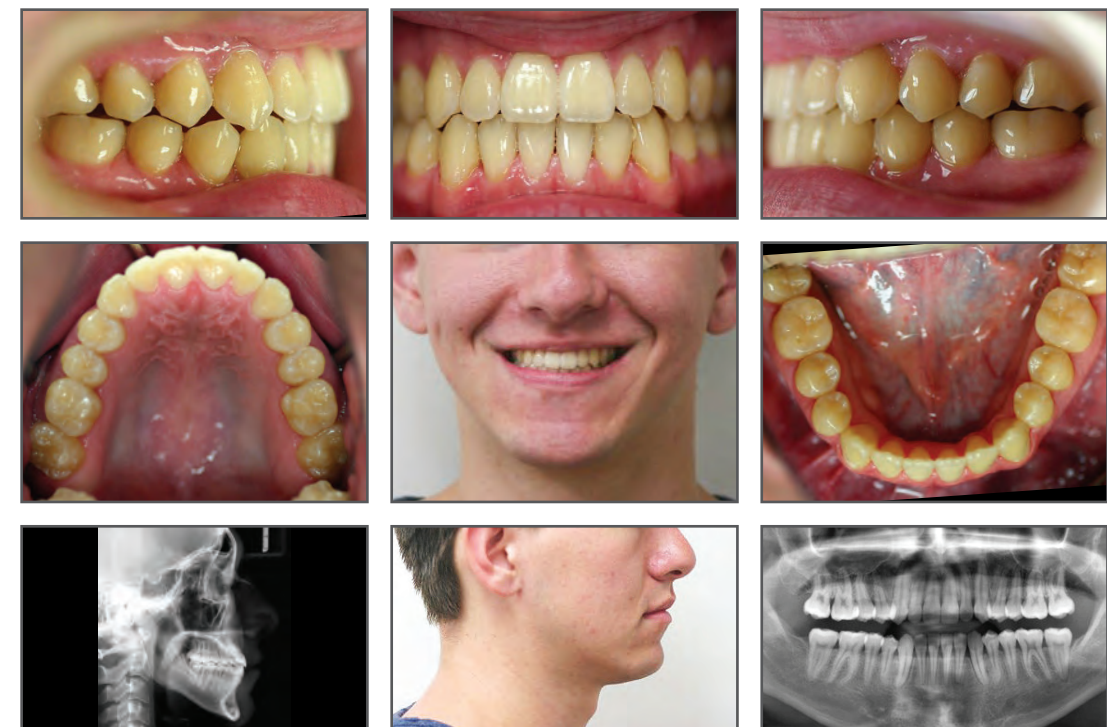
OF ALIGNERS USED
Upper: 17 + 32
Lower: 17 + 32

ADDITIONAL TREATMENT Class III elastics were used, with buttons bonded to the U6's and L3's. A clear Essix® overlay appliance was worn over the aligners for 22 hrs/day throughout the duration of treatment (4 overlays total). An AcceleDent® device was used 20 min/day and the aligners changed every week beginning at stage #7. Orthognathic surgery was originally planned, but not needed in the end.

RETENTION
Upper: Vivera® (full time) + Essix® overlay (at night) for 6 months, then Vivera® (12 hours) + overlay (at night)
Lower: Vivera® (full time) + Essix® overlay (at night) for 6 months, then Vivera® (12 hours) + overlay (at night)



BEFORE



AFTER

ALPHABETICAL INDEX

TREATING DOCTOR

Dr. Nahal Ashouri.....56, 148

Dr. Patricia Bendick 58

Dr. Bartley Benson..... 60

Dr. Vijay Bhagia..... 150

Dr. Sujata Bhatia..... 62, 64

Dr. Gary Brigham 2, 152

Dr. Charles Brodsky4, 66

Dr. Terry Carlyle 154

Dr. Joseph Ciccio..... 68

Dr. Dustin Coles..... 70, 72

Dr. Linda Crawford 74, 76

Dr. Doug Crosby.....6

Dr. James Crouse.....8, 78

Dr. Chunni Duan80, 156

Dr. Tarek El-Bialy 82

Dr. Robert Elliott..... 84

Dr. Donna Galante.....86, 158

Dr. Jose Luis Garcia..... 88

Dr. Mark Garlington 10

Dr. Bella Shen Garnett..... 90, 92, 160

Drs. Stanley and Scott Gersch..... 12

Dr. Barry Glaser.....94, 96, 162

Dr. Ira Goldberg..... 98

Dr. Jasmine Gorton 100, 164

Dr. William Grieve 14

Dr. William Heintz 16, 18

Dr. Dudley M. Hodgkins 166

Dr. Sean Holliday..... 20, 102, 104

Dr. Lindsay Jackfert..... 22

Dr. Paul Kasrovi..... 24

Dr. Kraig Kottemann 106

Dr. Edwin Lee 108

Dr. Laura Low 168

Dr. Tom Lowder 170

Dr. Mark Lowe 110

Dr. Steven Luccarelli 26

Dr. Ramtin Nassiri 112

Dr. Michelle Fogg Neal.....28, 114

Dr. Jonathan Nicozisis 30, 32

Dr. Bradley Nirenblatt..... 34, 116, 118

Drs. Robert and James Passamano 36, 120, 122

Dr. Luis Piedade..... 38, 124, 172

Dr. Gregory Ross 126

Dr. Vishal Sharma 128

Dr. Kurt Silberstein40, 42, 130

Dr. Manuel Sousa..... 44

Dr. John Sparaga..... 46, 48, 132, 134

Dr. Sandra Tai.....136

Dr. Kenyu Takamoto..... 174

Dr. Jason Tam 50

Dr. Samie Thabet.....52, 138

Dr. Maureen Valley 140

Dr. Jenny Zhu 142

Dr. Ray Zoka..... 144

TEEN TREATMENT INDEX

TREATING DOCTOR

Dr. Patricia Bendick 58

Dr. Bartley Benson..... 60

Dr. Vijay Bhagia..... 150

Dr. Gary Brigham 2, 152

Dr. Joseph Ciccio..... 68

Dr. Dustin Coles..... 72

Dr. Linda Crawford 74

Dr. James Crouse.....8, 78

Dr. Chunni Duan 80

Dr. Tarek El-Bialy 82

Dr. Donna Galante.....86, 158

Dr. Jose Luis Garcia..... 88

Dr. Bella Shen Garnett..... 160

Dr. Barry Glaser94, 96, 162

Dr. Jasmine Gorton 100

Dr. William Grieve 14

Dr. William Heintz 18

Dr. Sean Holliday..... 20, 102, 104

Dr. Edwin Lee 108

Dr. Laura Low 168

Dr. Mark Lowe 110

Dr. Steven Luccarelli 26

Dr. Michelle Fogg Neal.....28, 114

Dr. Jonathan Nicozisis 32

Drs. Robert and James Passamano 120, 122

Dr. Luis Piedade..... 124

Dr. Gregory Ross 126

Dr. Kurt Silberstein40, 130

Dr. John Sparaga.....46, 48, 132

Dr. Sandra Tai.....136

Dr. Kenyu Takamoto..... 174

Dr. Jason Tam 50

Dr. Samie Thabet..... 138

Dr. Maureen Valley 140

TREATMENT PLAN INDEX

ACCELERATED ORTHODONTIC TREATMENT

Dr. Bella Shen Garnett 90
Dr. Kenyu Takamoto..... 174

ALIGNER TRAY SEATER

Dr. Maureen Valley 140

ARCH EXPANDERS

Dr. Vijay Bhagia..... 150
Dr. Chunni Duan 80
Dr. Kurt Silberstein 130

BITE RAMPS

Dr. Lindsay Jackfert 22
Dr. Tom Lowder 170
Dr. John Sparaga..... 132

CLASS II CORRECTION APPLIANCES

Dr. Bartley Benson..... 60
Dr. Jasmine Gorton 100
Dr. Michelle Fogg Neal..... 114
Dr. John Sparaga..... 132

ELASTICS

Dr. Nahal Ashouri..... 56, 148
Dr. Patricia Bendick 58
Dr. Vijay Bhagia..... 150
Dr. Gary Brigham 2, 152

ELASTICS CONTINUED

Dr. Terry Carlyle 154
Dr. Joseph Ciccio..... 68
Dr. Dustin Coles 70, 72
Dr. Linda Crawford 74, 76
Dr. James Crouse..... 78
Dr. Chunni Duan 80, 156
Dr. Tarek El-Bialy 82
Dr. Robert Elliott..... 84
Dr. Donna Galante..... 86, 158
Dr. Jose Luis Garcia..... 88
Dr. Bella Shen Garnett..... 90, 92, 160
Drs. Stanley and Scott Gersch 12
Dr. Barry Glaser..... 94, 96
Dr. Ira Goldberg..... 98
Dr. Jasmine Gorton 100, 164
Dr. William Heintz 16, 18
Dr. Sean Holliday..... 20, 102, 104
Dr. Paul Kasrovi..... 24
Dr. Kraig Kottemann 106
Dr. Laura Low 168
Dr. Tom Lowder 170
Dr. Mark Lowe 110
Dr. Ramtin Nassiri 112
Dr. Michelle Fogg Neal..... 28, 114
Dr. Bradley Nirenblatt..... 118
Drs. Robert and James Passamano 120, 122
Dr. Luis Piedade 38, 124, 172
Dr. Gregory Ross 126
Dr. Vishal Sharma 128
Dr. Kurt Silberstein 130
Dr. John Sparaga..... 46, 48, 132, 134
Dr. Sandra Tai..... 136
Dr. Kenyu Takamoto..... 174
Dr. Samie Thabet..... 138
Dr. Maureen Valley 140
Dr. Jenny Zhu 142

TREATMENT PLAN INDEX

EXTRACTIONS

Dr. Charles Brodsky 66
Dr. Dustin Coles 70
Dr. Linda Crawford 74
Dr. William Grieve 14
Dr. Dudley M. Hodgkins 166
Dr. Lindsay Jackfert 22
Dr. Kraig Kottemann 106
Dr. Edwin Lee 108
Dr. Ramtin Nassiri 112
Dr. Jonathan Nicozisis 32
Dr. Ray Zoka 144

GINGIVAL GRAFTING

Dr. John Sparaga..... 46, 48

ORTHOGNATHIC SURGERY

Dr. Robert Elliott..... 84
Dr. Kraig Kottemann 106
Dr. Laura Low 168

OVERLAY APPLIANCE

Dr. Kenyu Takamoto..... 174

PONTIC RETAINER (TEMPORARY RESTORATION)

Dr. Sean Holliday..... 20

RESTORATIVE TREATMENT

Dr. Gary Brigham 152
Dr. Linda Crawford 76
Dr. Jasmine Gorton 164
Dr. Bradley Nirenblatt..... 34

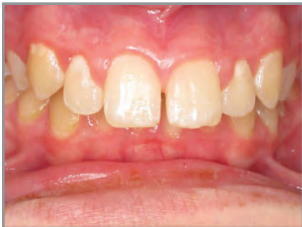SECTIONAL BRACES

Dr. Paul Kasrovi..... 24
Dr. Kraig Kottemann 106
Dr. Edwin Lee 108
Dr. John Sparaga..... 132

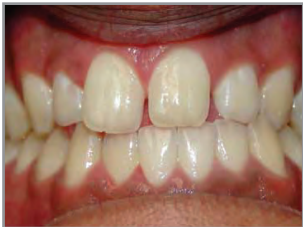TADs

Dr. Terry Carlyle 154
Dr. Dustin Coles..... 70
Dr. Bella Shen Garnett..... 90
Drs. Stanley and Scott Gersch 12
Dr. Ramtin Nassiri 112
Dr. Luis Piedade..... 38
Dr. John Sparaga..... 134

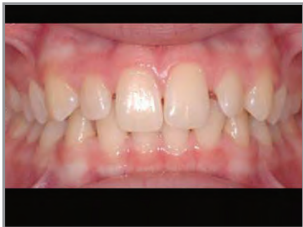VISUAL INDEX



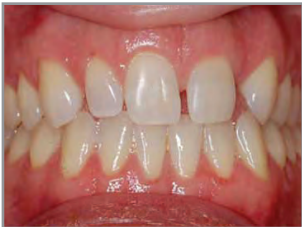78



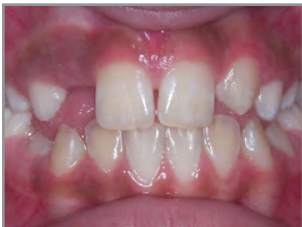168



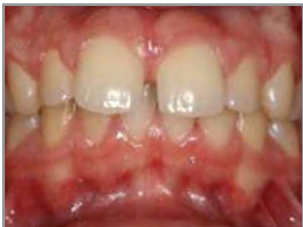122



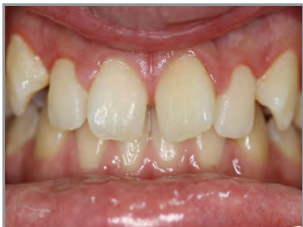34



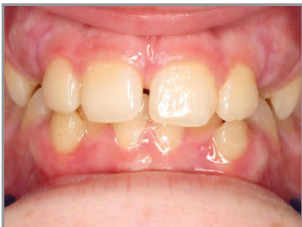20



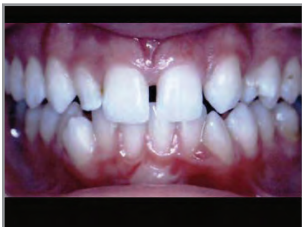82



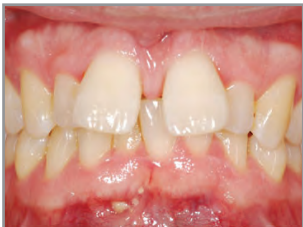124



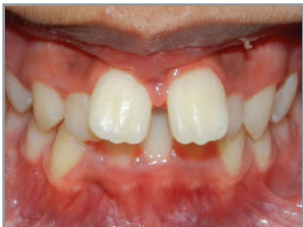8



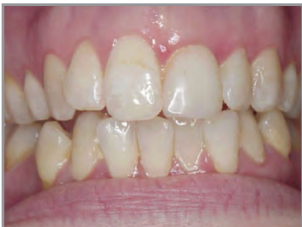152



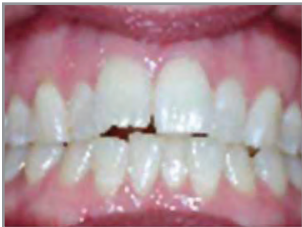134



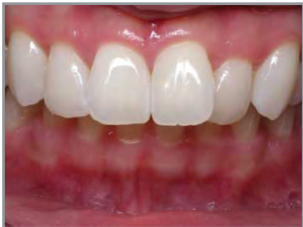102



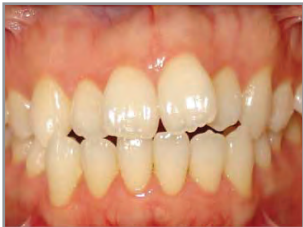106



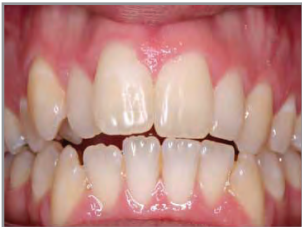16



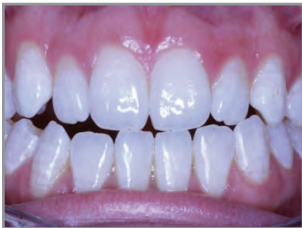86



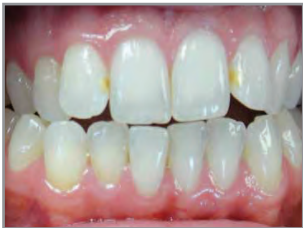30



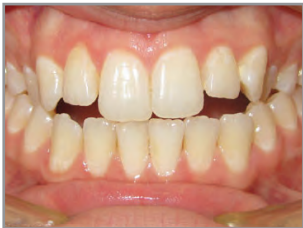92



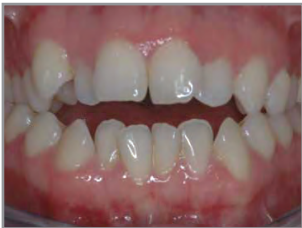172



64



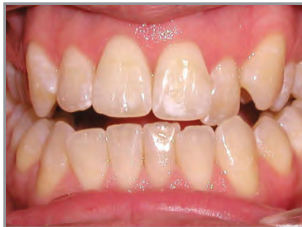150



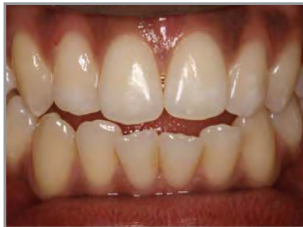170

180

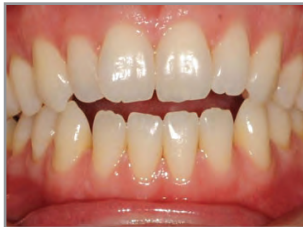VISUAL INDEX



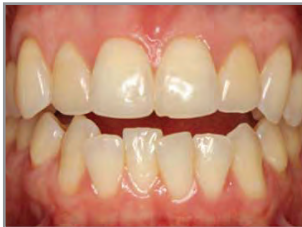24



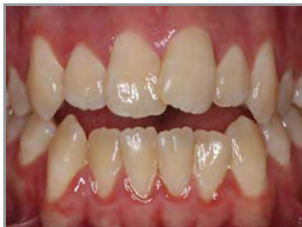6



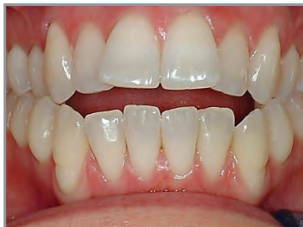44



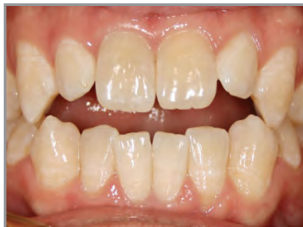42



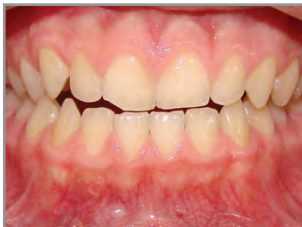154



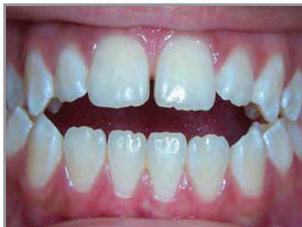56



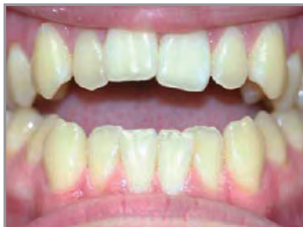38



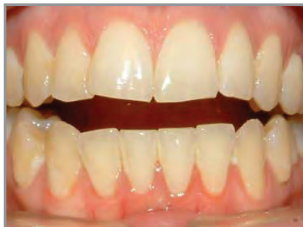28



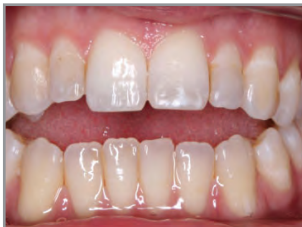50



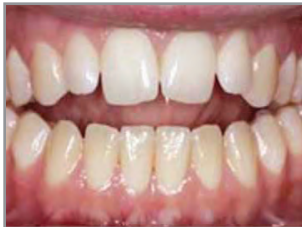174



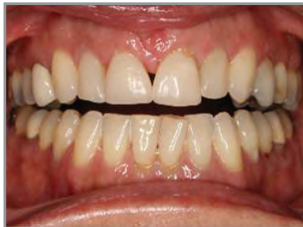12



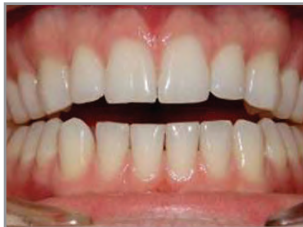90



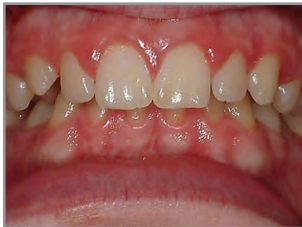58



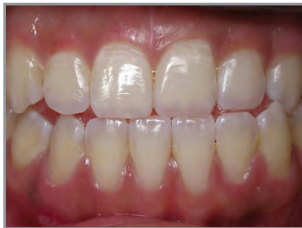112



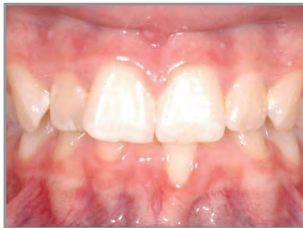88



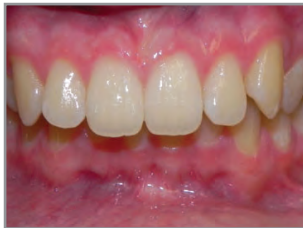100



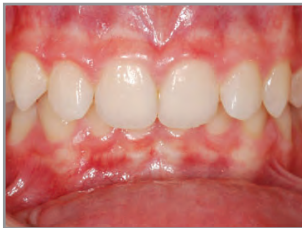158



48



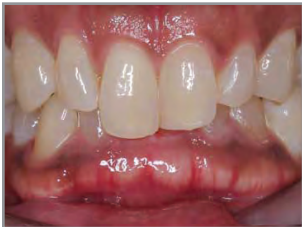104



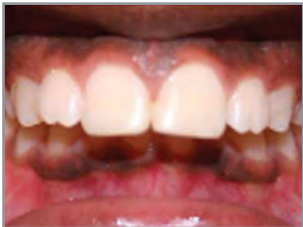132

181

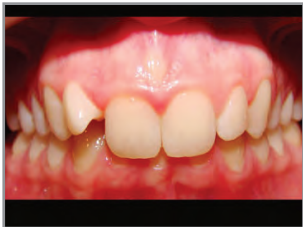VISUAL INDEX



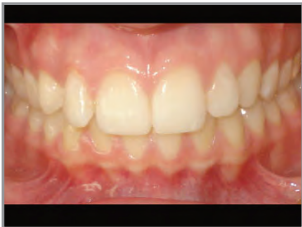52



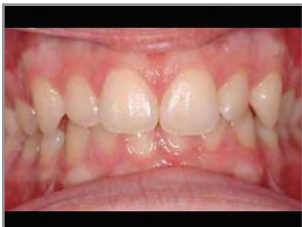60



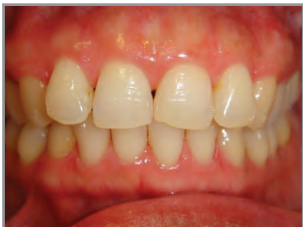26



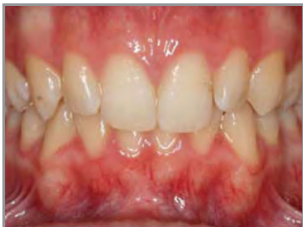32



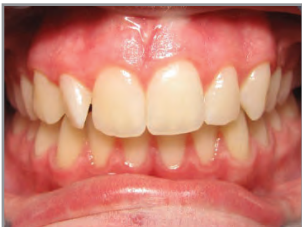120



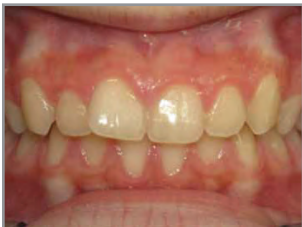62



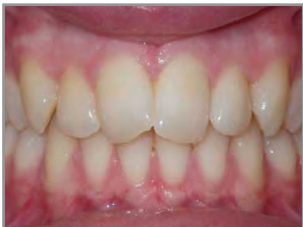136



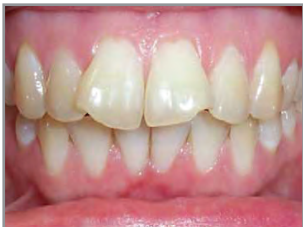110



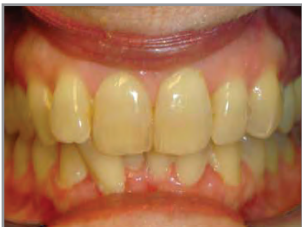126



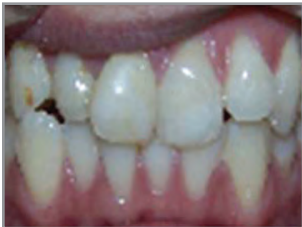96



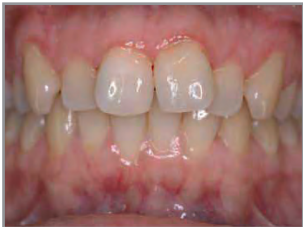76



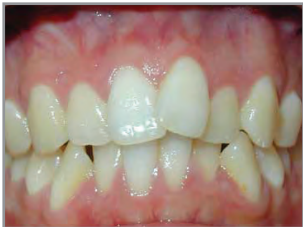22



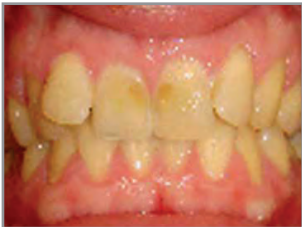10



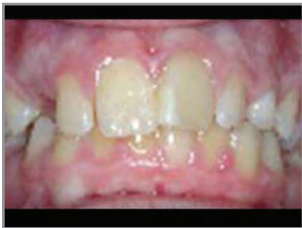98



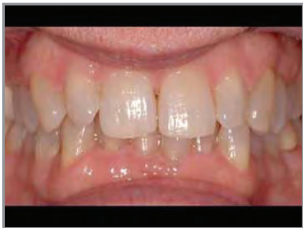4



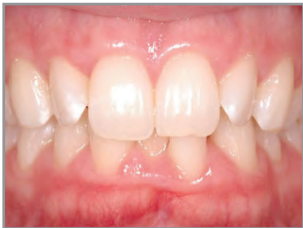128



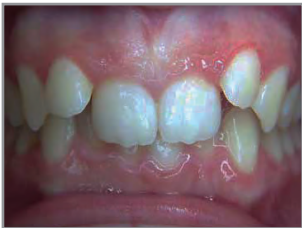18



36



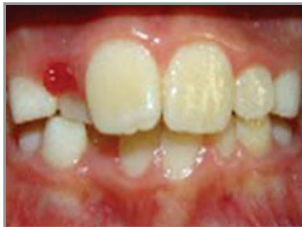46



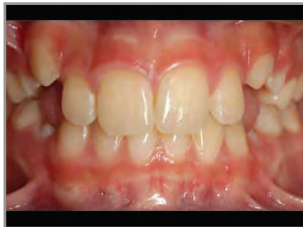72

182

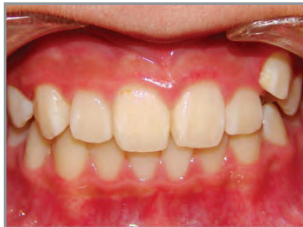VISUAL INDEX



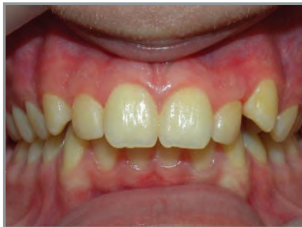80



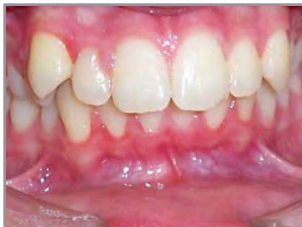40



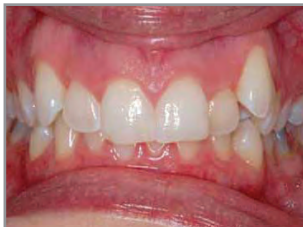114



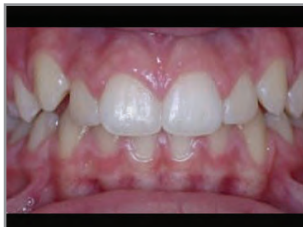68



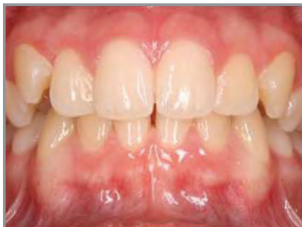74



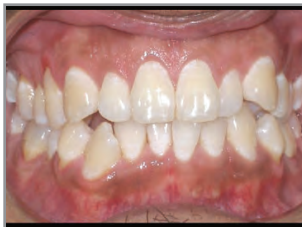118



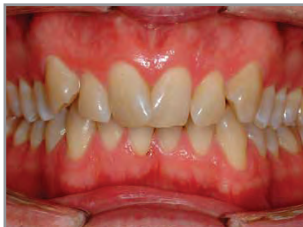2



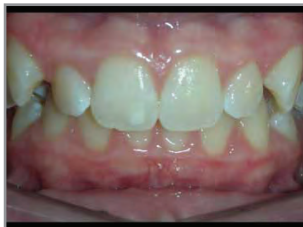108



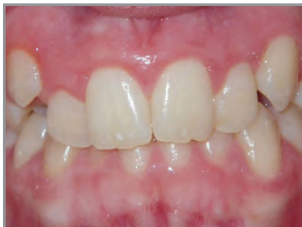144



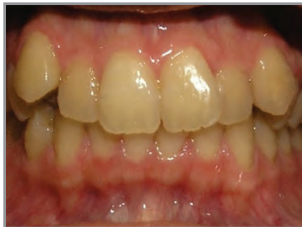84



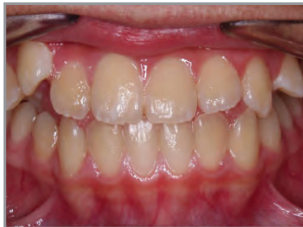138



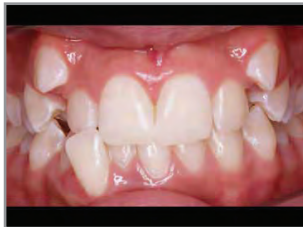94



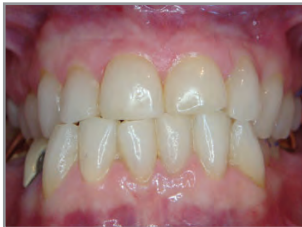142



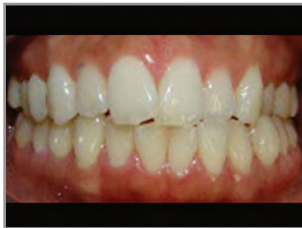160



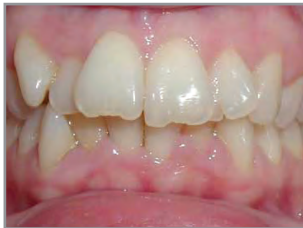140



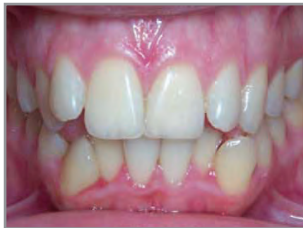164



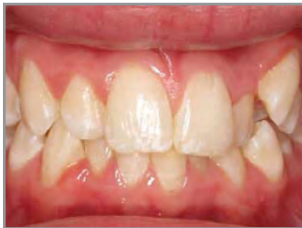156



66



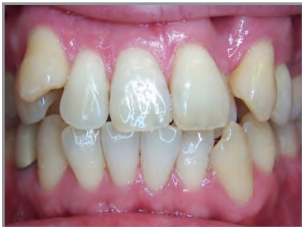166



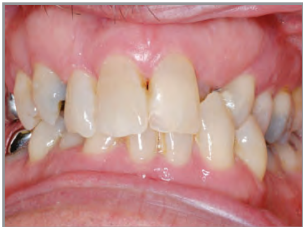14

183

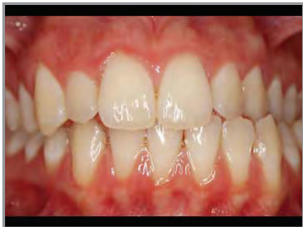VISUAL INDEX



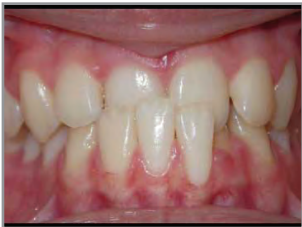70



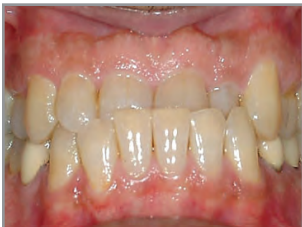116



130



162



148

2014 CLINICAL REVIEW COMMITTEE



Dr. Keith Black
Private Practice, Orthodontics – Asheville, NC
MS, Orthodontic certificate, DDS, PA – University of North Carolina at Chapel Hill
BA – Emory University
Professional associations – AAO, ADA, SAO, NCAO, SSG



Dr. Terry Carlyle
Private Practice, Orthodontics – Edmonton, AB, Canada
MSc Orthodontics – University of Manitoba; DDS – University of Alberta
Teaching affiliation – University of Alberta, Edmonton, AB, Canada
Professional associations – CAO, AAO, ADA, ASO, PCSO, FRCDC



Dr. Brett Gluck
Private Practice, Orthodontics – Alpharetta and Johns Creek, GA
MS, Orthodontic certificate, DMD – Medical University of South Carolina
BSEE – Fairleigh Dickinson University
Professional associations – AAO, ADA, SAO, GAO, GDA, Hinman Dental Society



Dr. Terry Gruelle
Private Practice, Orthodontics – Florence, KY and Montgomery, OH
MS, Orthodontic certificate – University of North Carolina
DMD – University of Kentucky
Professional associations – AAO, ABO, CDABO, ADA, SAO, KDA, ODA



Dr. Sandra Tai
Private Practice, Orthodontics – Richmond and Burnaby, BC, Canada
MS, Orthodontic certificate – University of Minnesota; BDS – University of Malaya
Teaching affiliation – University of British Columbia, Vancouver, BC, Canada
Professional associations – AAO, CAO, FRCDC, FCDSBC



Dr. Eric Wu
Private Practice, Orthodontics – Palo Alto, CA
Orthodontic certificate – University of Pittsburgh; AEGD – UCLA; DMD – University of Pennsylvania
Teaching affiliation – University of the Pacific, San Francisco, CA
Professional associations – AAO

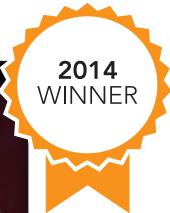

2014 AWARD RECIPIENTS

Invisalign Summit Shootout
November 13-16, 2014
Aria Hotel & Casino
Las Vegas, NV

TOP MULTI-DISCIPLINE TREATMENT

Dr. Dustin Coles
Chandler, AZ
www.premierorthoaz.com
Page 70



TOP CLASS II TREATMENT

Dr. Jose Luis Garcia
Temecula, CA
www.bracesbygarcia.com
Page 88



TOP OPEN BITE/DEEP BITE TREATMENT

Dr. Luis Piedade
Waterloo, ON, Canada
www.ritebite.ca
Page 38



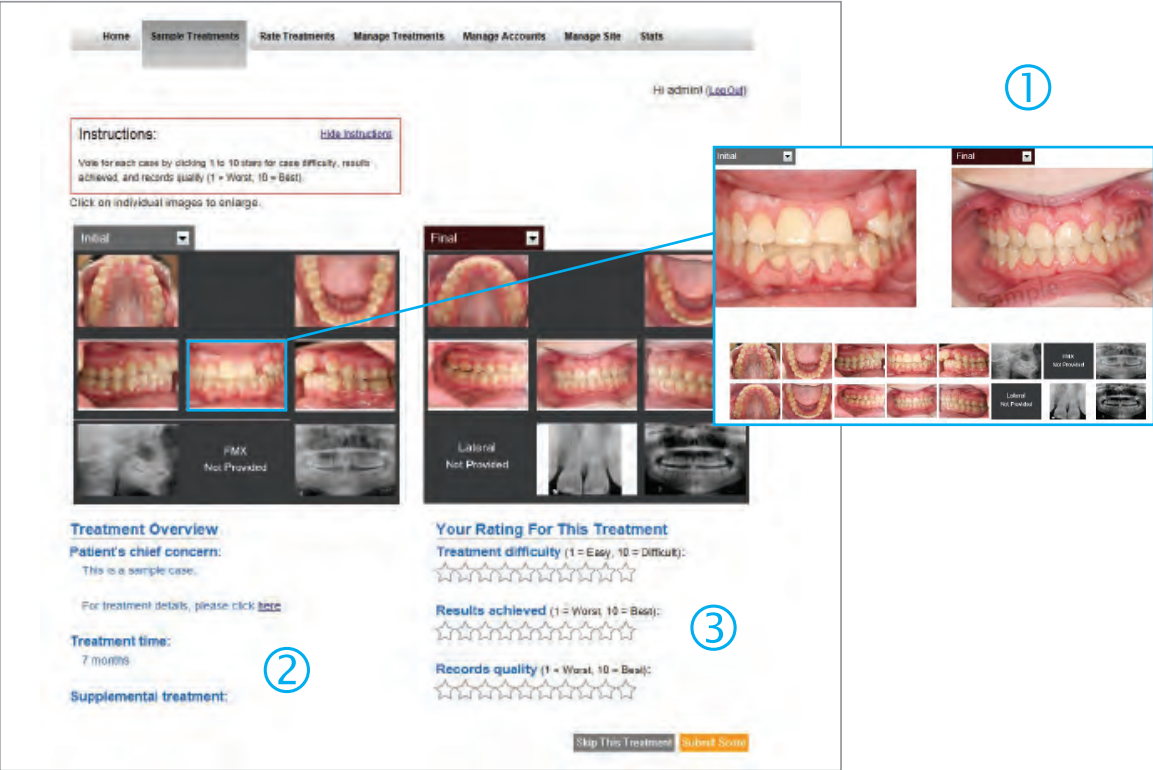
TOP TEEN TREATMENT

Dr. Kenyu Takamoto
Bellevue, WA
www.drtakamoto.com
Page 174



METHODOLOGY

The top treatments of the 2014 Invisalign Gallery were determined through double-blind online voting on a secure website developed by Align Technology, Inc. All records were displayed on the SmileScore.com website with any identifiers of the patient and treating doctor concealed. An optimization algorithm presented the treatments with the fewest votes collected first, so that the number of votes received per treatment was similar. All online voting was performed by orthodontists experienced with Invisalign treatment. Doctors with cases entered into the competition were ineligible to vote.



1 Close-up and comparison views were displayed by clicking on the image of interest. With the exception of cropping and image orientation, all clinical images were displayed as originally submitted by the treating doctor. All images (including radiographs) were taken and provided at the sole discretion of the treating doctor.

2 The treatment overview section included the patient's chief concern, the treatment time, and any auxiliaries used in conjunction with clear aligners (as reported by the treating doctor). Certain details about treatment such as the number of aligners used and the retention protocol were not displayed at the time of voting, but are reported in this publication.

METHODOLOGY


3 Doctors rated each case on a scale of 1 (worst) to 10 (best) based on three criteria and could only vote on each case once. To prevent selective voting, skipped cases could not be revisited. Skipped cases, however, were not counted towards the average composite score calculated.

INVISALIGN GALLERY PROGRAM DETAILS

- Entries for publication consideration (230 total) were submitted by orthodontists covered by Align Technology's North American Sales Team, and included submissions into the Invisalign Summit Shootout, along with submissions for Invisalign Gallery publication consideration only. Participants were able to enter one case per treatment category into the program, up to 4 cases total.
- Each entry was screened by an independent Clinical Review Committee. Committee members were eligible to submit entries, but could not vote on their own case(s). All reviewers were blinded to the identities of both the treating doctor and the patient. The top 85 cases from the initial screening process were published in the 2014 Invisalign Gallery and advanced as semi-finalists to the online voting phase of the program.
- Invitations for online voting were sent via email to orthodontists experienced with Invisalign treatment who were not registered to attend the 2014 Invisalign Summit. From the 5,298 email invitations sent, 308 orthodontists participated in the online voting process, with 5,749 votes received during a five-week voting window. All voting was voluntary, anonymous, and double-blind. Doctors who were semi-finalists were ineligible to vote.

- Treatments were presented on the voting website at random, with a distribution optimization algorithm used to ensure that a similar number of votes were received per treatment.
- The four Invisalign Summit Shootout finalists were determined based on the highest average composite score received for the category, on a scale of 1.0 (worst) to 10.0 (best). Composite scores were calculated based on treatment difficulty (40%), results achieved (40%), and records quality (20%). The Summit Shootout winner was determined by attendees at the Invisalign Summit continuing education event (November 13-16, 2014).
- Written patient and doctor consent (including parental consent where applicable) was received for all the treatments presented in this book.
- Every effort was made to accurately represent the treatment details as reported by the treating doctor. The categorization of each submission was based solely on the treating doctor's assessment of the patient's condition. With the exception of cropping/orientation, background extensions to fit the layout, and adjustments to color and contrast, all clinical images in this publication are presented as submitted.
- Doctors who provided optional study models in addition to their submitted photographs and radiographs were compensated in the amount of up to \$300 for the doctor and up to \$50 for the patient.
- For more information and full program details, please visit: www.InvisalignGallery.com.

2014 INVISALIGN GALLERY & UNIVERSITY CHALLENGE TEAM



PRODUCTION LAYOUT

Dr. Shirin Behdad
Emma Chen
Anna DeCicco

RECORDS COLLECTION LEAD

Wendy Liu

TECHNICAL LEAD

Eakta Malik

GRAPHIC DESIGN/ARTWORK

Christopher Carter

SOFTWARE DEVELOPMENT

Graham Westerlund

PROJECT SUPPORT

Isaac Kang
Sara Moghul
Sherri Wilson-Lopes

STATISTICAL VERIFICATION

Larry Lai, PhD

SUMMIT EVENT COORDINATORS

Shannon Henderson
Kimberly Holmes

REGULATORY/LEGAL COMPLIANCE

Karrie Anger
K Royal

PHOTO EDITORS

Lauren Frisch
Rickelle Shaw
Thu-Ha Truong
Dr. Kelly Weikert

EDITOR

Dr. Eric Kuo

