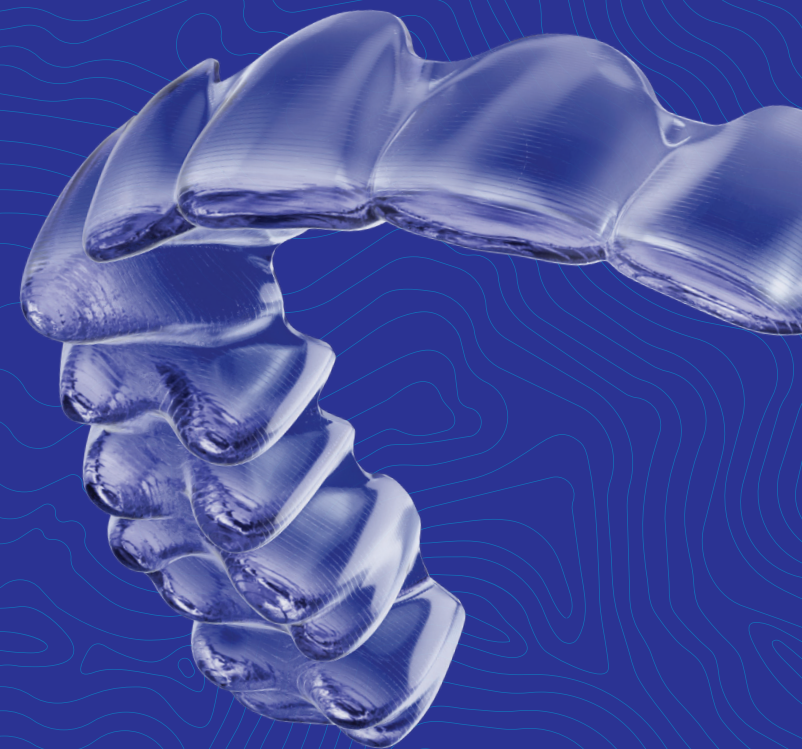

Invisalign Gallery 2015

Invisalign® Gallery 2015



Align Technology, Inc.
2560 Orchard Parkway
San Jose, CA 95131

www.invisalign.com

2015 INVISALIGN® GALLERY

Library of Congress Cataloging-in-Publication Data

Invisalign® Gallery 2015/Edited by Dr. Mitra Derakhshan

p. cm.
Includes index.

ISBN-10: 0692858653

ISBN-13: 978-0-692-85865-3

1. Orthodontics, Corrective 2. Orthodontic Appliances

I. Align Technology, Inc.

©2015 Align Technology, Inc. All rights reserved.

Published by Align Technology Inc., San Jose, CA

This book contains material protected under International and Federal Copyright Laws and Treaties. Any unauthorized reprint or use of this material is prohibited. No part of this book may be reproduced or transmitted in any form or by any means, electronic or mechanical, including photocopying, recording, or by any information storage and retrieval system without express written permission from the publisher. Requests to the Publisher for permission should be addressed to Align Technology, Inc., RE: Invisalign Gallery, 2560 Orchard Parkway, San Jose, CA 95131 or via email to: InvisalignGallery@aligntech.com.

All trademarks and registered trademarks are the property of their respective owners.

Limit of Liability/Disclaimer of Warranty. While the publisher and editor have used their best efforts in preparing this book, they make no representations or warranties with respect to the accuracy or completeness of the contents of this book and specifically disclaim any implied warranties, appropriateness, or fitness for a particular purpose. The strategies contained herein may not be suitable for your situation and should not be construed as medical advice. The publisher is not engaged in the business of rendering dental treatment, so a dental professional should always be consulted where appropriate. Neither the publisher nor the editor shall be liable for any loss of profit or other damages, including but not limited to special, incidental, consequential, or other damages.

Printed in the United States of America

TABLE OF CONTENTS

INTRODUCTION..... v

CLINICAL CONTRIBUTORSvii

CROWDING TREATMENTS

Dr. Keith Anderson2

Dr. Rakesh Arya4

Dr. Robert Asp.....6

Dr. Robert Asp.....8

Dr. San Bhatha 10

Dr. Ruby Bhullar..... 12

Dr. Edward Camacho..... 14

Dr. Edward Camacho..... 16

Dr. Su-Wen Chang 18

Dr. Jasbir Cheema20

Dr. Joseph Field22

Dr. Anthony Gadbois.....24

Dr. David Galler.....26

Dr. David Galler.....28

Dr. David Galler.....30

Dr. Arne Gundersen32

Dr. Mike Hinkle34

Dr. Eugene Kim.....36

Dr. Jeremy Kurtz38

Dr. Jeremy Kurtz40

Dr. Yu Li.....42

Dr. Yu Li.....44

Dr. Yu Li.....46

Dr. Steven London.....48

Dr. Steven London.....50

Dr. Debbie Mulroy52

Dr. Daniel Noor.....54

Dr. Daniel Noor.....56

Dr. Daniel Noor.....58

Dr. Brian Orcutt.....60

Dr. Bruno Paliani.....62

Dr. Bruno Paliani.....64

Dr. Patricia Primero66

Dr. Kenneth Pyle68

Dr. Stephane Reinhardt70

Dr. John Rogers72

TABLE OF CONTENTS

SPACING TREATMENTS

Dr. Payam Ataii..... 76

Dr. Anthony Gadbois..... 78

Dr. David Galler..... 80

Dr. Mike Hinkle 82

Dr. Yu Li..... 84

Dr. Daniel Noor..... 86

Dr. Stephane Reinhardt 88

Dr. Richard Schmidt..... 90

Dr. Jeffrey Tamucci 92

RESTORATIVE TREATMENTS

Dr. Joseph Field 96

Dr. David Galler..... 98

Dr. Xianglong Li..... 100

Dr. Daniel Noor..... 102

Dr. Anthony Ramirez 104

Dr. Renae Roelofs..... 106

Dr. Nathalie Tungesvik 108

Dr. Jack Von Bulow 110

ALPHABETICAL INDEX..... 112

TEEN TREATMENT INDEX 113

TREATMENT PLAN INDEX..... 114

VISUAL INDEX 116

2015 CLINICAL REVIEW COMMITTEE 120

2015 AWARD RECIPIENTS 121

METHODOLOGY 122

2015 INVISALIGN GALLERY TEAM 125

INTRODUCTION

The purpose of the Invisalign Gallery program is to celebrate the success of those who have demonstrated clinical excellence in orthodontic treatment using Invisalign aligners, and have pushed the envelope with the types of malocclusions that are being treated today.

The peer-voting process used to determine the top treatments this year was the same as in past years, and is described in the Methodology section of this book. However, the selection of the overall winner was determined through a live vote during the Invisalign Summit event held in Las Vegas, Nevada in July 2015. The bar for demonstrating clinical excellence was also raised this year. First, the clinical categories of the competition were much more challenging than before: crowding, spacing, restorative, and a unique bonus category. Second, doctors were only allowed to submit one case per clinical category.

The response with the number of cases submitted was outstanding. The treatment outcomes achieved were what many would have once thought to be impossible or impractical using clear plastic aligners. In some cases, orthodontic elastics are being used to augment treatment of the most difficult types of cases, along with accommodations being made with aligner manufacturing features such as precision cuts. Comprehensive treatment planning remains essential, and is as important to insuring excellent treatment outcomes as the appliances used.

The success achieved by the general dentists who participated in the 2015 Invisalign Gallery will hopefully bring us one step closer to ending the debate over what can or cannot be treated with clear aligners, so that greater focus and energy can be directed towards how best to efficiently achieve the desired treatment

outcome with clear aligners, supported by the continuum of new innovations such as Invisalign G-series solutions, SmartTrack material, and ClinCheck Pro software.

Congratulations to each of the doctors in the 2015 Invisalign Gallery. Your commitment to clinical excellent is unparalleled. Congratulations also to Dr. Jasbir Cheema, Dr. Stephane Reinhardt, Dr. Richard Schmidt, and Dr. Jack Von Bulow for having your work selected as the top treatments by your peers, and to Dr. Reinhardt for being chosen as the 2015 Invisalign Gallery Summit Shootout winner.



Mitra Derakhshan

Dr. Mitra Derakhshan
Editor, Invisalign® Gallery 2015

CLINICAL CONTRIBUTORS

Dr. Keith Anderson
Keith F. Anderson, DMD, PC
St. Louis, MO
www.RadiantSmilesSTL.com

Dr. Su-Wen Chang
Dr. Chang Dentistry
Tucson, AZ
www.DrChangDentistry.com

Dr. Rakesh Arya
Dr. R.K. Arya, Inc.
Abbotsford, BC, Canada
www.AbbotsfordDentist.com

Dr. Jasbir Cheema
Cheema Dental Orthodontics
Stockton, CA
www.CheemaDental.com

Dr. Robert Asp
Live Life Smiling Family Dentistry
Appleton & Hilbert, WI
www.LLSmiling.com

Dr. Joseph Field
Peninsula Center of Cosmetic Dentistry
Los Altos, CA
www.PCCD.net

Dr. Payam Ataii
Laser Dental Center
Laguna Hills, CA
www.LaserDentalCenterOC.com

Dr. Anthony Gadbois
Cherry Hill Dental Associates, Inc.
Columbia, MO
www.CherryHillDentalOnline.com

Dr. San Bhatha
Southridge Dental
Surrey, BC, Canada
www.SouthridgeDental.ca

Dr. David Galler
Premier Dental Associates of Lower Manhattan
New York, NY
www.PremierDentalAssociates.com

Dr. Ruby Bhullar
Eagle Landing Dental
Chilliwack, BC, Canada
www.EagleLandingDental.com

Dr. Arne Gundersen
Gundersen Dental Care
Tumwater, WA
www.GunderSmile.com

Dr. Edward Camacho
Cosmetic Dentistry of San Antonio
San Antonio, TX
www.CosmeticDentistryOfSA.com

Dr. Mike Hinkle
Utica Dental
Tulsa, OK
www.UticaDental.com



CLINICAL CONTRIBUTORS

Dr. Eugene Kim
San Diego California Dental Group
San Diego, CA
www.SDDentalGroup.com

Dr. Jeremy Kurtz
Dental Arts At Lawrence
Toronto, ON, Canada
www.DentalArtsAtLawrence.com

Dr.Xianglong Li
Xianglong Li, DDS, MA, PC
New York, NY
www.facebook.com/xianglonglidds

Dr. Yu Li
City Centre Dental Clinic
Surrey, BC, Canada
www.facebook.com/dryuli

Dr. Steven London
London Dental Group
Boca Raton, FL
www.StevenLondonDDS.com

Dr. Debbie Mulroy
All West Dental
Lethbridge, AB, Canada
www.AllWestDental.com

Dr. Daniel Noor
Smile Café
New York, NY
www.SmileCafeNY.com

Dr. Brian Orcutt
Orcutt Family Dentistry
Fair Oaks, CA
www.FairOaksClearBraces.com

Dr. Bruno Paliani
Paliani Dentistry, PC
London, ON, Canada
www.SmileDentist.com

Dr. Patricia Primero
The Smile Fairy Dental Spa
Naples, FL
www.TheSmileFairy.com

Dr. Kenneth Pyle
Orlando Dental Group
Orlando, FL
www.OrlandoDentalGroup.com

Dr. Anthony Ramirez
Anthony Ramirez, DDS, MAGD
Brooklyn, NY
www.DrAnthonyRamirez.com

Dr. Stephane Reinhardt
Clinique Dentaire Reinhardt, Thibert & Assoc.
Brossard, QC, Canada
www.CliniqueRTA.com

Dr. Renae Roelofs
Personal Dental Care
N. Chesterfield, VA
www.Dentist4YourSmile.com

CLINICAL CONTRIBUTORS

Dr. John Rogers
White Rock Dental Clinic
White Rock/South Surrey, BC, Canada
www.SurreyWhiteRockDentist.com

Dr. Richard Schmidt
Dentistry At 8 Nelson
Brampton, ON, Canada
www.DentistryAt8Nelson.com

Dr. Jeffrey Tamucci
Jeffrey A. Tamucci, DDS
Norwalk, CT
www.TamucciDDS.com

Dr. Nathalie Tungesvik
Diamond Ridge Dentistry
Jefferson City, MO
www.DrNathalie.com

Dr. Jack Von Bulow
Temple City Dental Care
Temple City, CA
www.TempleCityDental.com

SPECIAL THANKS TO:
Dr. Perry Jones*
Perry Jones, DDS, MAGD
Richmond, VA
www.drperryjones.com

*Provided sample treatments to display
on www.SmileScore.com

CROWDING TREATMENTS





Dr. Keith Anderson
Keith F. Anderson, DMD, PC
St. Louis, MO

www.RadiantSmilesSTL.com

TREATMENT SUMMARY

PATIENT 34-year-old female

CHIEF CONCERN The patient was concerned about her rotated front tooth.

DIAGNOSIS
Right: Class I
Left: Class I

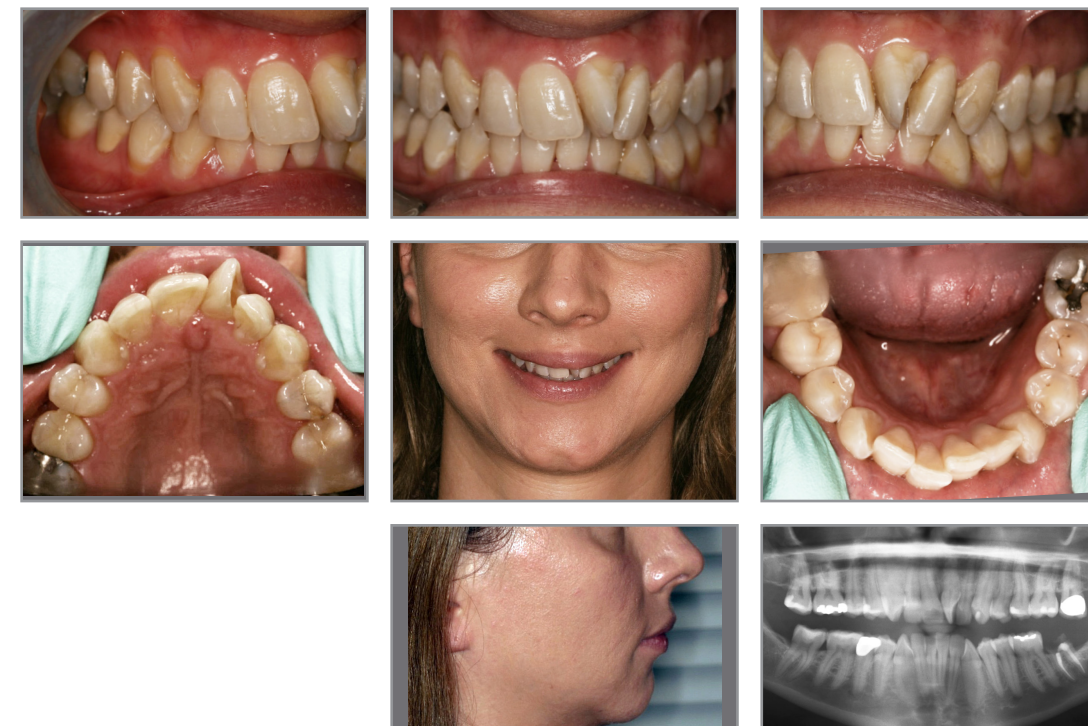Bilateral Class I molar relationship with stable posterior occlusion and narrow arch form. Significant maxillary and mandibular anterior crowding. The upper left central incisor and the lower left canine were rotated 90 degrees.

LENGTH OF TREATMENT 40 months

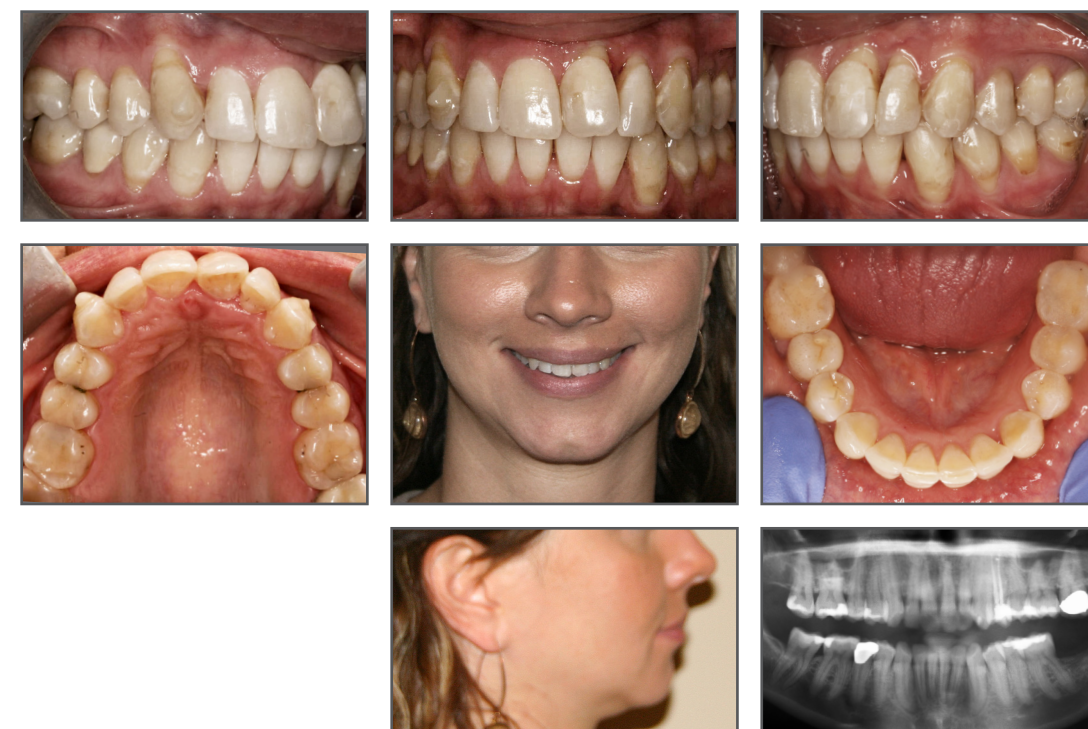OF ALIGNERS USED
Upper: 28 + 30 + 9 + 6 + 7
Lower: 28 + 30 + 9

ADDITIONAL TREATMENT None

RETENTION
Upper: Vivera® retainer over bonded lingual
Lower: Vivera® retainer over bonded lingual



BEFORE



AFTER



Dr. Rakesh Arya
Dr. R.K. Arya, Inc.
Abbotsford, BC, Canada

www.AbbotsfordDentist.com

TREATMENT SUMMARY

PATIENT 18-year-old female

CHIEF CONCERN The patient wanted to correct her crowding and crossbite.

DIAGNOSIS Right: Class I
Left: Class I

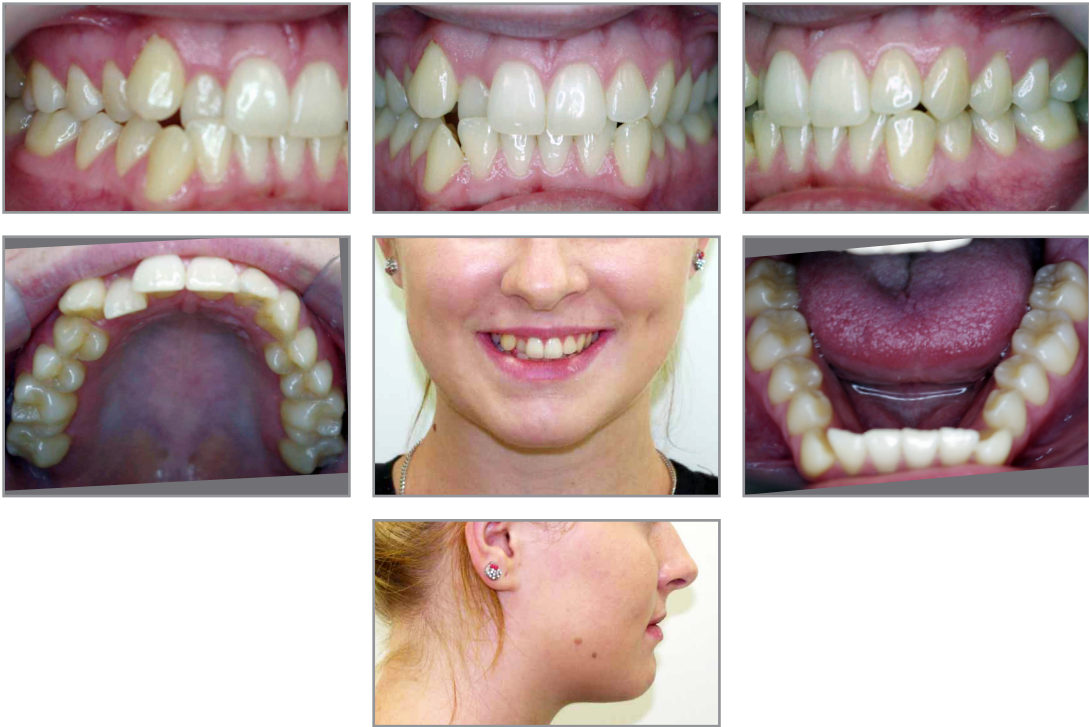Class I molar relationship with moderate to severe anterior crowding of the upper and lower arches, and the upper right lateral incisor was in crossbite.

LENGTH OF TREATMENT 9.5 months

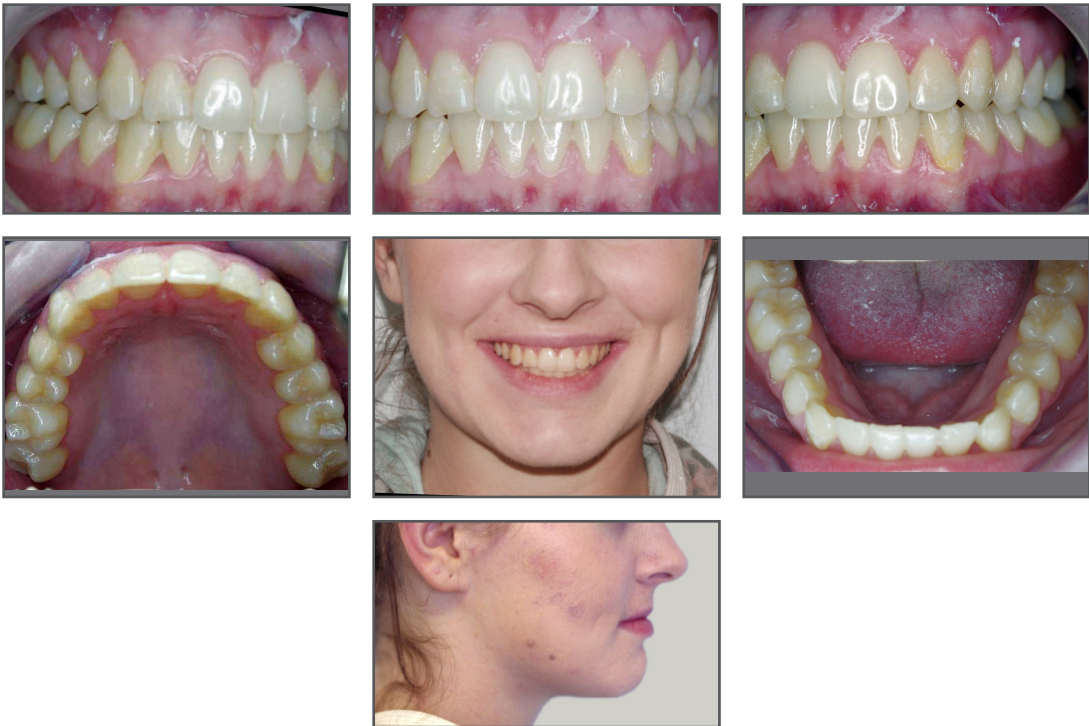OF ALIGNERS USED Upper: 19
Lower: 19

ADDITIONAL TREATMENT None

RETENTION Upper: Other clear
Lower: Other clear



BEFORE



AFTER



Dr. Robert Asp
Live Life Smiling Family Dentistry
Appleton & Hilbert, WI

www.LLSmiling.com

TREATMENT SUMMARY

PATIENT 64-year-old female

CHIEF CONCERN The patient had trouble keeping her teeth clean. She was also concerned about crowding, broken teeth, and tooth loss.

DIAGNOSIS
Right: Class II
Left: Class II

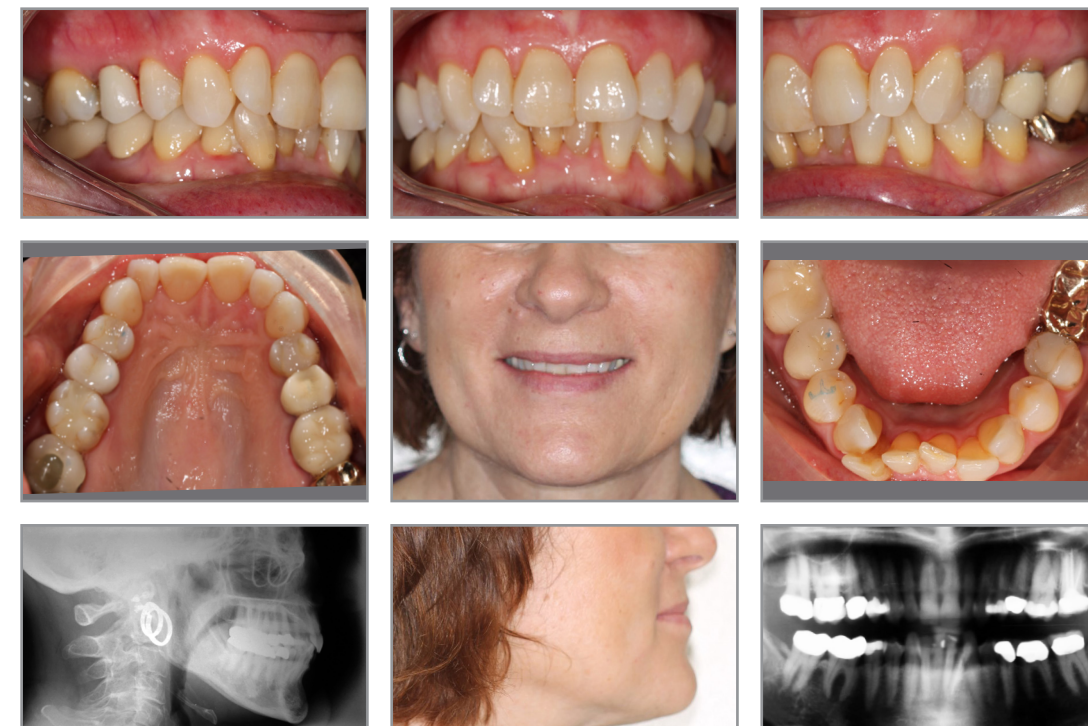Division 1 malocclusion with crowding in both arches. The patient presented with periodontal issues and a crown was needed on the lower right lateral incisor.

LENGTH OF TREATMENT 18 months

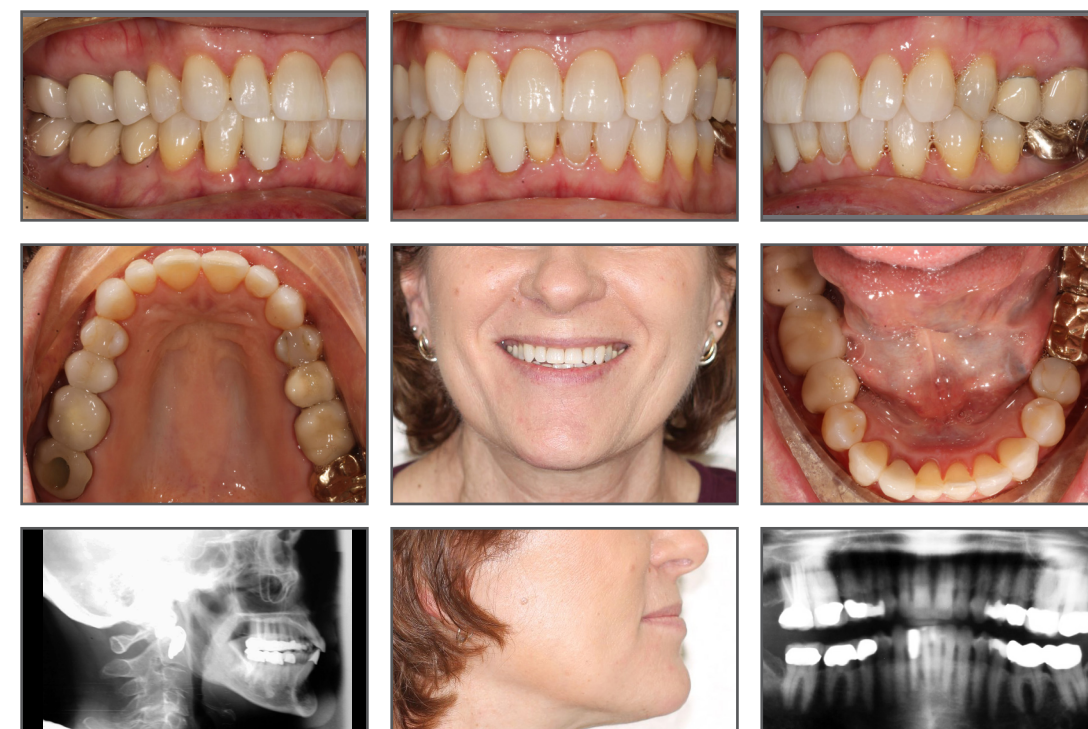OF ALIGNERS USED
Upper: 25 + 10
Lower: 25 + 10

ADDITIONAL TREATMENT After Class I occlusion was attained with Invisalign® treatment, the lower right lateral incisor was restored with a porcelain crown.

RETENTION
Upper: Vivera® retainer
Lower: Vivera® retainer



BEFORE



AFTER



Dr. Robert Asp
Live Life Smiling Family Dentistry
Appleton & Hilbert, WI

www.LLSmiling.com

TREATMENT SUMMARY

PATIENT 14-year-old female

CHIEF CONCERN The patient did not like how her front teeth were tipped backwards, and she did not smile much because of it.

DIAGNOSIS
Right: Class II
Left: Class II

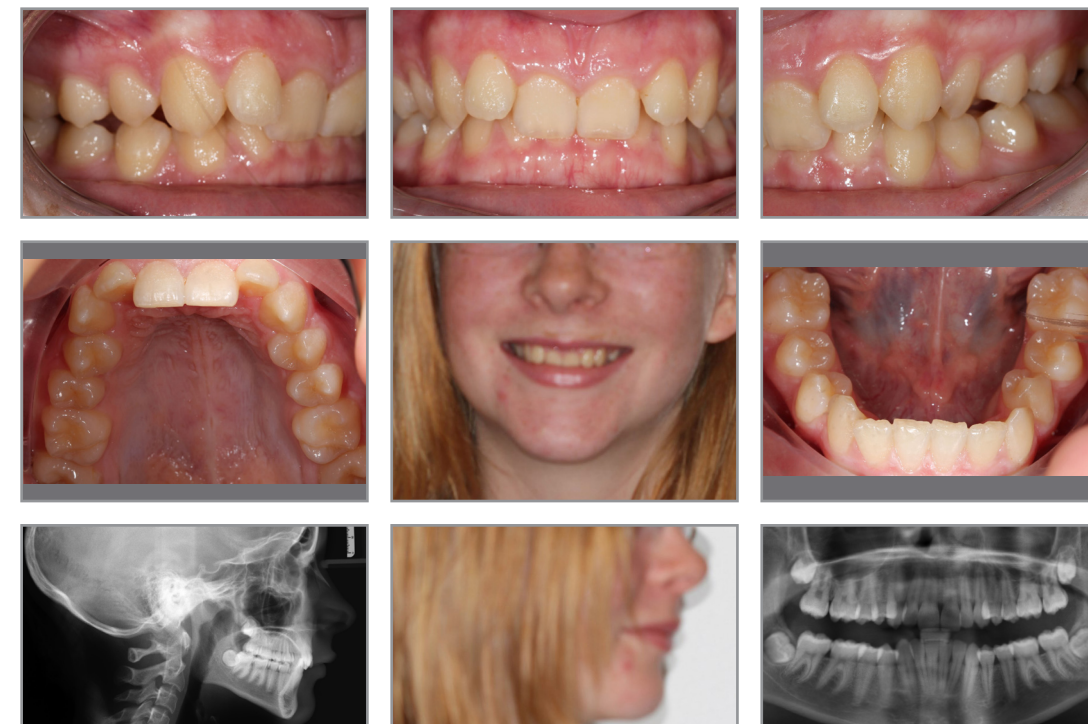Division 2 malocclusion, deep bite, and jaw pain.

LENGTH OF TREATMENT 24 months

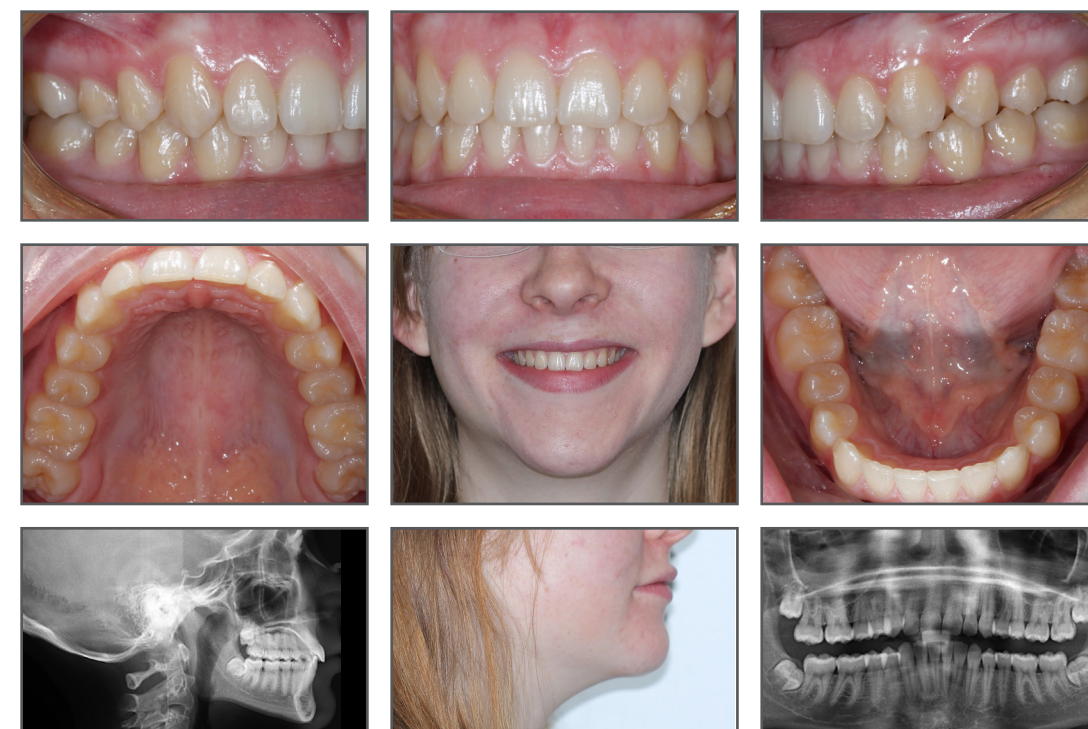
OF ALIGNERS USED
Upper: 42 + 13
Lower: 42 + 13

ADDITIONAL TREATMENT Class II elastics were used from stage 3 through stage 42, with hooks cut into the aligners near the upper canines and buttons bonded to the lower first molars.

RETENTION
Upper: Vivera® retainer
Lower: Vivera® retainer



BEFORE



AFTER



Dr. San Bhatha
Southridge Dental
Surrey, BC, Canada

www.SouthridgeDental.ca

TREATMENT SUMMARY

PATIENT 15-year-old female

CHIEF CONCERN The patient was concerned about her flared upper and lower canines, an uneven smile, and crowding.

DIAGNOSIS
Right: Class I
Left: Class I

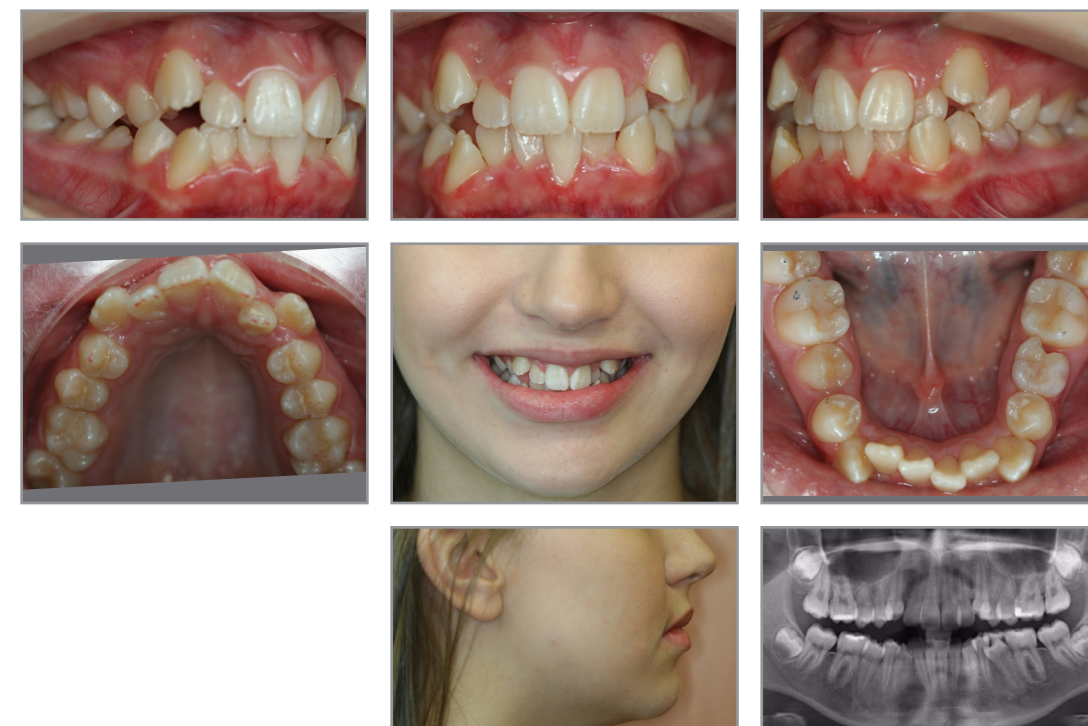
Class I molars and canines with mandibular midline shifted 5 mm to the right, 20% overbite, and severe anterior crowding in both (constricted) arches, with the upper left lateral incisor in crossbite.

LENGTH OF TREATMENT 36 months

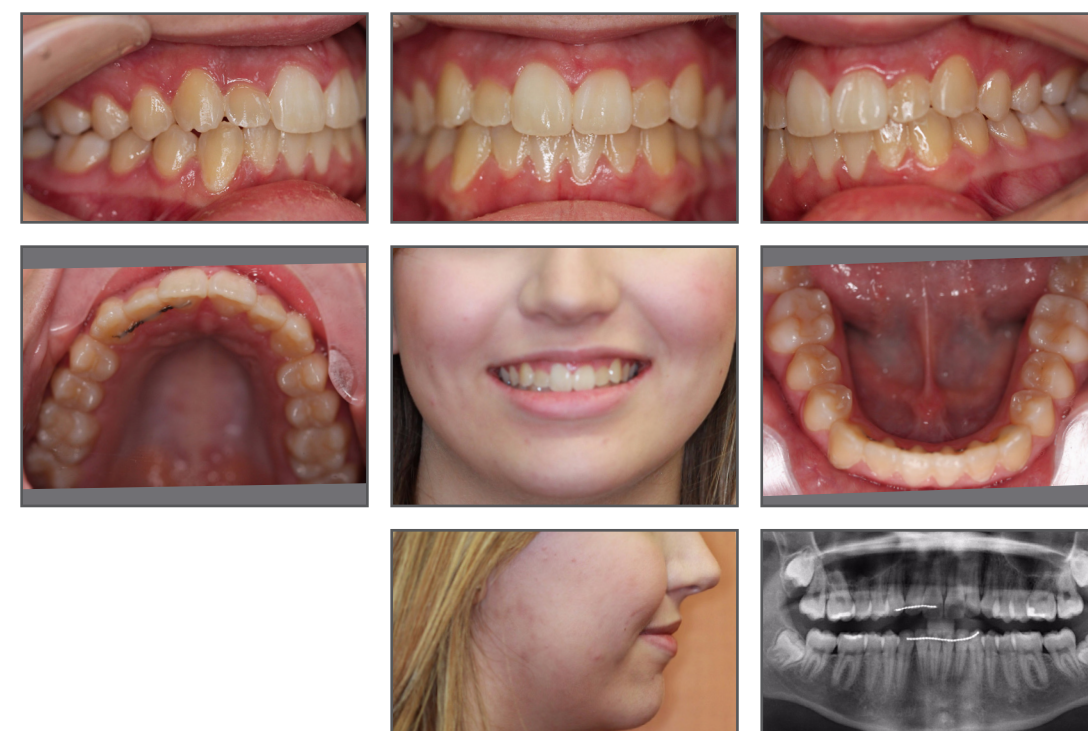
OF ALIGNERS USED
Upper: 26 + 28
Lower: 22 + 28

ADDITIONAL TREATMENT Interarch elastics were used throughout treatment, with buttons bonded to the upper laterals, all canines, and the lower first bicuspid.

RETENTION
Upper: Vivera® retainer over bonded lingual
Lower: Vivera® retainer over bonded lingual



BEFORE



AFTER



Dr. Ruby Bhullar
Eagle Landing Dental
Chilliwack, BC, Canada

www.EagleLandingDental.com

TREATMENT SUMMARY

PATIENT 30-year-old male

CHIEF CONCERN The patient was concerned that his teeth did not come together when biting. They were also crowded.

DIAGNOSIS Right: Class II
Left: Class II

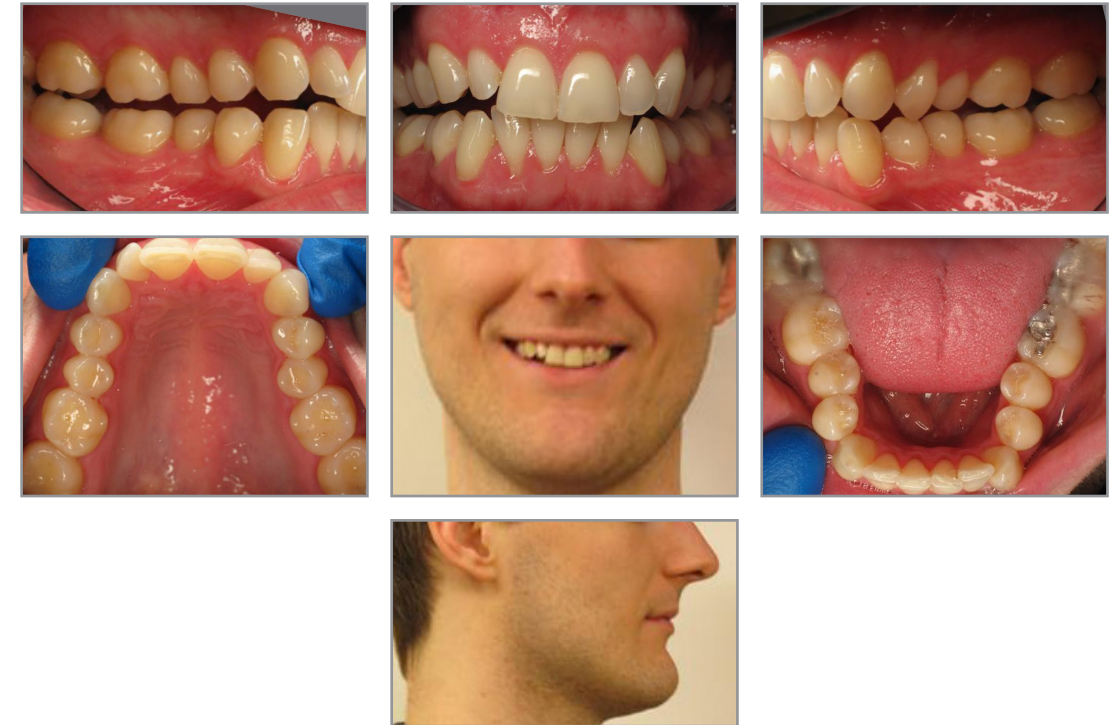Class II malocclusion with bilateral posterior open bite, narrow arches, and crowding.

LENGTH OF TREATMENT 26 months

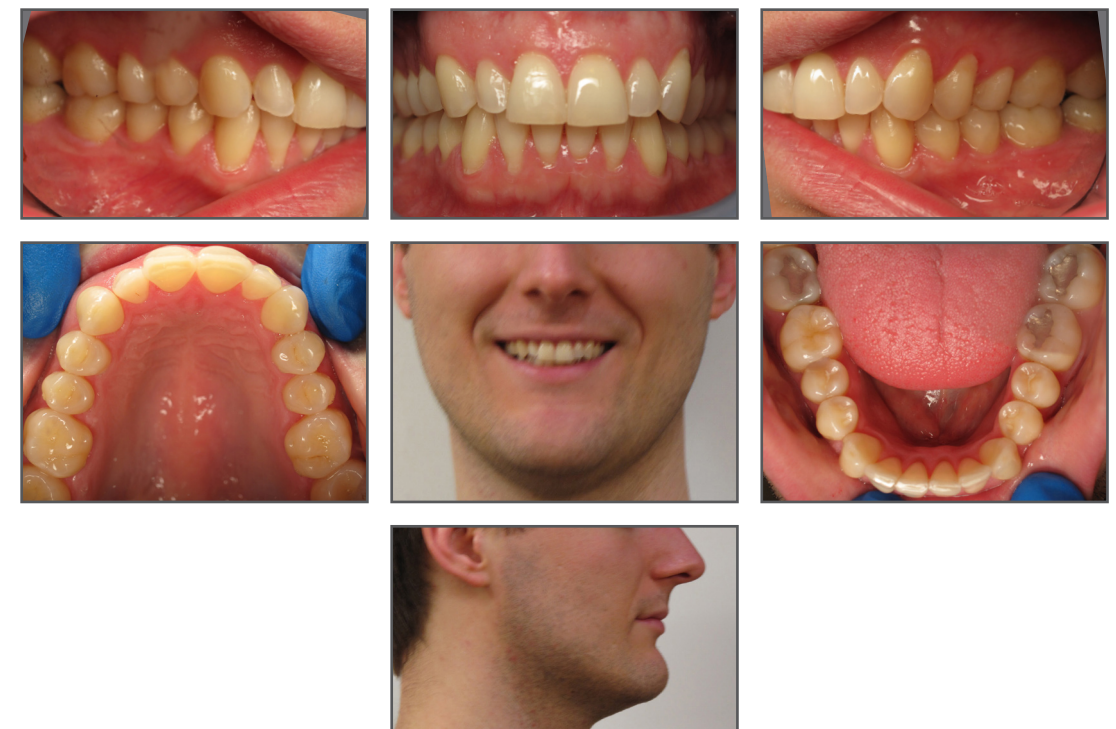OF ALIGNERS USED Upper: 17 + 9 + 14
Lower: 11 + 7

ADDITIONAL TREATMENT None

RETENTION Upper: Vivera® retainer
Lower: Vivera® retainer



BEFORE



AFTER



Dr. Edward Camacho
Cosmetic Dentistry of San Antonio
San Antonio, TX

www.CosmeticDentistryOfSA.com

TREATMENT SUMMARY

PATIENT 41-year-old male

CHIEF CONCERN The patient was concerned about his severe anterior crowding, and complained that his teeth were hard to floss. He wanted straighter teeth, but he was not concerned about any aesthetic improvements.

DIAGNOSIS Right: Class I
Left: Class III

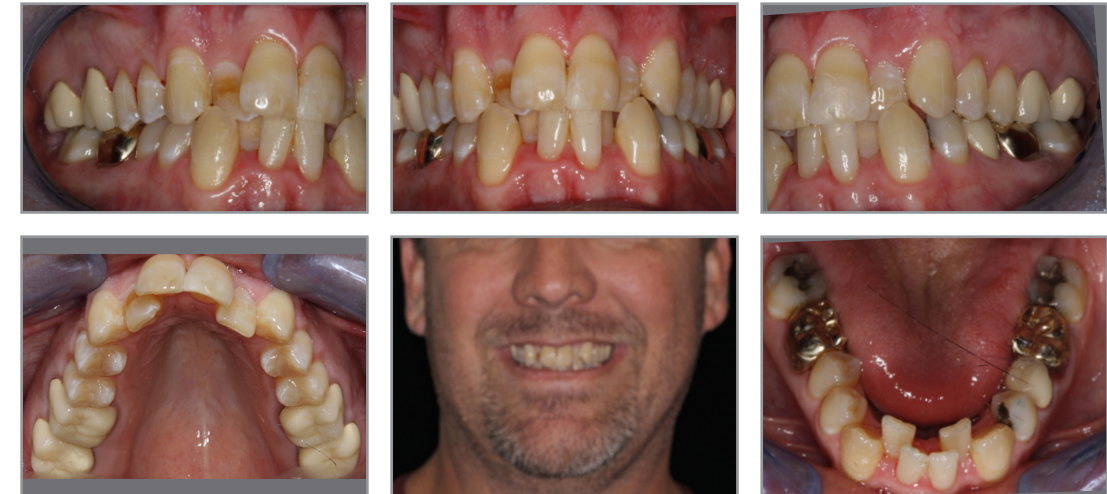Mild Class III tendency left side, and Class I right side, narrow arches, and severe anterior crowding with the upper lateral incisors in crossbite.

LENGTH OF TREATMENT 13 months

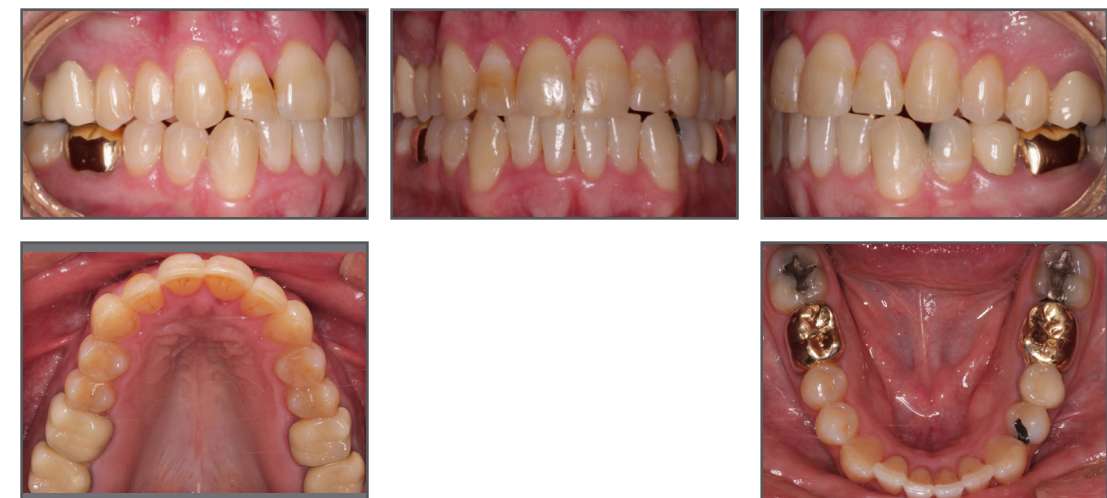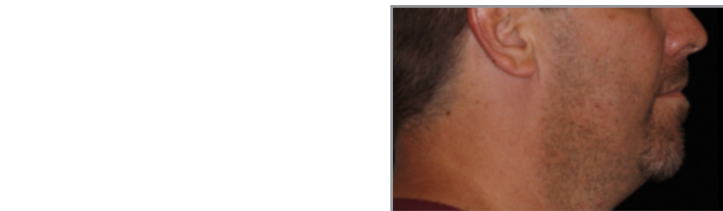
OF ALIGNERS USED Upper: 28
Lower: 28

ADDITIONAL TREATMENT None

RETENTION Upper: Vivera® retainer
Lower: Vivera® retainer



BEFORE



AFTER



Dr. Edward Camacho
Cosmetic Dentistry of San Antonio
San Antonio, TX

www.CosmeticDentistryOfSA.com

TREATMENT SUMMARY

PATIENT 27-year-old male

CHIEF CONCERN The patient was unhappy with his crowded teeth.

DIAGNOSIS
Right: Class II
Left: Class I

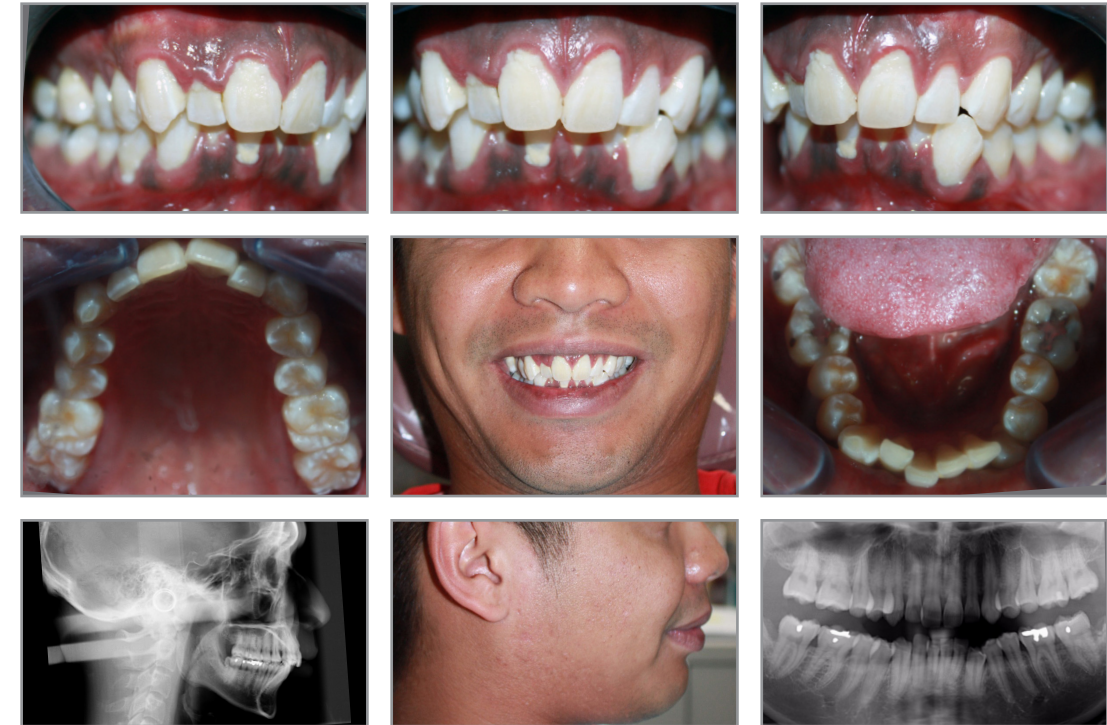Class II right side and Class I left side with moderate to severe crowding in both arches.

LENGTH OF TREATMENT 10 months

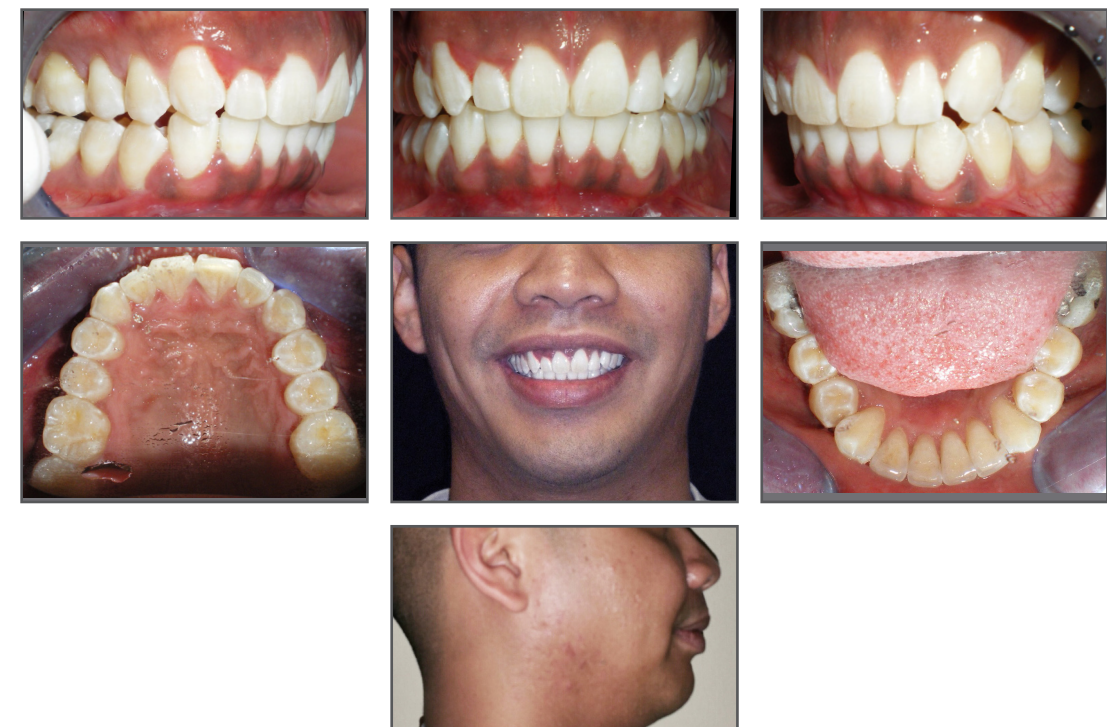OF ALIGNERS USED
Upper: 16 + 2
Lower: 17 + 2

ADDITIONAL TREATMENT In order to aid in the extrusion of the upper right lateral incisor, buttons were bonded to the lingual and facial gingival thirds of the tooth, and an elastic was stretched over the aligner.


RETENTION
Upper: Vivera® retainer
Lower: Vivera® retainer



BEFORE



AFTER



Dr. Su-Wen Chang
Dr. Chang Dentistry
Tucson, AZ

www.DrChangDentistry.com

TREATMENT SUMMARY

PATIENT 45-year-old male

CHIEF CONCERN The patient was concerned about his crowding and anterior crossbite.

DIAGNOSIS
Right: Class I
Left: Class I

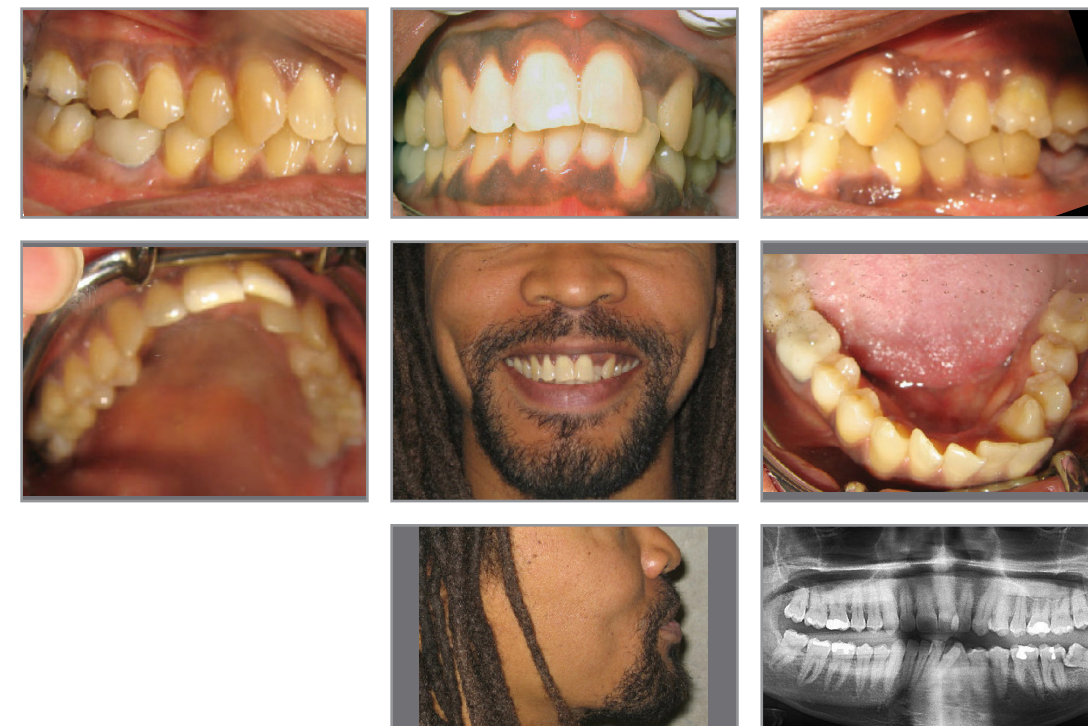Class I relationship with anterior crowding, missing lower left second molar, and the upper left lateral incisor was in crossbite.

LENGTH OF TREATMENT 19 months

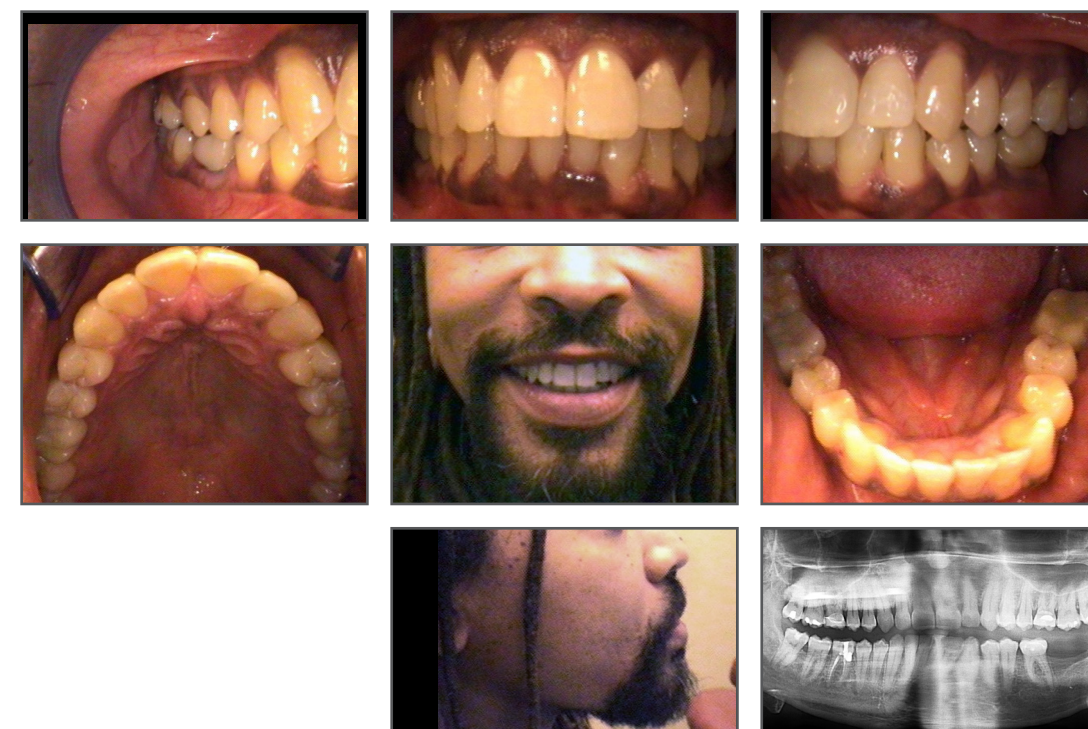OF ALIGNERS USED
Upper: 26 + 0
Lower: 26 + 4

ADDITIONAL TREATMENT None

RETENTION
Upper: Vivera® retainer
Lower: Vivera® retainer



BEFORE



AFTER



Dr. Jasbir Cheema
Cheema Dental Orthodontics
Stockton, CA

www.CheemaDental.com



TREATMENT SUMMARY

PATIENT 20-year-old female

CHIEF CONCERN The patient did not like her "underbite," and did not want to have jaw surgery.

DIAGNOSIS
Right: Class III
Left: Class III

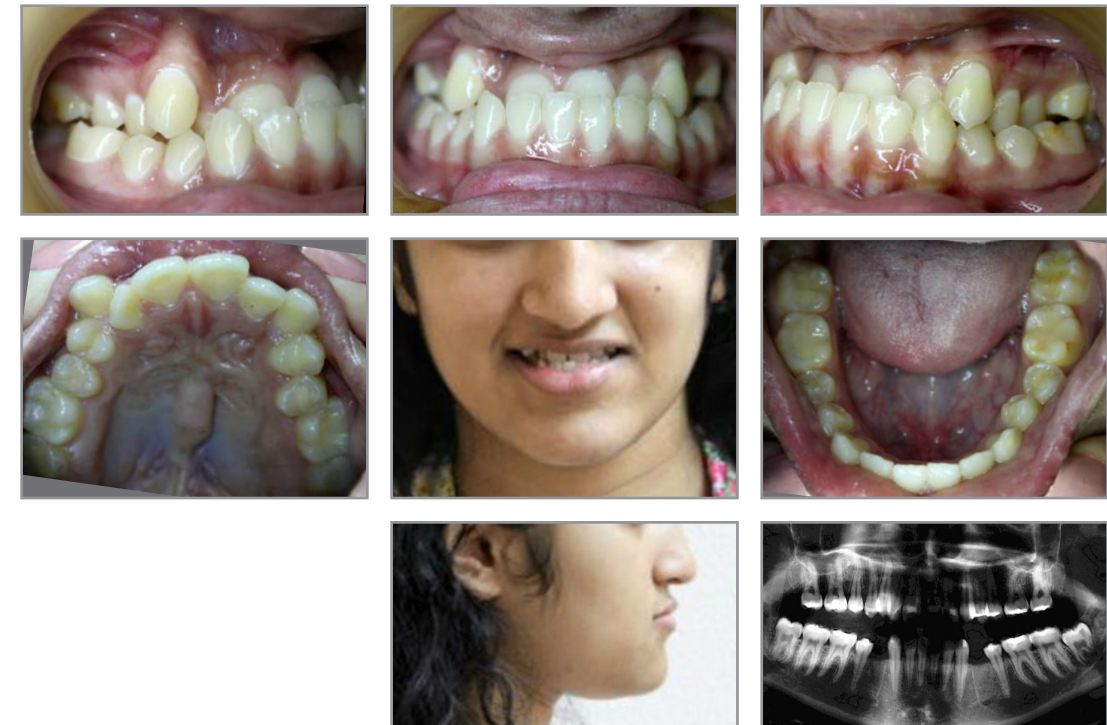Full cusp Class III relationship right side and Class III tendency left side, with collapsed maxilla, severe crowding, bilateral posterior crossbite, anterior crossbite, steep curve of Spee, and facial profile deficiency associated with limited maxillary growth.

LENGTH OF TREATMENT 40 months

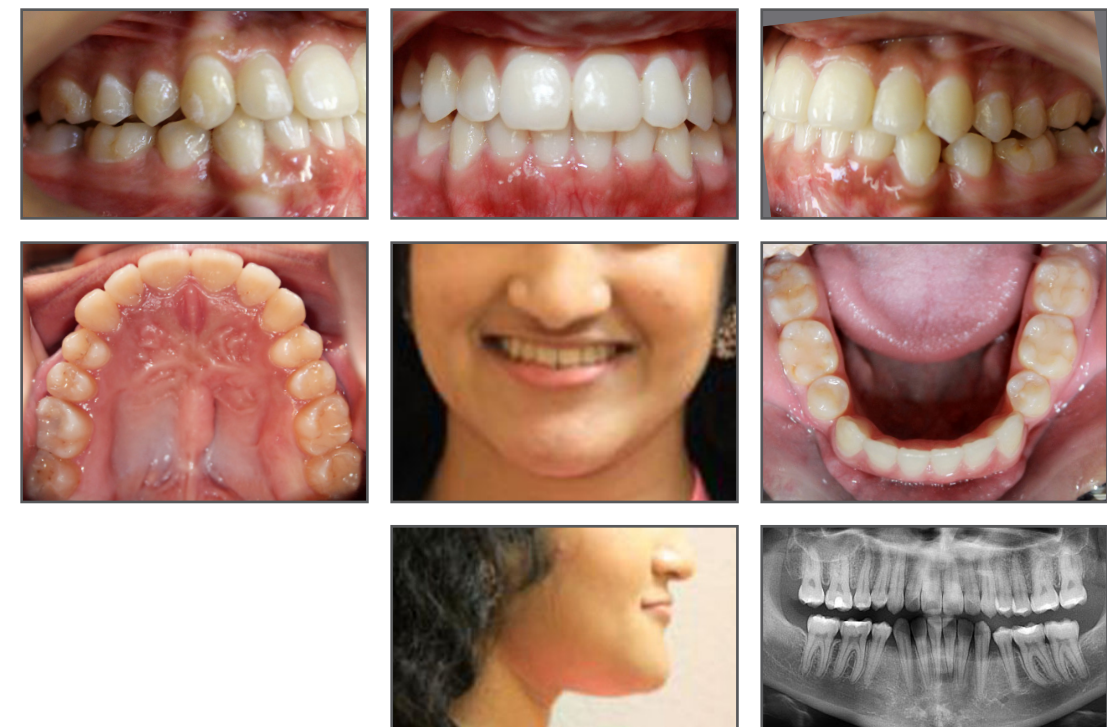
OF ALIGNERS USED
Upper: 30 + 19 + 15
Lower: 30 + 40 + 20

ADDITIONAL TREATMENT Class III elastics were used for the duration of treatment, with buttons bonded to the upper first molars and the lower canines.

RETENTION
Upper: Vivera® retainer
Lower: Vivera® retainer



BEFORE



AFTER



Dr. Joseph Field
Peninsula Center of Cosmetic Dentistry
Los Altos, CA

www.PCCD.net

TREATMENT SUMMARY

PATIENT 25-year-old female

CHIEF CONCERN The patient did not like her smile and she did not have a comfortable bite.

DIAGNOSIS Right: Class I
Left: Class I

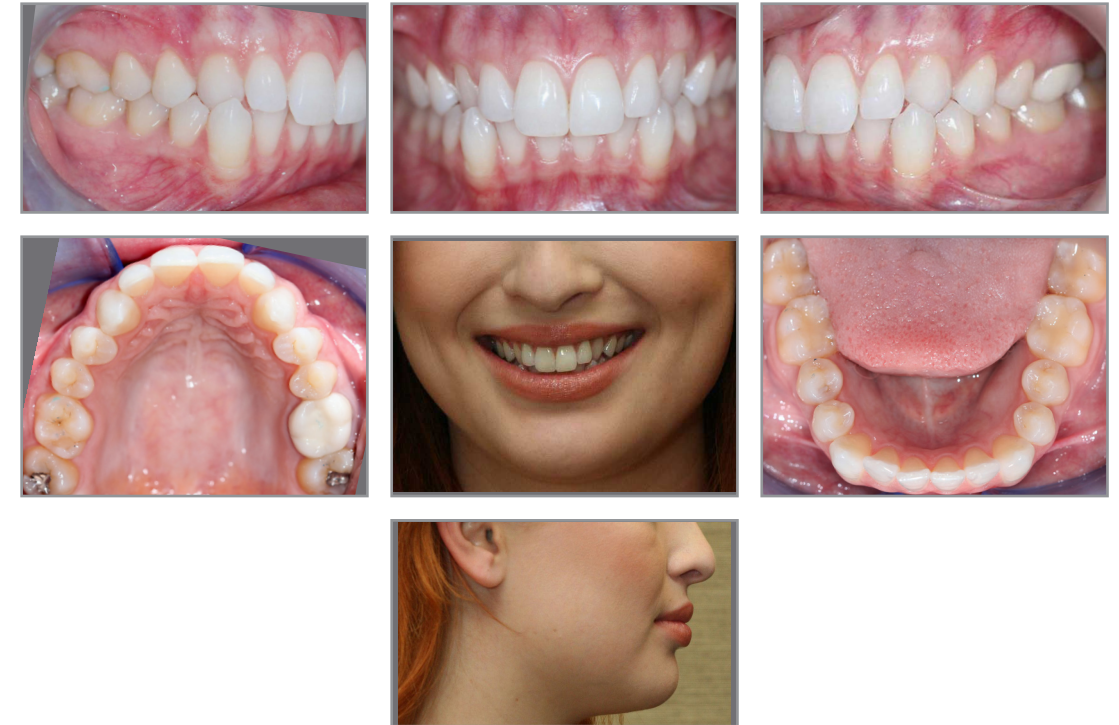Class I relationship with canines in crossbite.

LENGTH OF TREATMENT 17 months

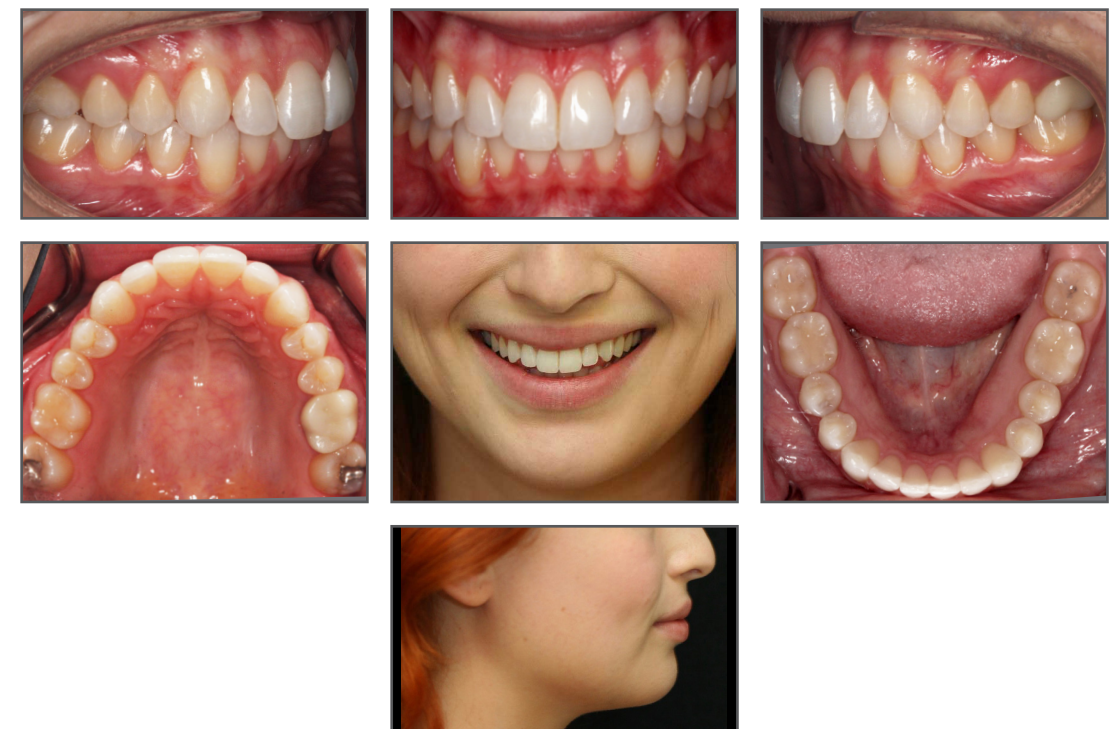OF ALIGNERS USED Upper: 9 + 10 + 2 + 12
Lower: 9 + 10 + 2 + 12

ADDITIONAL TREATMENT Occlusal equilibration was performed following Invisalign® treatment.

RETENTION Upper: Vivera® retainer
Lower: Vivera® retainer



BEFORE



AFTER



Dr. Anthony Gadbois
Cherry Hill Dental Associates, Inc.
Columbia, MO

www.CherryHillDentalOnline.com

TREATMENT SUMMARY

PATIENT 22-year-old male

CHIEF CONCERN The patient was concerned about his anterior crossbite.

DIAGNOSIS Right: Class III
Left: Class III

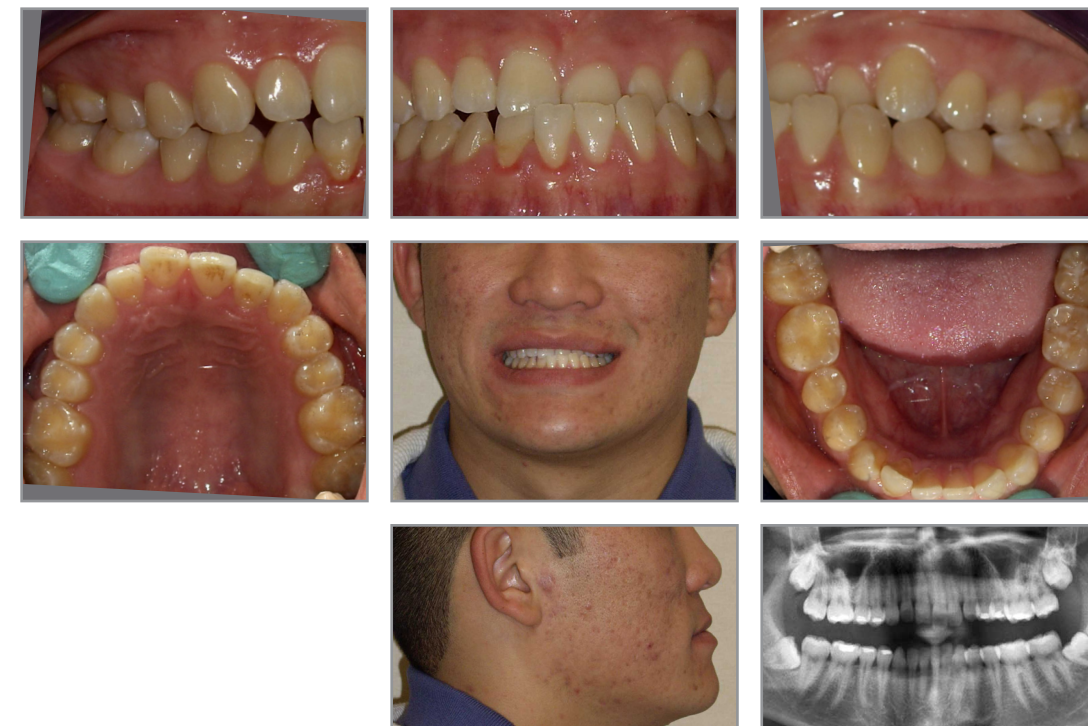Bilateral Class III tendency with crowding and anterior crossbite.

LENGTH OF TREATMENT 19 months

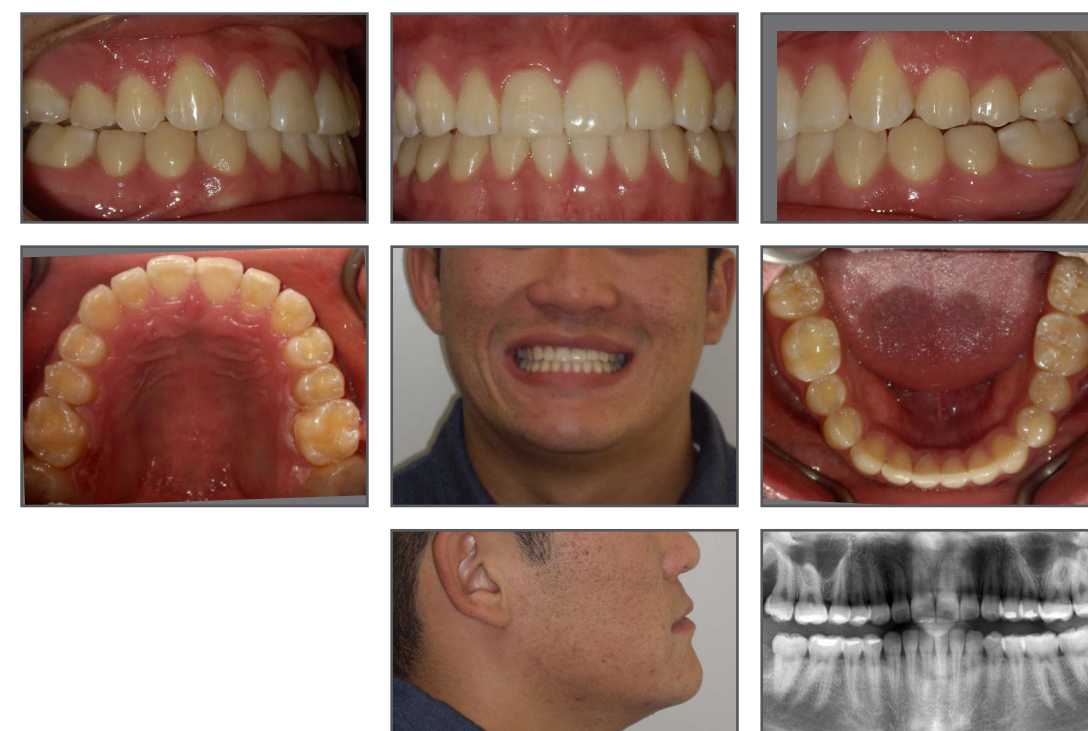OF ALIGNERS USED Upper: 33 + 3
Lower: 34 + 3

ADDITIONAL TREATMENT Class III elastics were used for the duration of treatment with hooks cut into the aligners near the upper first molars and lower canines. Buttons were placed on the upper left canine for use with extrusion elastics for six months.

RETENTION Upper: Vivera® retainer
Lower: Vivera® retainer



BEFORE



AFTER



Dr. David Galler
Premier Dental Associates of Lower Manhattan
New York, NY

www.PremierDentalAssociates.com

TREATMENT SUMMARY

PATIENT 25-year-old female

CHIEF CONCERN The patient did not like the appearance of her front teeth.

DIAGNOSIS Right: Class I
Left: Class I

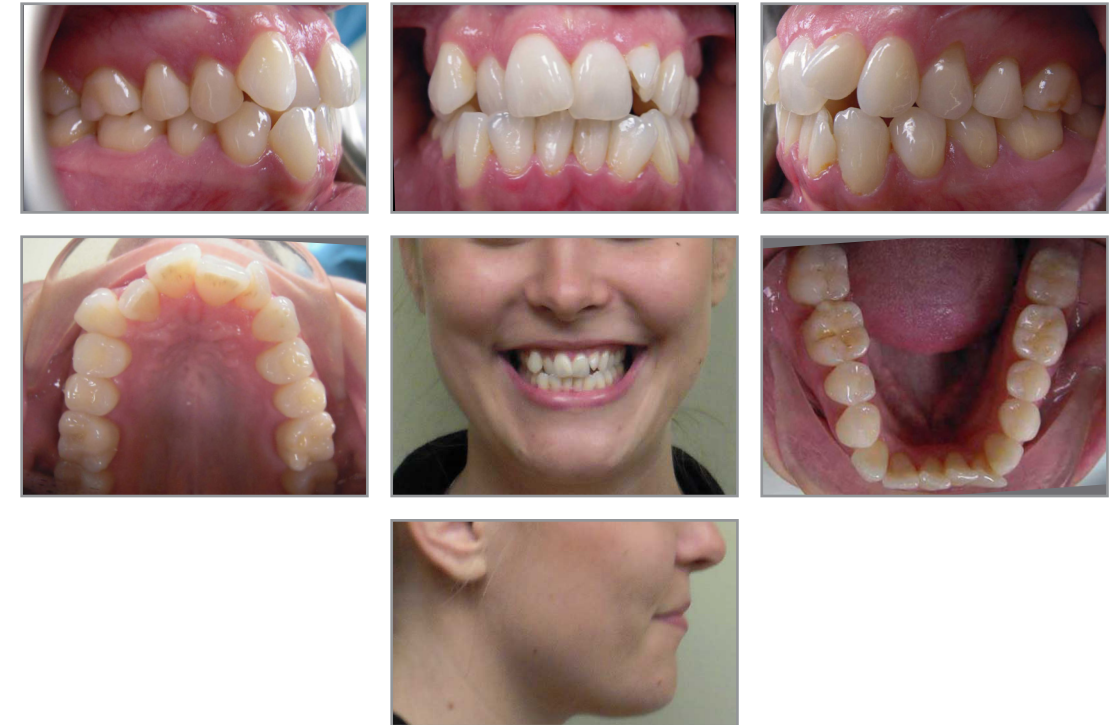Class I relationship with severe upper and lower crowding and laterals in crossbite.

LENGTH OF TREATMENT 20 months

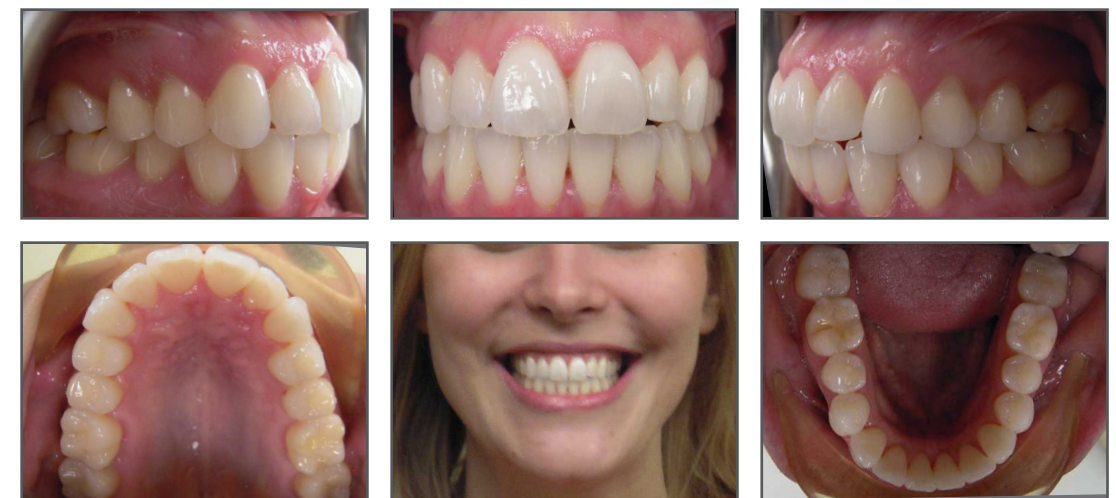OF ALIGNERS USED Upper: 26 + 15
Lower: 26 + 15

ADDITIONAL TREATMENT None

RETENTION Upper: Vivera® retainer
Lower: Vivera® retainer



BEFORE



AFTER





Dr. David Galler
Premier Dental Associates of Lower Manhattan
New York, NY

www.PremierDentalAssociates.com

TREATMENT SUMMARY

PATIENT 30-year-old male

CHIEF CONCERN The patient wanted to improve the appearance of his teeth.

DIAGNOSIS Right: Class I
Left: Class I

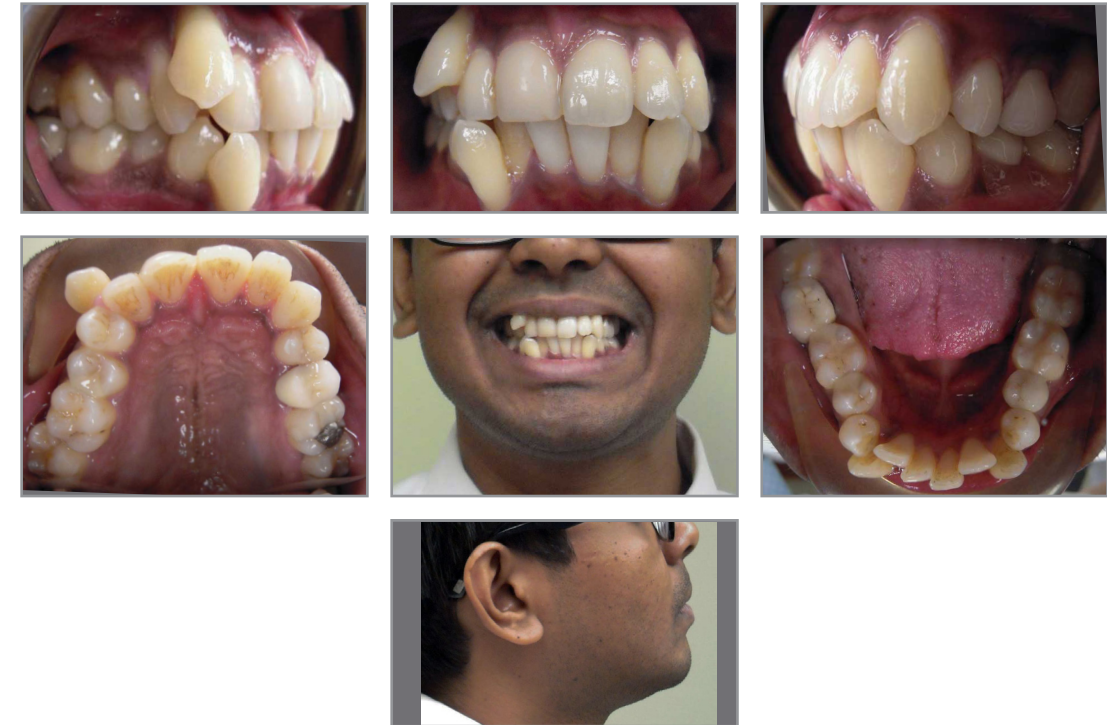Class I relationship with severe crowding in both arches. The upper and lower right canines were blocked out of the arches.

LENGTH OF TREATMENT 12 months

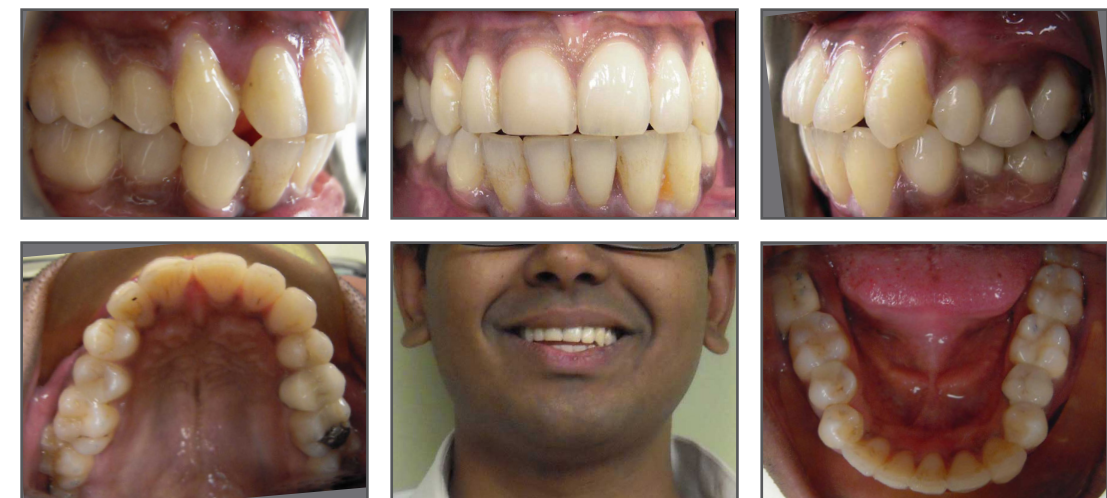OF ALIGNERS USED Upper: 21
Lower: 21

ADDITIONAL TREATMENT The upper and lower right canines were extracted.

RETENTION Upper: Vivera® retainer
Lower: Vivera® retainer



BEFORE



AFTER





Dr. David Galler
Premier Dental Associates of Lower Manhattan
New York, NY

www.PremierDentalAssociates.com

TREATMENT SUMMARY

PATIENT 21-year-old female

CHIEF CONCERN The patient did not like to smile.

DIAGNOSIS Right: Class I
Left: Class I

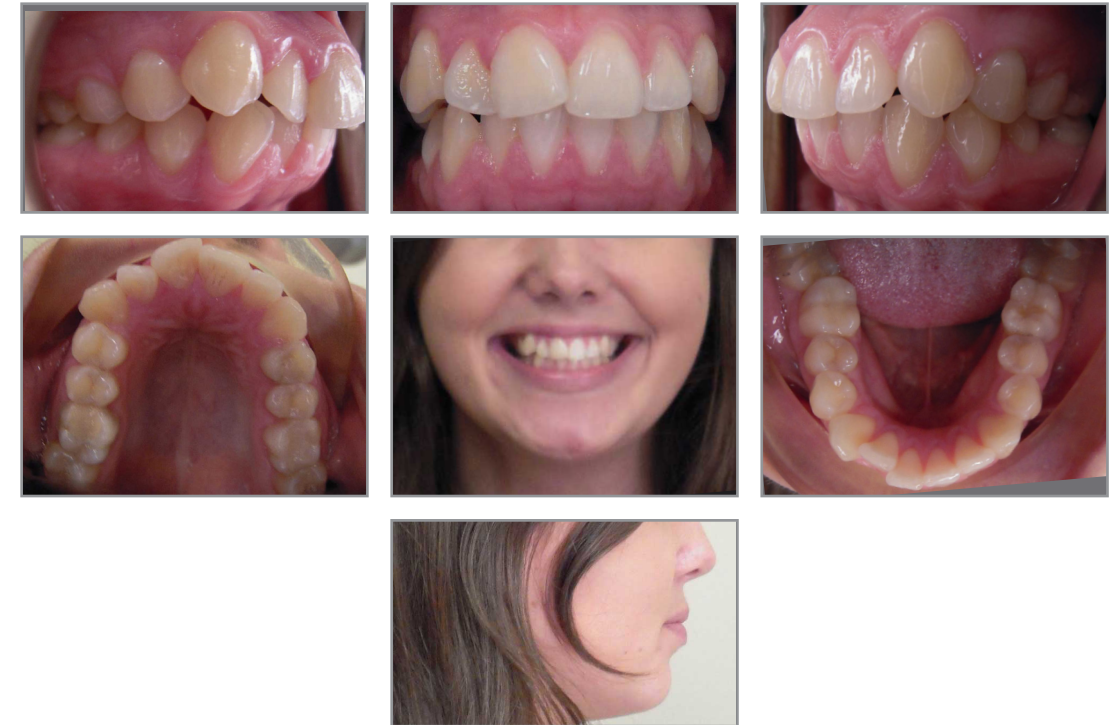Class I molar relationship with narrow arches and moderate upper and lower crowding.

LENGTH OF TREATMENT 14 months

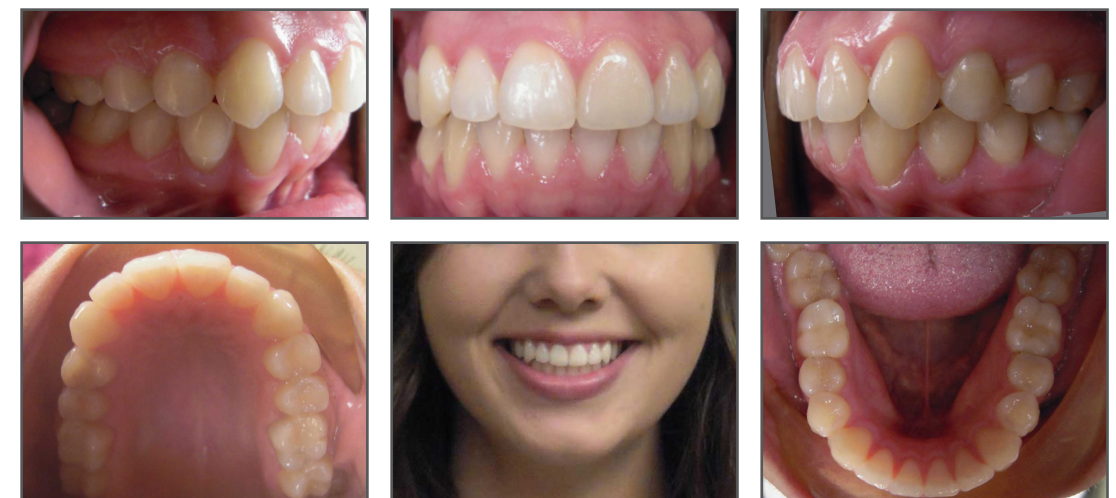OF ALIGNERS USED Upper: 20 + 4
Lower: 20 + 4

ADDITIONAL TREATMENT None

RETENTION Upper: Vivera® retainer
Lower: Vivera® retainer



BEFORE



AFTER



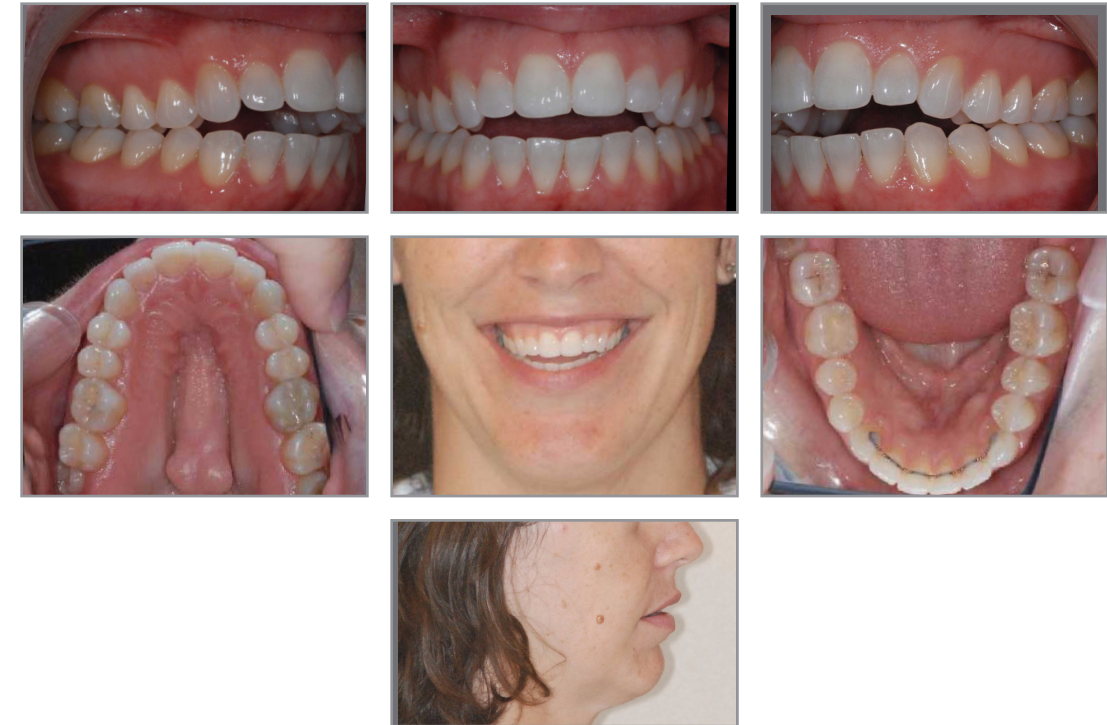

Dr. Arne Gundersen
Gundersen Dental Care
Tumwater, WA

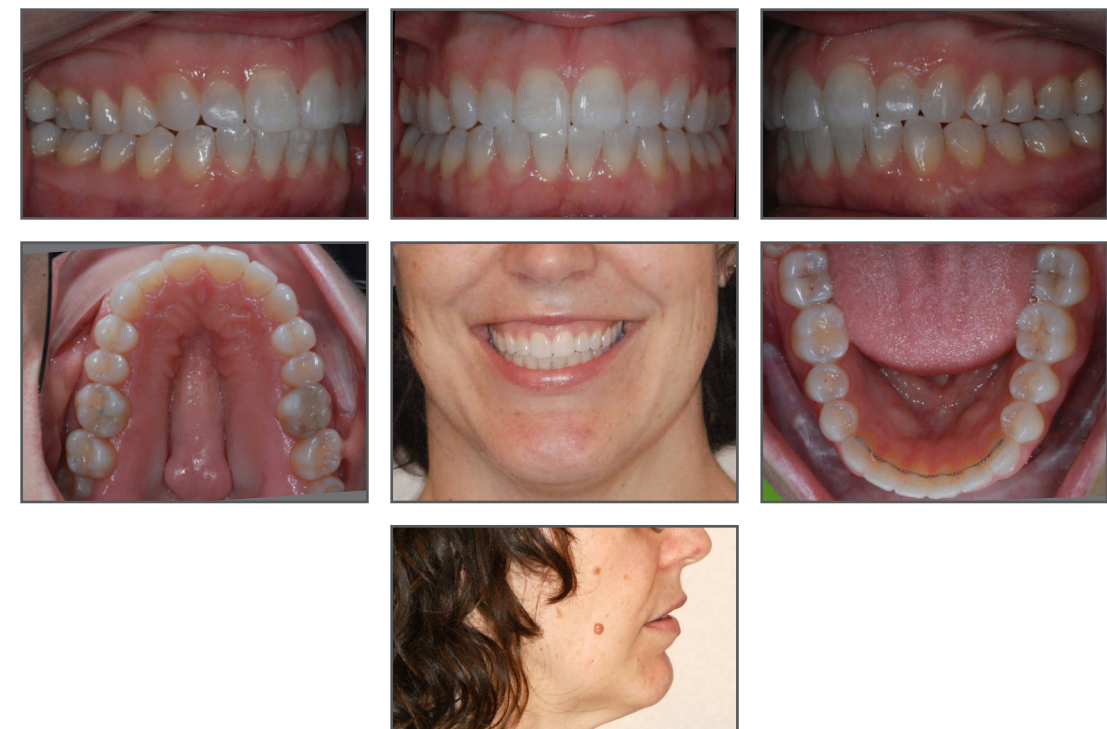www.GunderSmile.com

TREATMENT SUMMARY

PATIENT	43-year-old female
CHIEF CONCERN	The patient was concerned that she was unable to bite into food with her front teeth.
DIAGNOSIS	Right: Class II Left: Class I Class I relationship on the left side, Class II relationship on the right side, and anterior open bite.
LENGTH OF TREATMENT	24 months
# OF ALIGNERS USED	Upper: 18 + 10 + 10 + 13 Lower: 18 + 10 + 10 + 13
ADDITIONAL TREATMENT	None
RETENTION	Upper: Other clear Lower: Other clear over bonded lingual



BEFORE



AFTER



Dr. Mike Hinkle
Utica Dental
Tulsa, OK

www.UticaDental.com

TREATMENT SUMMARY

PATIENT 28-year-old male

CHIEF CONCERN The patient did not like the appearance of his teeth.

DIAGNOSIS
Right: Class III
Left: Class II

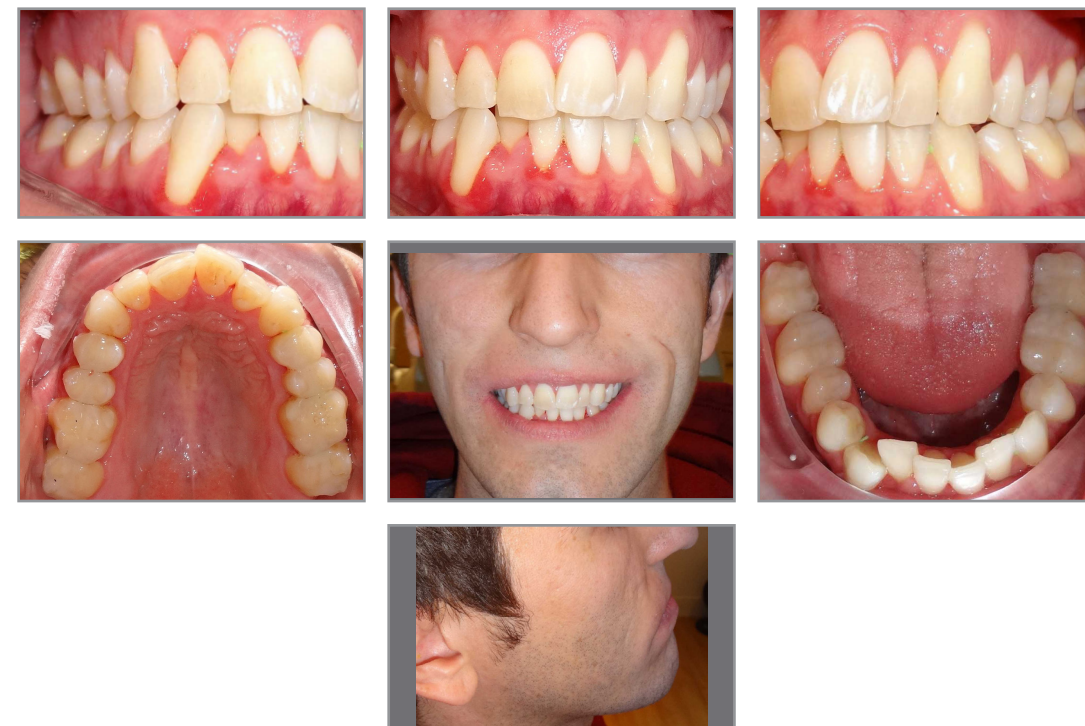Class III relationship on the right side and Class II relationship on the left side with moderate lower incisor crowding.

LENGTH OF TREATMENT 15 months

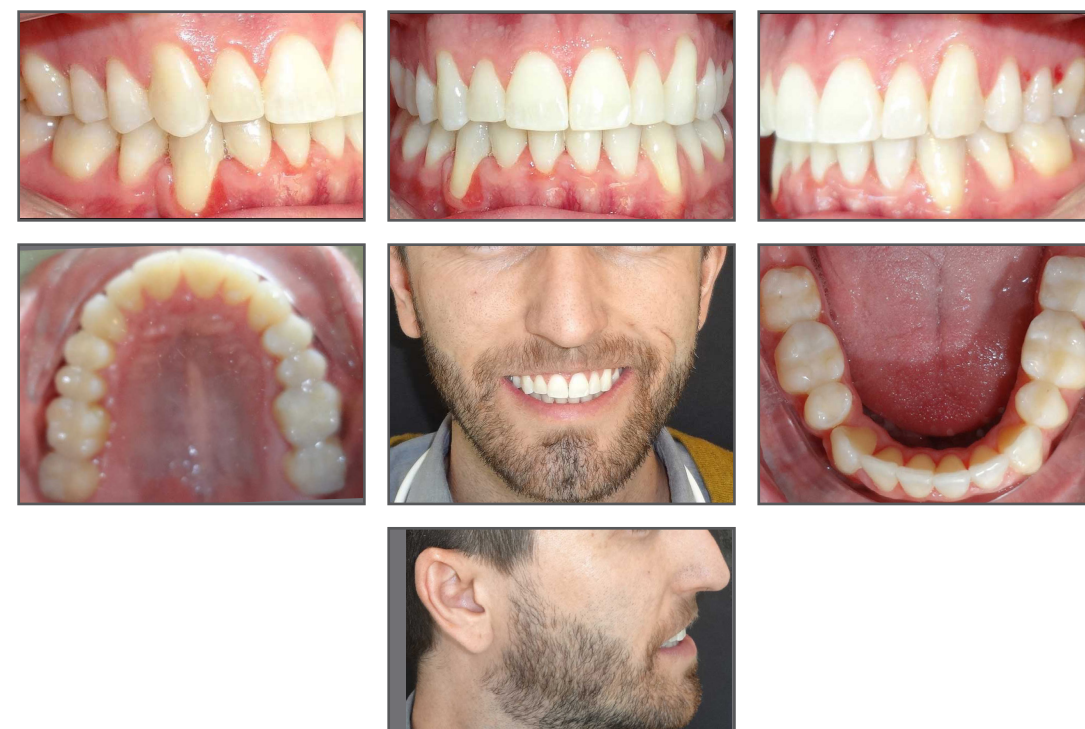OF ALIGNERS USED
Upper: 33 + 23
Lower: 33 + 23

ADDITIONAL TREATMENT None

RETENTION
Upper: Vivera® retainer
Lower: Vivera® retainer



BEFORE



AFTER



Dr. Eugene Kim
San Diego California Dental Group
San Diego, CA

www.SDDentalGroup.com

TREATMENT SUMMARY

PATIENT 33-year-old female

CHIEF CONCERN The patient was concerned about her crowded teeth.

DIAGNOSIS
Right: Class I
Left: Class II

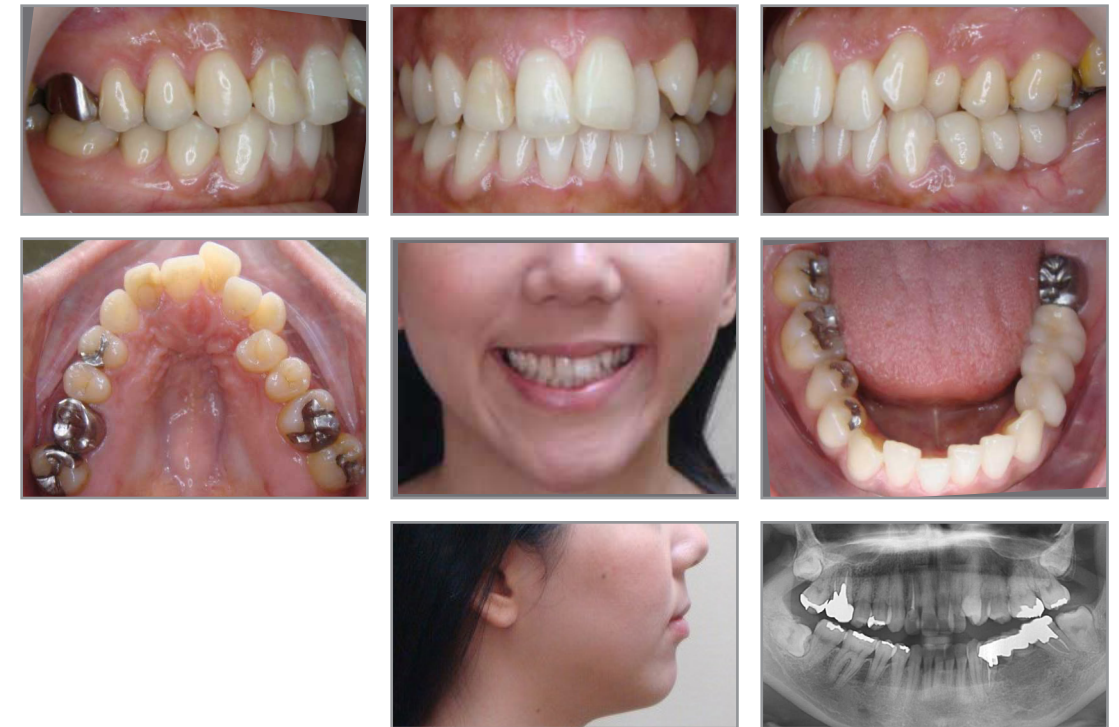Class I relationship on the right side and Class II relationship on the left side with narrow maxilla, crowding, and single tooth posterior crossbite.

LENGTH OF TREATMENT 20 months

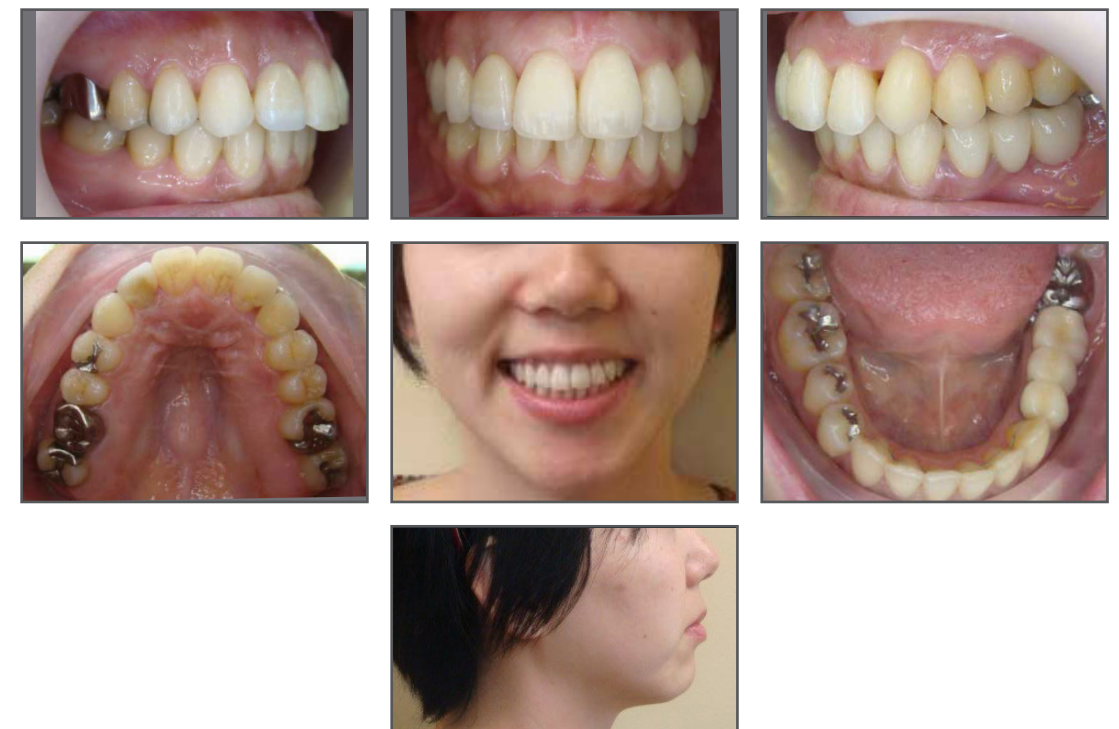OF ALIGNERS USED
Upper: 36
Lower: 36

ADDITIONAL TREATMENT None

RETENTION
Upper: Vivera® retainer
Lower: Vivera® retainer



BEFORE



AFTER



Dr. Jeremy Kurtz
Dental Arts At Lawrence
Toronto, ON, Canada

www.DentalArtsAtLawrence.com

TREATMENT SUMMARY

PATIENT 42-year-old female

CHIEF CONCERN The patient did not like to smile because of her crowded teeth.

DIAGNOSIS Right: Class I
Left: Class II

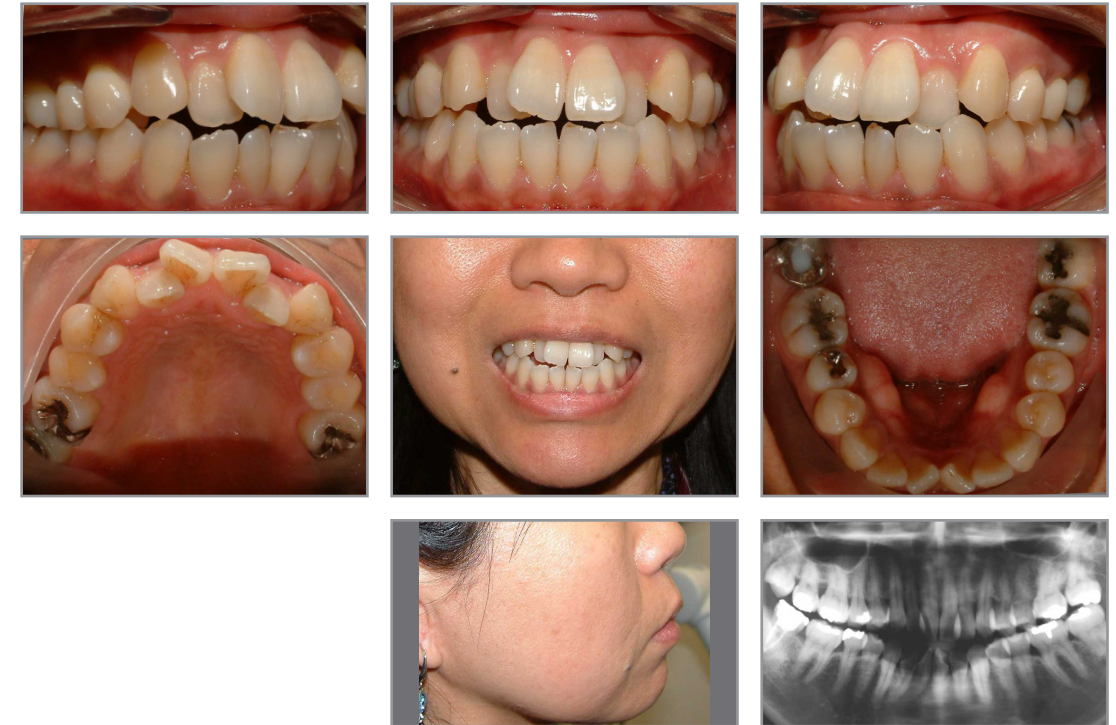Class II relationship on the left side and Class I relationship on the right side with severe crowding, anterior open bite with upper laterals in crossbite, and flared central incisors.

LENGTH OF TREATMENT 15 months

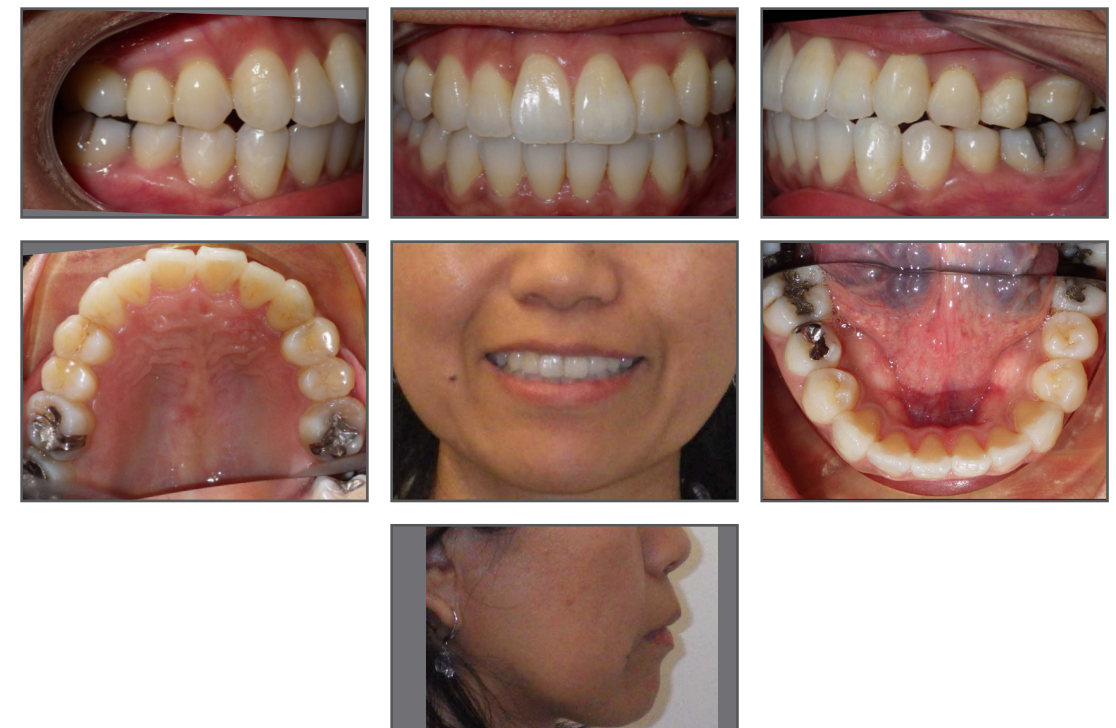OF ALIGNERS USED Upper: 31 + 5
Lower: 31 + 5

ADDITIONAL TREATMENT None

RETENTION Upper: Vivera® retainer
Lower: Vivera® retainer



BEFORE



AFTER



Dr. Jeremy Kurtz
Dental Arts At Lawrence
Toronto, ON, Canada

www.DentalArtsAtLawrence.com

TREATMENT SUMMARY

PATIENT 13-year-old female

CHIEF CONCERN The patient was concerned about her crowded teeth but did not want to have any teeth extracted.

DIAGNOSIS Right: Class I
Left: Class I

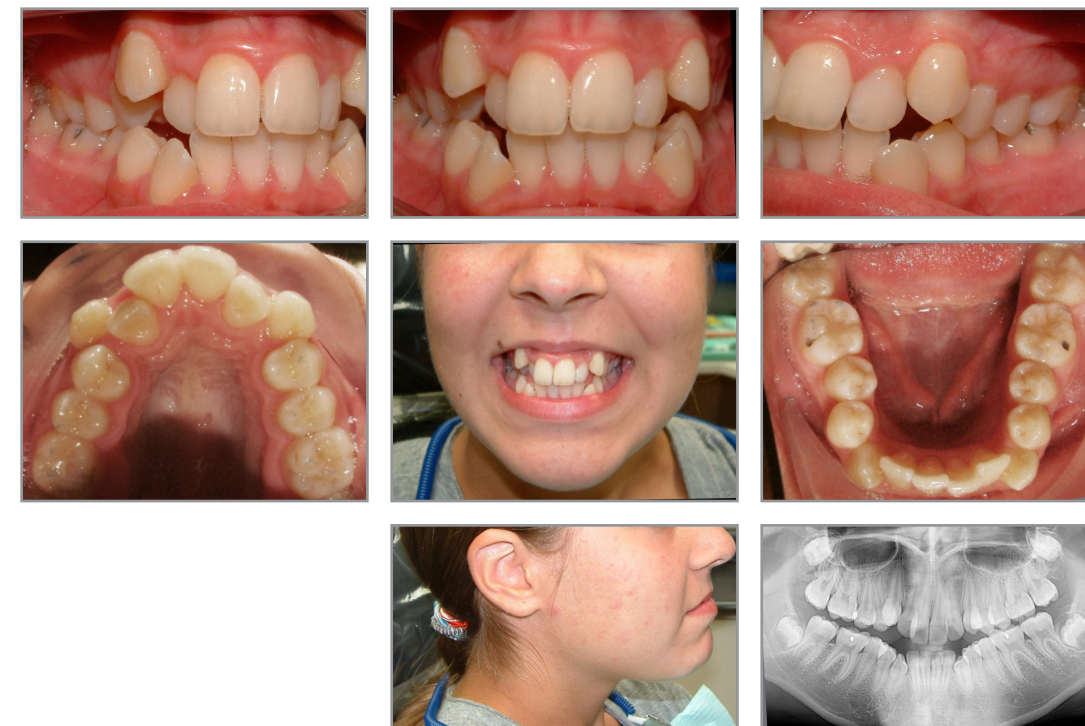Class I molar relationship with severe crowding in both arches, narrow arches, the upper canines were blocked out of the arch, and the upper lateral incisors were in crossbite.

LENGTH OF TREATMENT 24 months

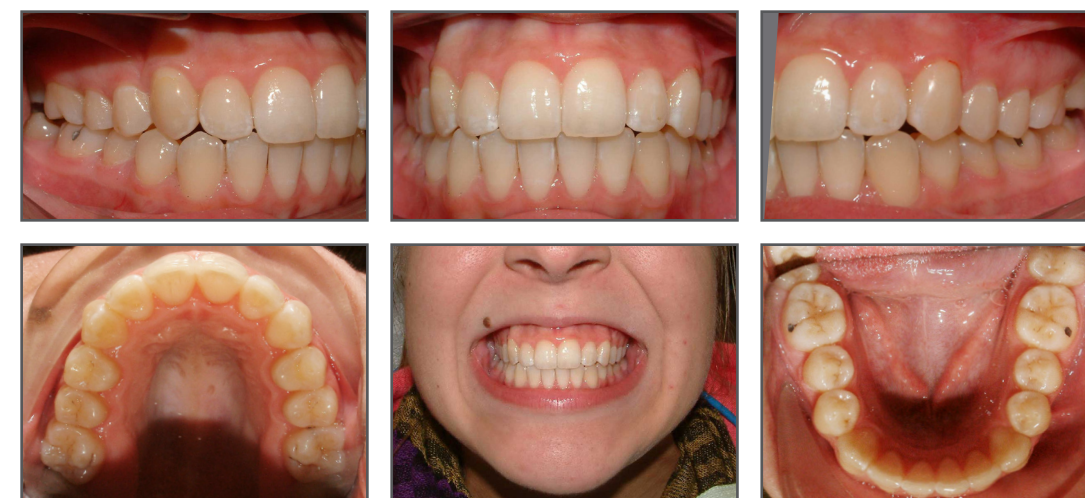OF ALIGNERS USED Upper: 38 + 12
Lower: 20 + 12

ADDITIONAL TREATMENT To aid in moving the upper canines into the arch, elastics were used during the initial 38 upper aligner stages, with ceramic buttons bonded to the upper canines and hooks cut into the aligners near the lower first bicuspid.

RETENTION Upper: Vivera® retainer
Lower: Vivera® retainer



BEFORE



AFTER





Dr. Yu Li
City Centre Dental Clinic
Surrey, BC, Canada

www.facebook.com/dryuli

TREATMENT SUMMARY

PATIENT 25-year-old female

CHIEF CONCERN The patient was concerned about her crooked teeth.

DIAGNOSIS
Right: Class I
Left: Class II

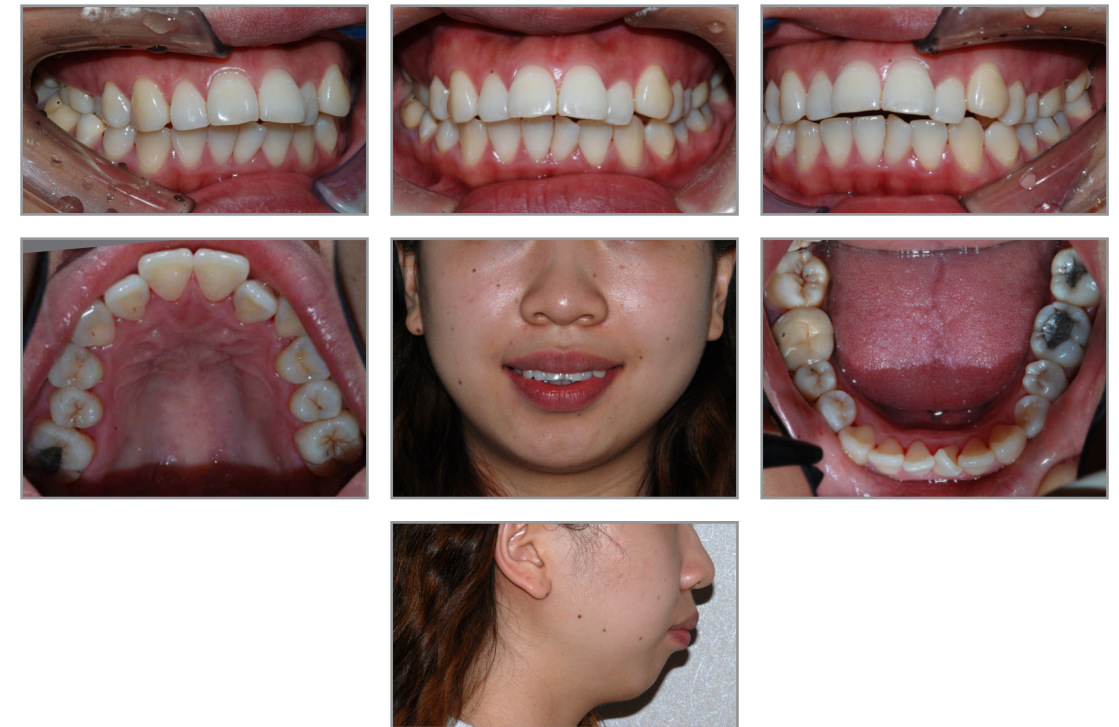Class II relationship on the left side, Class I tendency on the right side with upper and lower anterior crowding and anterior open bite.

LENGTH OF TREATMENT 28 months

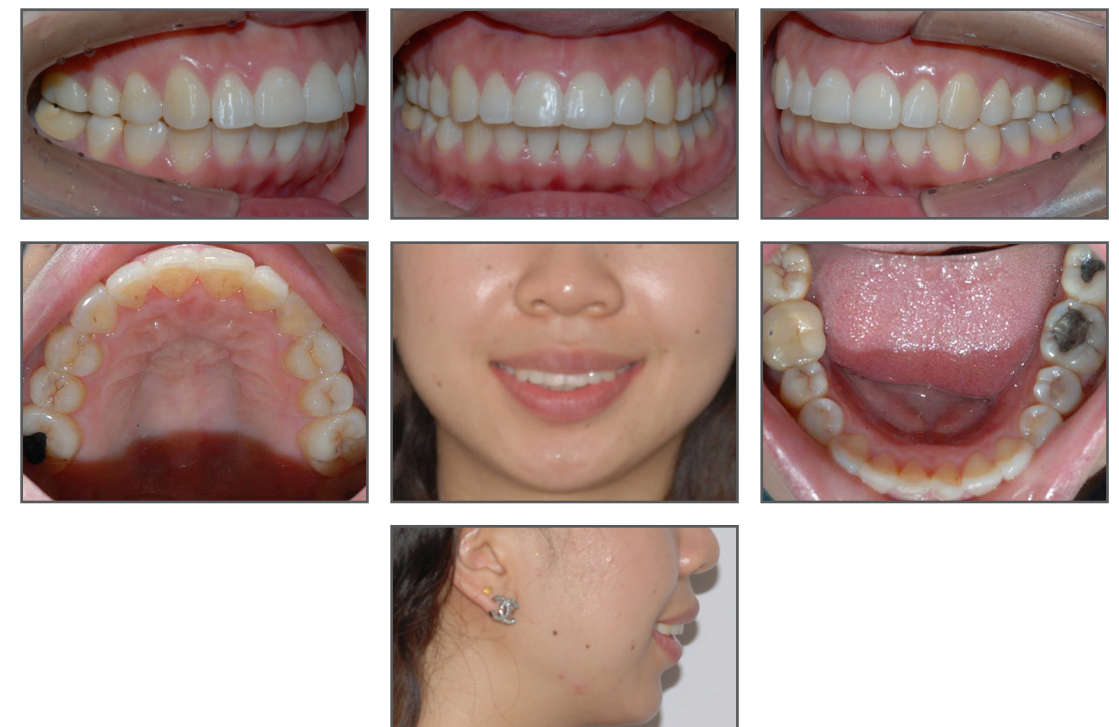OF ALIGNERS USED
Upper: 28 + 22
Lower: 28 + 10

ADDITIONAL TREATMENT None

RETENTION
Upper: Vivera® retainer
Lower: Vivera® retainer



BEFORE



AFTER



Dr. Yu Li
City Centre Dental Clinic
Surrey, BC, Canada

www.facebook.com/dryuli

TREATMENT SUMMARY

PATIENT 20-year-old female

CHIEF CONCERN The patient was concerned about her crooked teeth.

DIAGNOSIS Right: Class I
Left: Class II

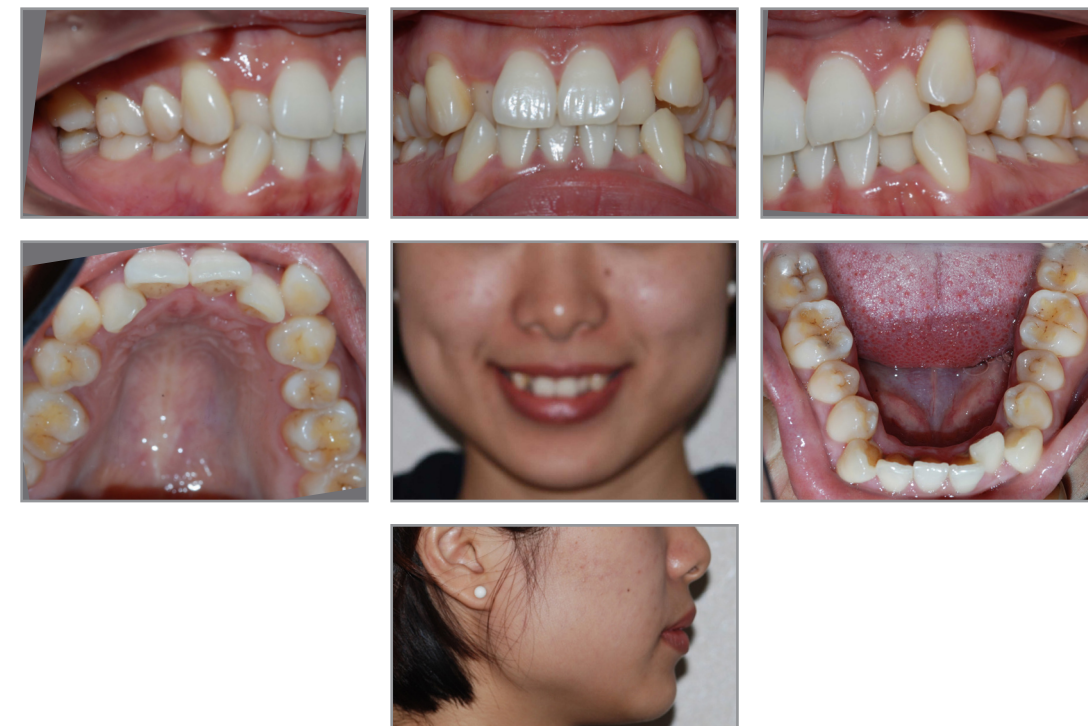Class I relationship right side, end-on Class II relationship left side, with severe crowding and upper lateral incisors in crossbite.

LENGTH OF TREATMENT 16 months

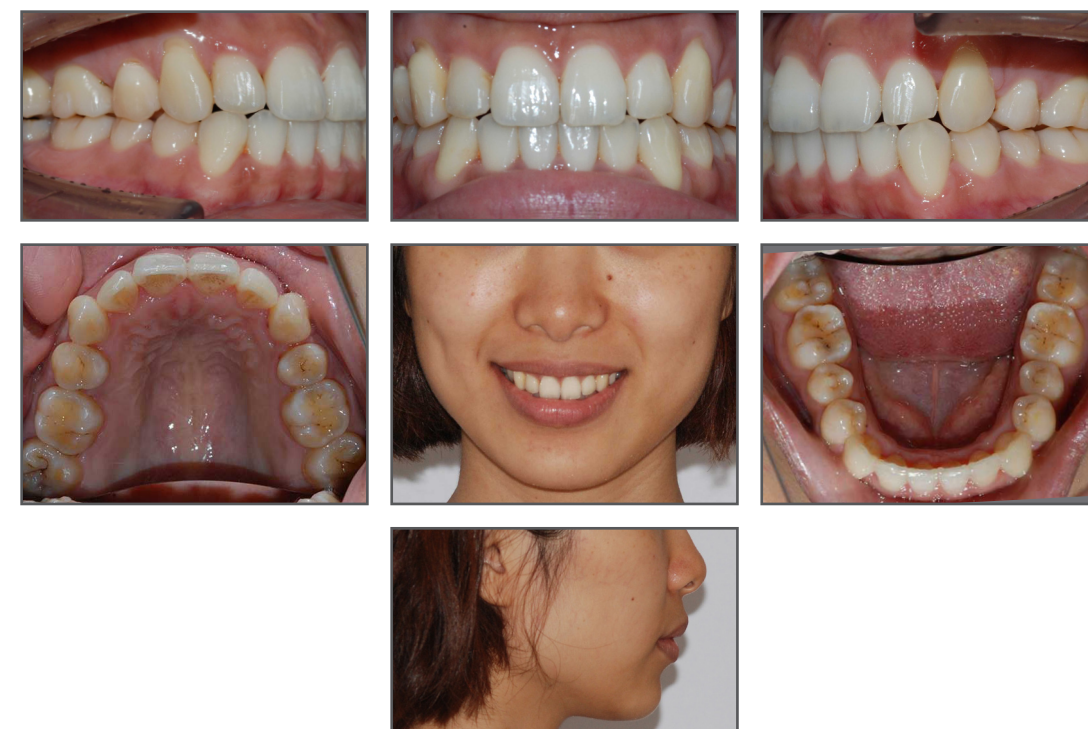OF ALIGNERS USED Upper: 32
Lower: 32

ADDITIONAL TREATMENT None

RETENTION Upper: Vivera® retainer
Lower: Vivera® retainer



BEFORE



AFTER



Dr. Yu Li
City Centre Dental Clinic
Surrey, BC, Canada

www.facebook.com/dryuli

TREATMENT SUMMARY

PATIENT 32-year-old female

CHIEF CONCERN The patient was concerned about her crooked teeth.

DIAGNOSIS Right: Class II
Left: Class II

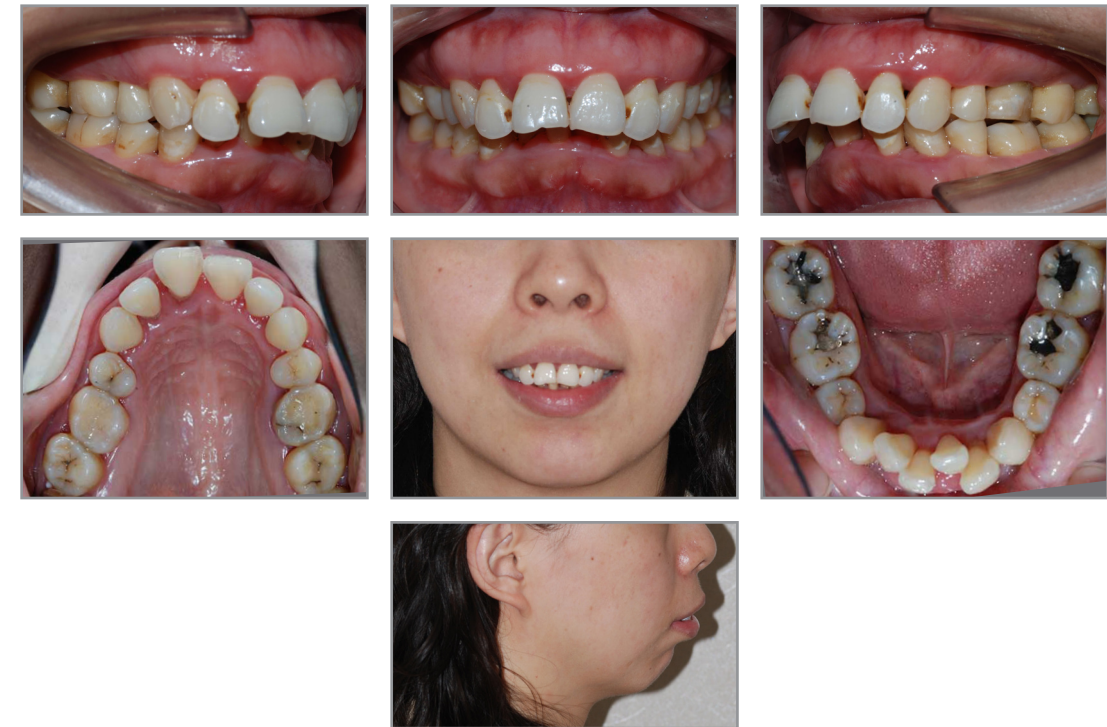Class II relationship with severe deep bite and excessive overjet.

LENGTH OF TREATMENT 12 months

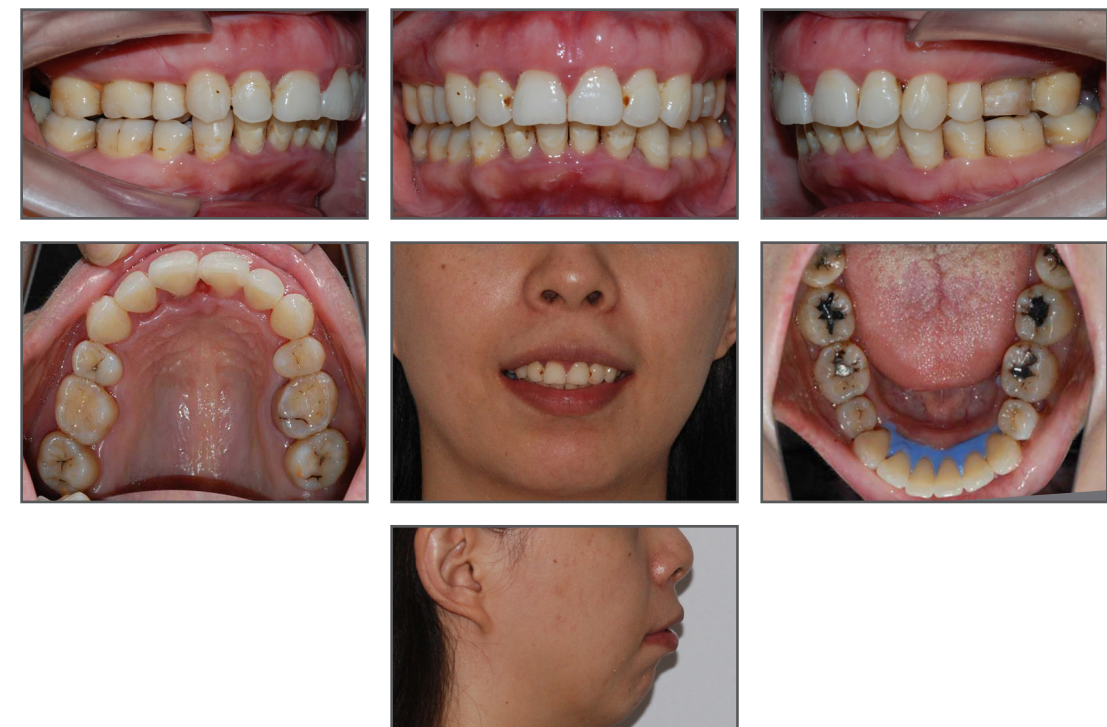OF ALIGNERS USED Upper: 25
Lower: 25

ADDITIONAL TREATMENT None

RETENTION Upper: Vivera® retainer
Lower: Vivera® retainer



BEFORE



AFTER



Dr. Steven London
London Dental Group
Boca Raton, FL

www.StevenLondonDDS.com

TREATMENT SUMMARY

PATIENT 32-year-old male

CHIEF CONCERN The patient wanted to improve his smile and straighten his teeth.

DIAGNOSIS Right: Class I
Left: Class I

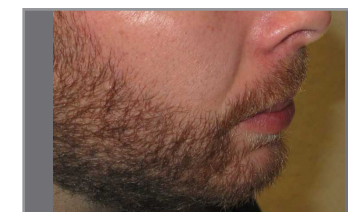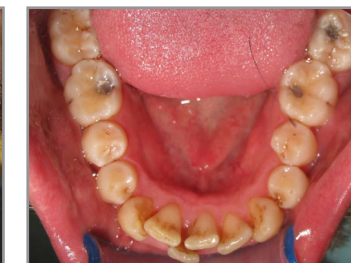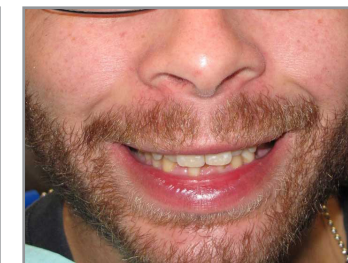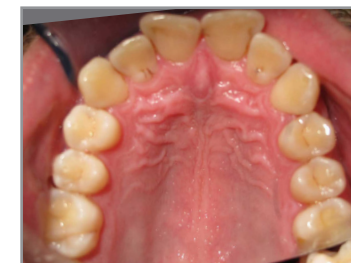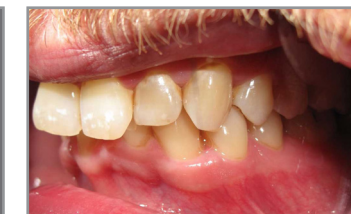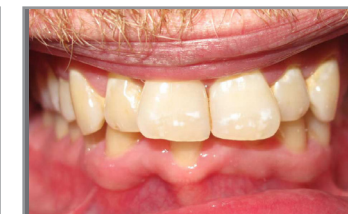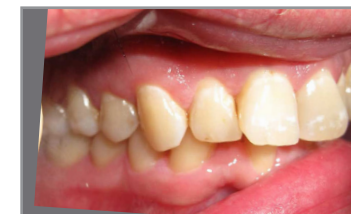Class I relationship, deep bite, moderate upper crowding, and severe lower crowding with the lower right central incisor blocked out of the arch.

LENGTH OF TREATMENT 16 months

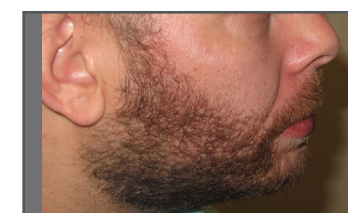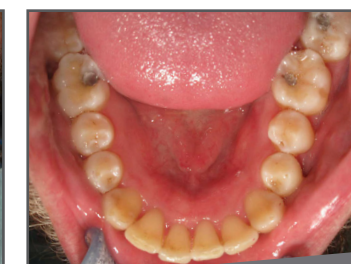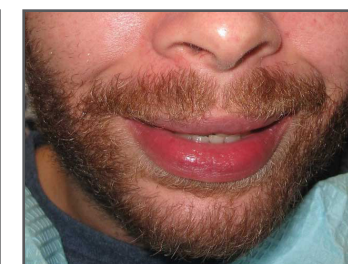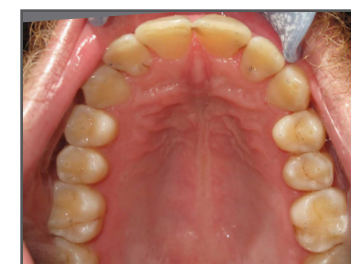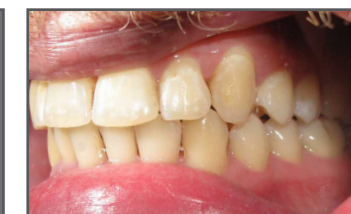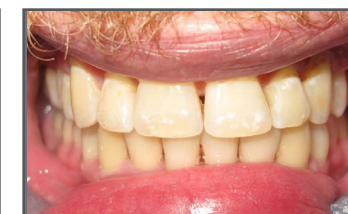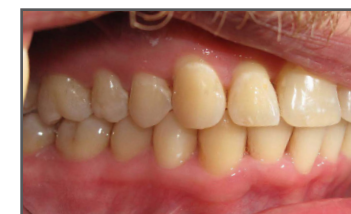OF ALIGNERS USED Upper: 23 + 13
Lower: 23 + 13

ADDITIONAL TREATMENT All caries restorations were completed prior to Invisalign®.

RETENTION Upper: Vivera® retainer
Lower: Vivera® retainer



BEFORE



AFTER



Dr. Steven London
London Dental Group
Boca Raton, FL

www.StevenLondonDDS.com

TREATMENT SUMMARY

PATIENT 24-year-old male

CHIEF CONCERN The patient wanted to fix his bite and make his teeth look better.

DIAGNOSIS Right: Class I
Left: Class I

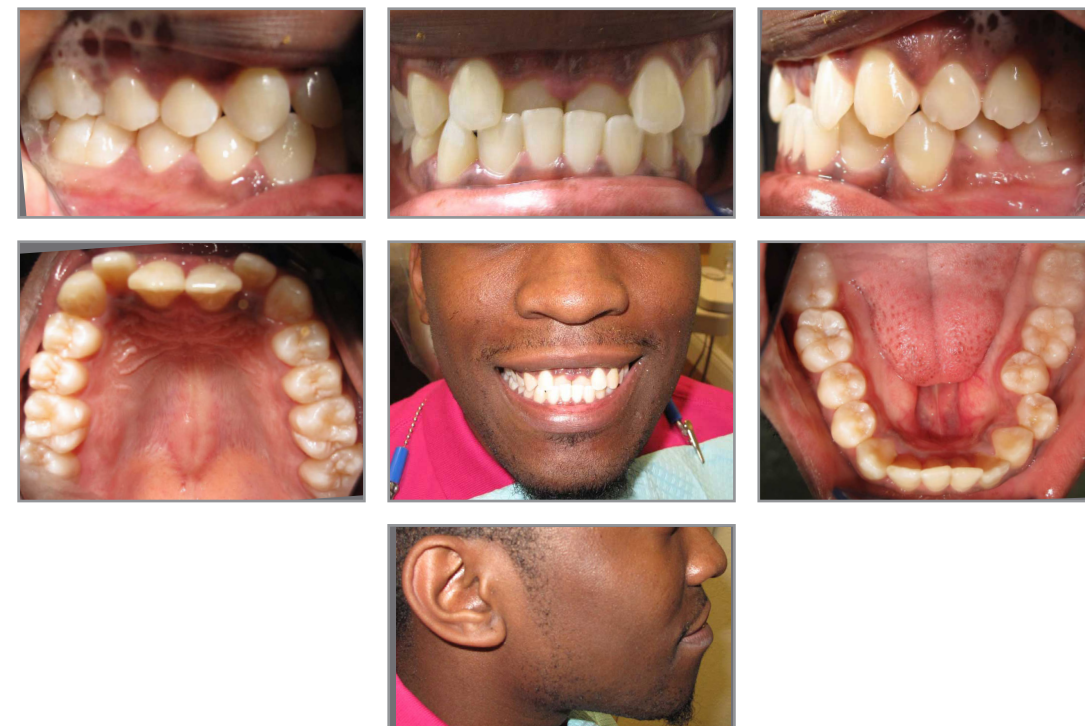Class I molars and canines with Class III tendency, anterior crossbite, and severe crowding.

LENGTH OF TREATMENT 22 months

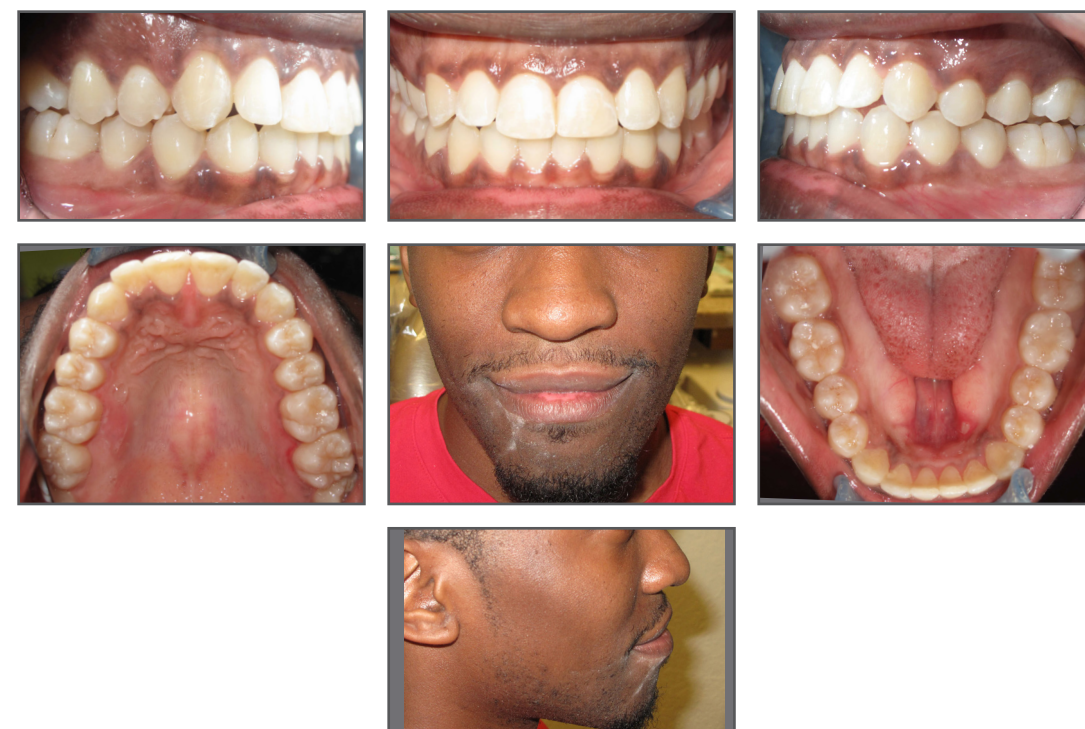OF ALIGNERS USED Upper: 26 + 17
Lower: 26 + 17

ADDITIONAL TREATMENT None

RETENTION Upper: Vivera® retainer
Lower: Vivera® retainer



BEFORE



AFTER

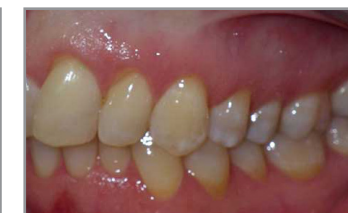
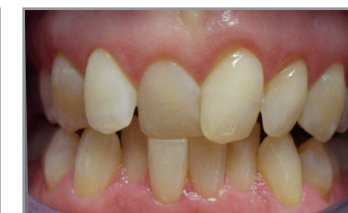
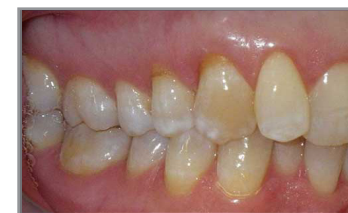Dr. Debbie Mulroy
All West Dental
Lethbridge, AB, Canada

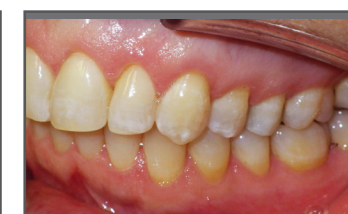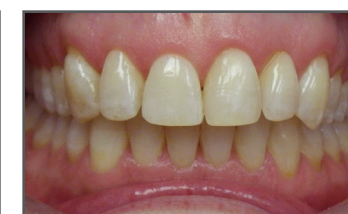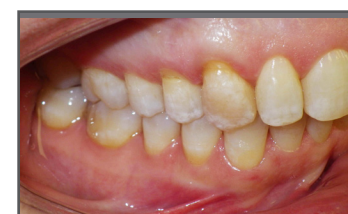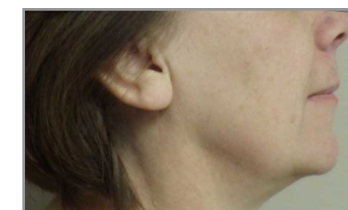
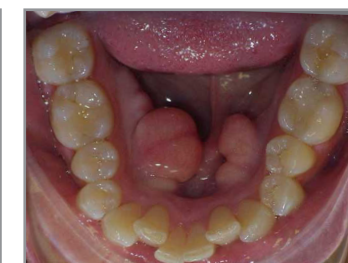
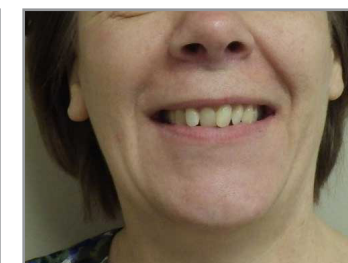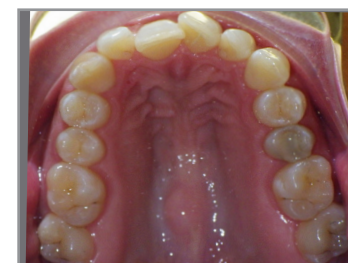www.AllWestDental.com

TREATMENT SUMMARY

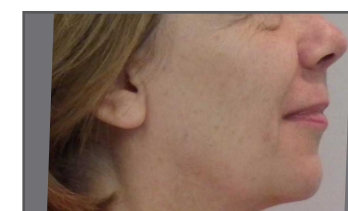
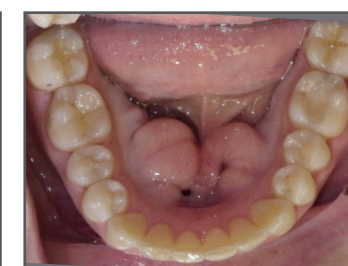
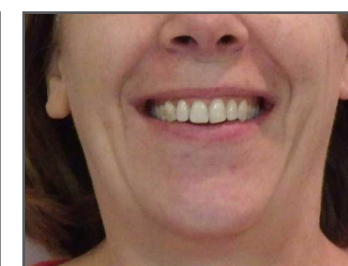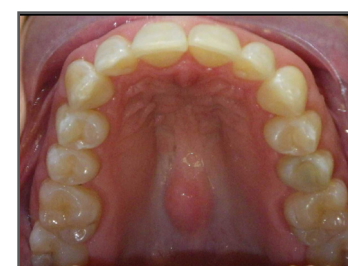
PATIENT	56-year-old female
CHIEF CONCERN	The patient did not like to smile.
DIAGNOSIS	Right: Class I Left: Class I Class I molar relationship with severe crowding and deep bite.
LENGTH OF TREATMENT	21 months
# OF ALIGNERS USED	Upper: 25 + 3 + 9 Lower: 19 + 2 + 0
ADDITIONAL TREATMENT	None
RETENTION	Upper: Vivera® retainer Lower: Vivera® retainer



BEFORE



AFTER





Dr. Daniel Noor
Smile Café
New York, NY

www.SmileCafeNY.com

TREATMENT SUMMARY

PATIENT 34-year-old male

CHIEF CONCERN The patient did not like his underbite, and was unable to bite into food. He was also concerned about bleeding gums and TMJ issues, but wanted to avoid surgery.

DIAGNOSIS Right: Class III
Left: Class III

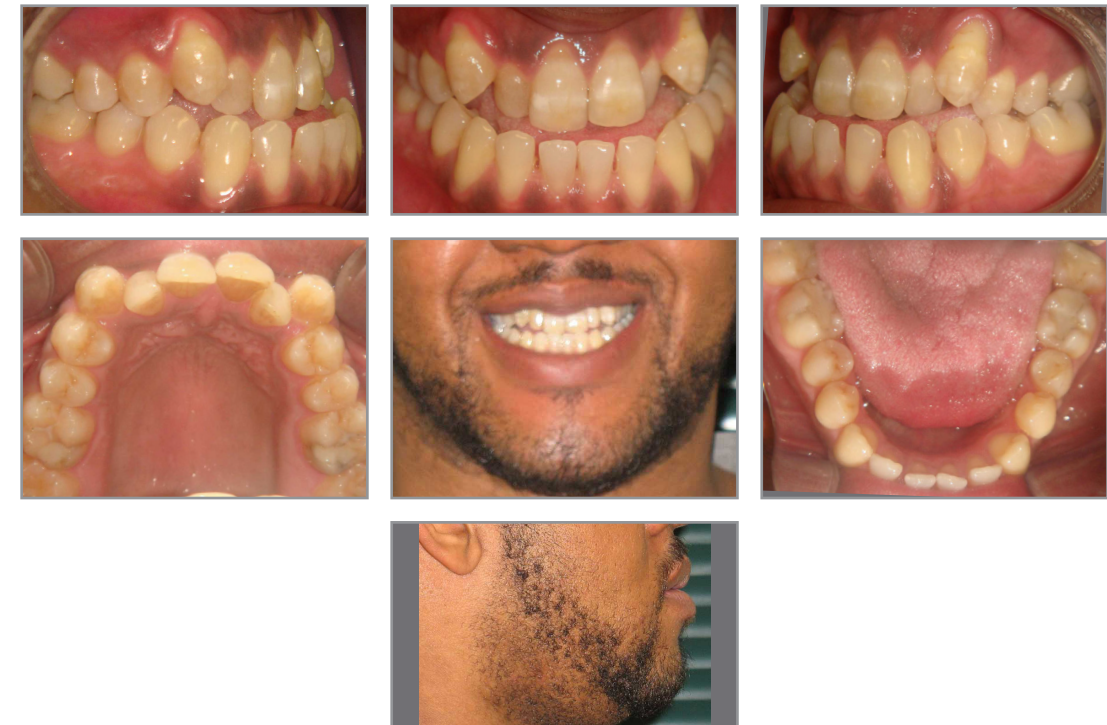Class III relationship with 5 mm negative overjet, anterior crossbite, retruded maxilla, protruded mandible, severe upper crowding with canines blocked out of the arch, and lower spacing.

LENGTH OF TREATMENT 33 months

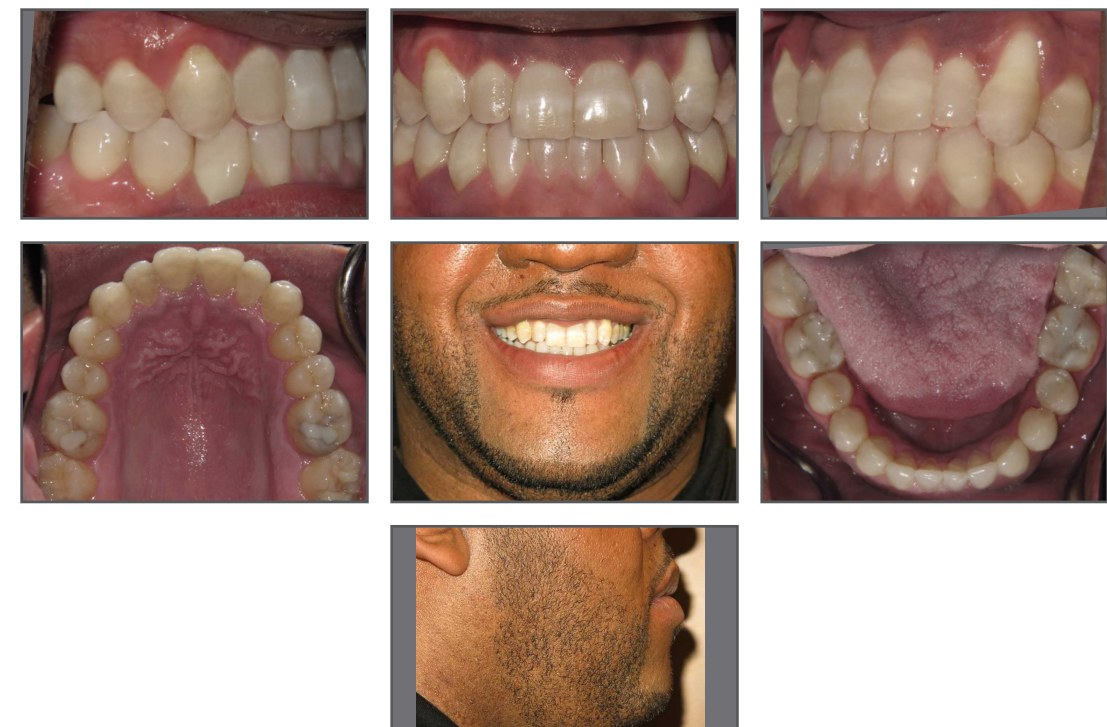OF ALIGNERS USED Upper: 36 + 31 + 28
Lower: 36 + 31 + 28

ADDITIONAL TREATMENT Class III elastics were used with buttons bonded to the upper first molars and lower canines. Detailing pliers were used as needed.

RETENTION Upper: Other clear
Lower: Other clear



BEFORE



AFTER



Dr. Daniel Noor
Smile Café
New York, NY

www.SmileCafeNY.com

TREATMENT SUMMARY

PATIENT 23-year-old female

CHIEF CONCERN The patient was unhappy with her facial discrepancies, bite problems, pain, and lack of self-confidence. She wanted to fix her bite and make her jaw look better.

DIAGNOSIS Right: Class I
Left: Class I

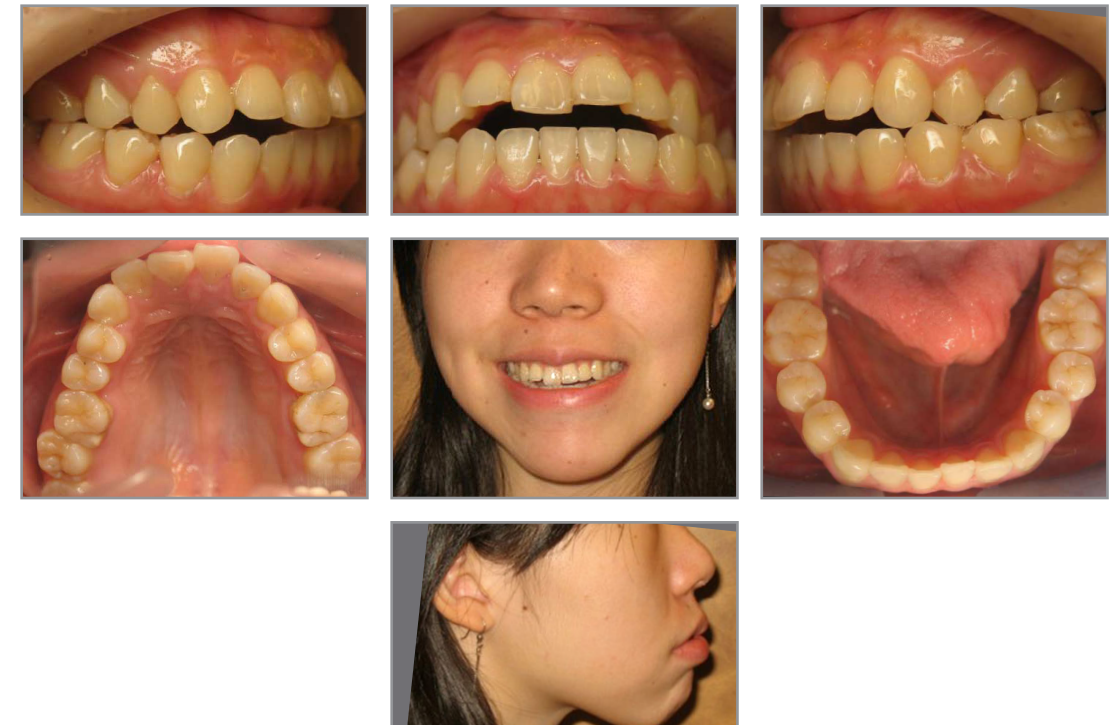Class I relationship with severe skeletal and facial asymmetry, anterior open bite, and posterior crossbite.

LENGTH OF TREATMENT 31 months

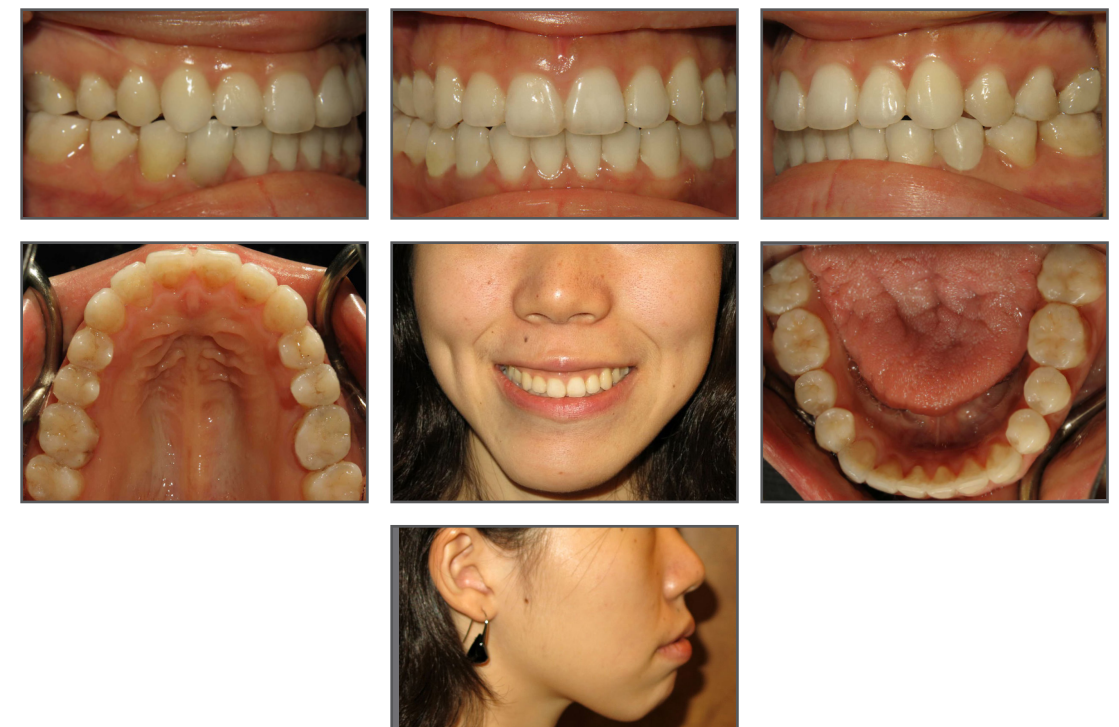OF ALIGNERS USED Upper: 38 + 27
Lower: 38 + 27

ADDITIONAL TREATMENT Elastics were used for the duration of treatment with buttons bonded to the upper first molar and lower canine on the right side, and buttons bonded to the upper first molar and lower first bicuspid on the left side. Detailing pliers were used as needed.

RETENTION Upper: Other clear
Lower: Other clear



BEFORE



AFTER



Dr. Daniel Noor
Smile Café
New York, NY

www.SmileCafeNY.com

TREATMENT SUMMARY

PATIENT 21-year-old female

CHIEF CONCERN The patient was concerned about her crowded teeth, as well as the discomfort and cost of treatment.

DIAGNOSIS
Right: Class III
Left: Class III

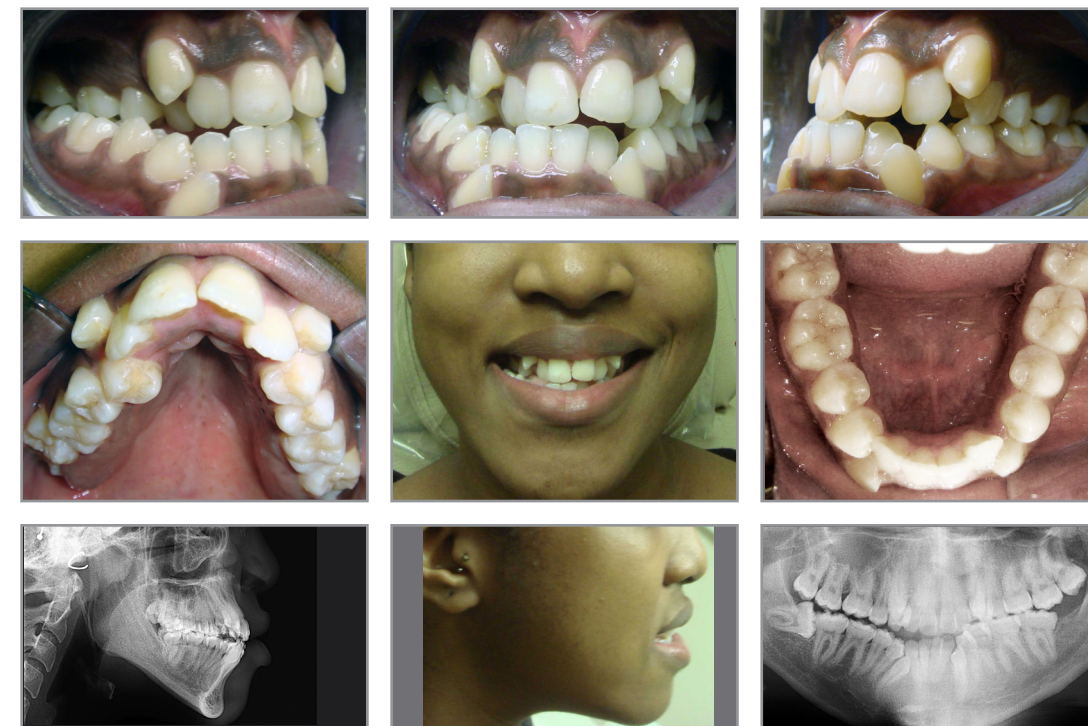
Class III relationship with 7 mm midline shift, severe crowding, anterior open bite and crossbite, and all canines blocked out of the arches.

LENGTH OF TREATMENT 29 months

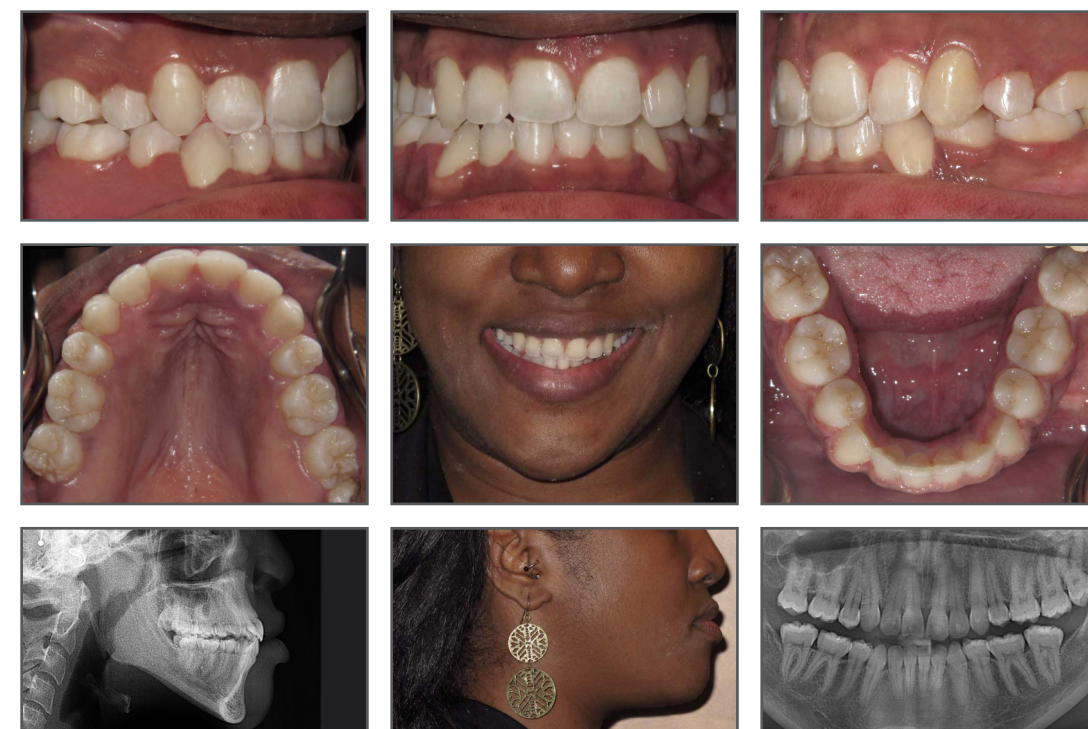
OF ALIGNERS USED
Upper: 58
Lower: 49

ADDITIONAL TREATMENT Elastics were used full-time for the duration of treatment, with buttons bonded to all canines and the upper second molars. The patient wore 1/4" clear elastics from her upper to lower canines, from the upper left second molar to the lower left canine, and from the upper right second molar to the lower right canine.

RETENTION
Upper: Other clear
Lower: Other clear



BEFORE



AFTER

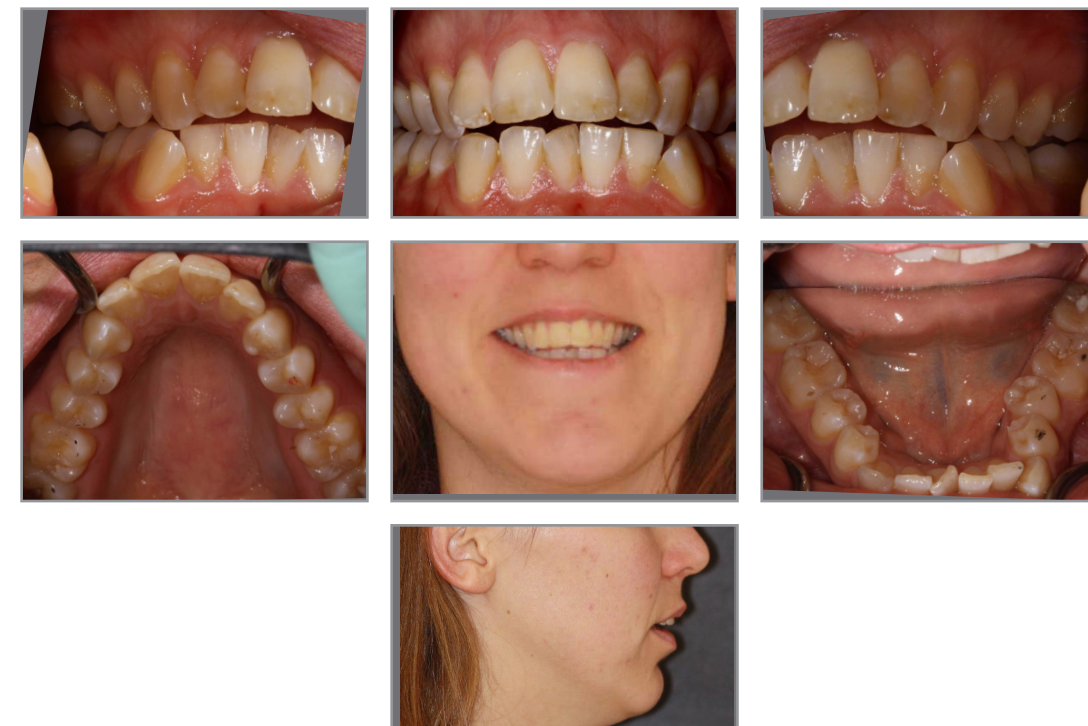

Dr. Brian Orcutt
Orcutt Family Dentistry
Fair Oaks, CA

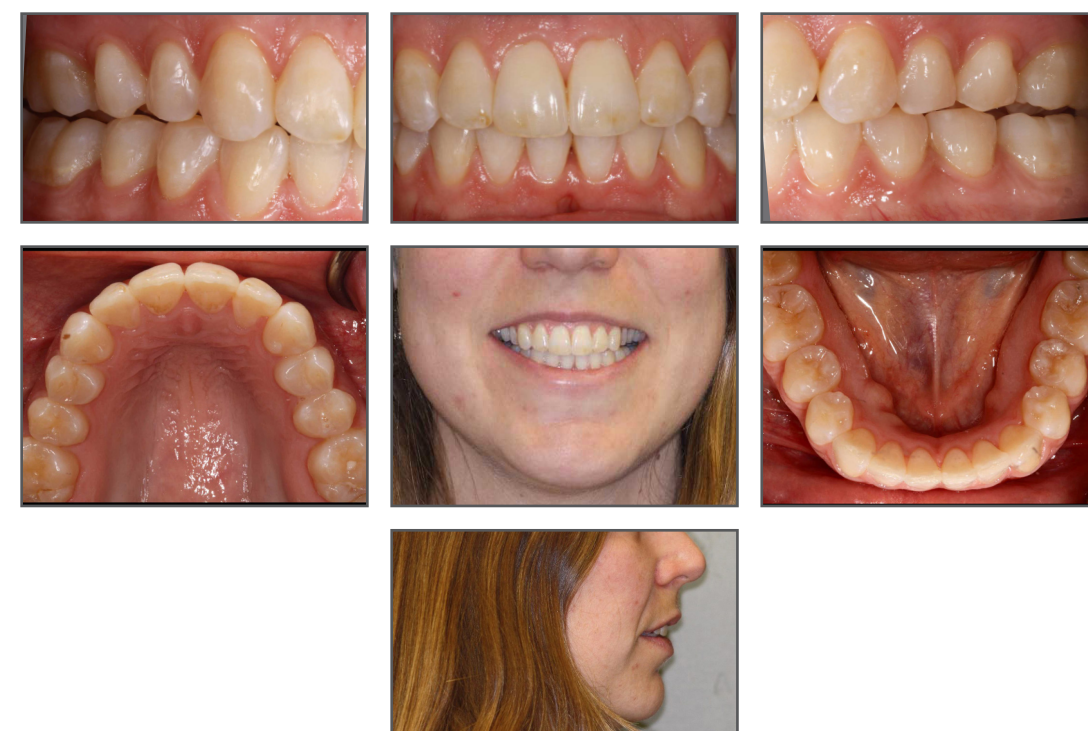www.FairOaksClearBraces.com

TREATMENT SUMMARY

PATIENT	33-year-old female
CHIEF CONCERN	The patient was concerned about her overbite and wanted a nice smile.
DIAGNOSIS	Right: Class II Left: Class II Division 1 malocclusion with moderate overjet and anterior open bite.
LENGTH OF TREATMENT	24 months
# OF ALIGNERS USED	Upper: 22 + 22 Lower: 22 + 22
ADDITIONAL TREATMENT	None
RETENTION	Upper: Vivera® retainer Lower: Vivera® retainer



BEFORE



AFTER



Dr. Bruno Paliani
Paliani Dentistry, PC
London, ON, Canada

www.SmileDentist.com

TREATMENT SUMMARY

PATIENT 19-year-old female

CHIEF CONCERN The patient was concerned about her crowded teeth, especially with the anterior teeth. The upper canines were blocked out and not fully erupted, and she had a "gummy" smile.

DIAGNOSIS Right: Class II
Left: Class II

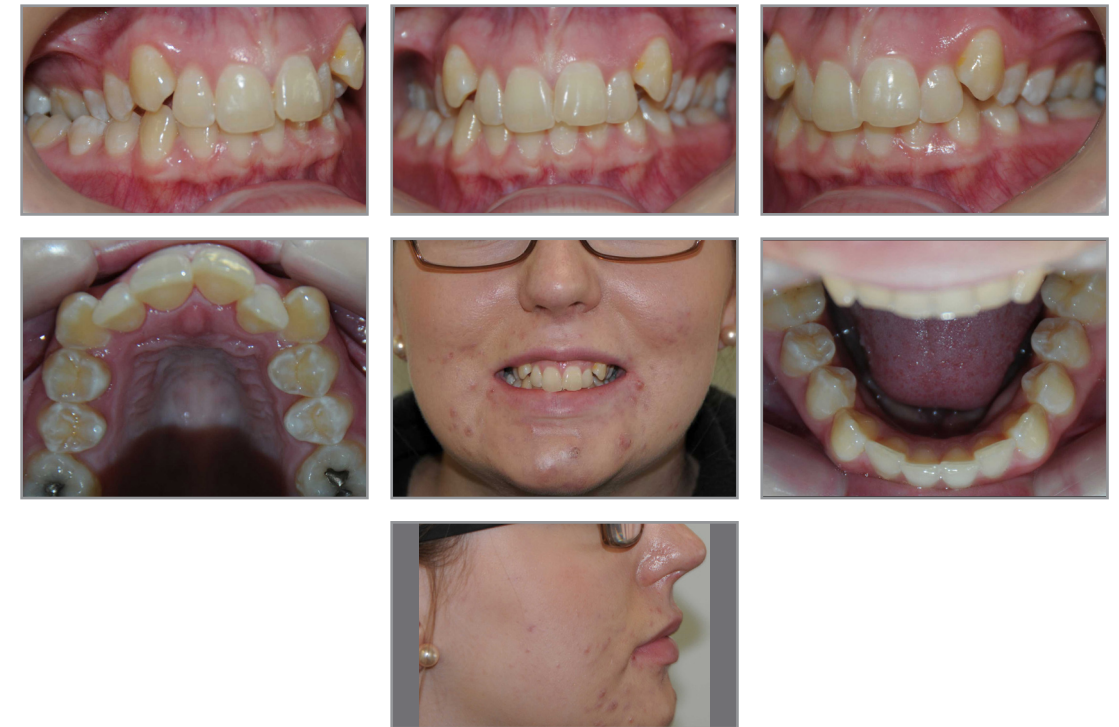Class II relationship with narrow arches, moderate to severe crowding, posterior crossbite on the right side, lower midline deviated 2.5 mm to the right, 30-50% overbite, and 3-5 mm overjet.

LENGTH OF TREATMENT 17 months

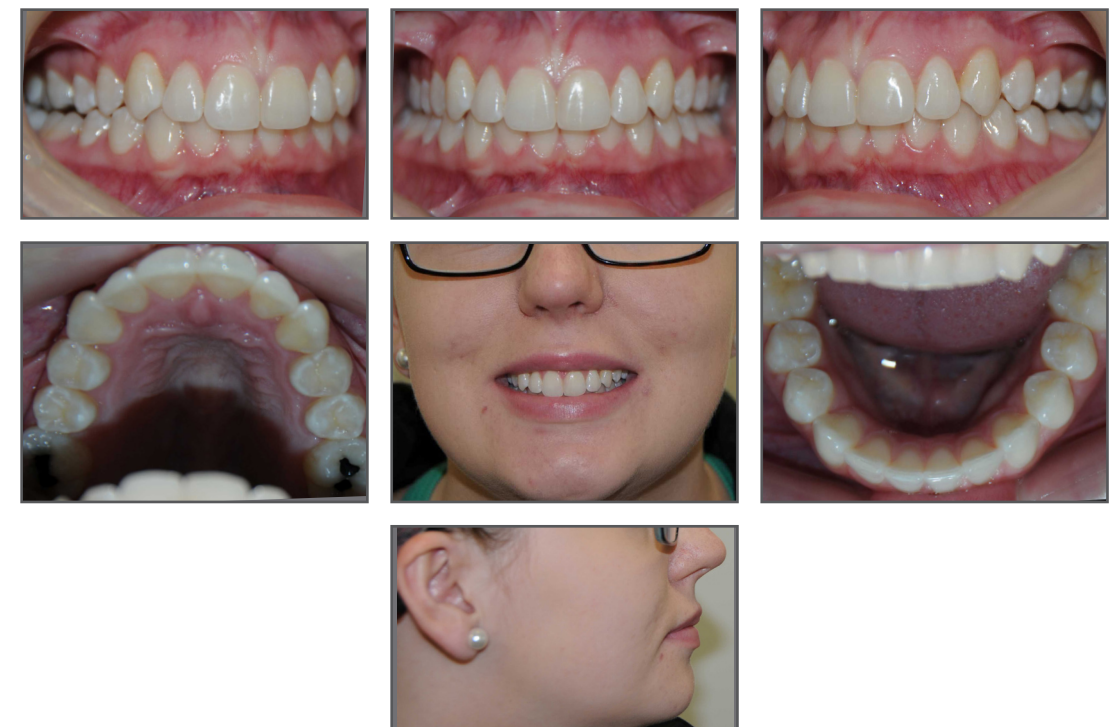OF ALIGNERS USED Upper: 22 + 11
Lower: 22 + 14

ADDITIONAL TREATMENT None

RETENTION Upper: Invisalign® retainer
Lower: Invisalign® retainer



BEFORE



AFTER



Dr. Bruno Paliani
Paliani Dentistry, PC
London, ON, Canada

www.SmileDentist.com

TREATMENT SUMMARY

PATIENT 13-year-old male

CHIEF CONCERN The patient was concerned about his crowded, narrow arches and the teeth that had not fully erupted.

DIAGNOSIS
Right: Class I
Left: Class I

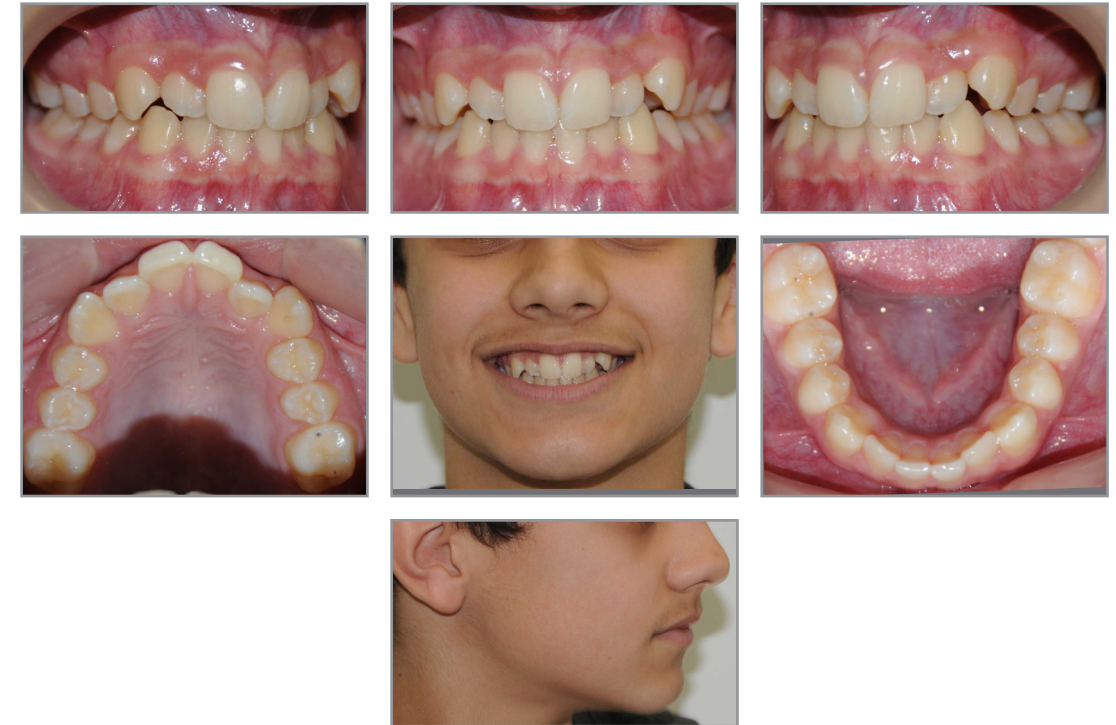Class I relationship with lower midline deviated 1.5 mm to the right, 30% overbite, and 2-3 mm of overjet.

LENGTH OF TREATMENT 8.5 months

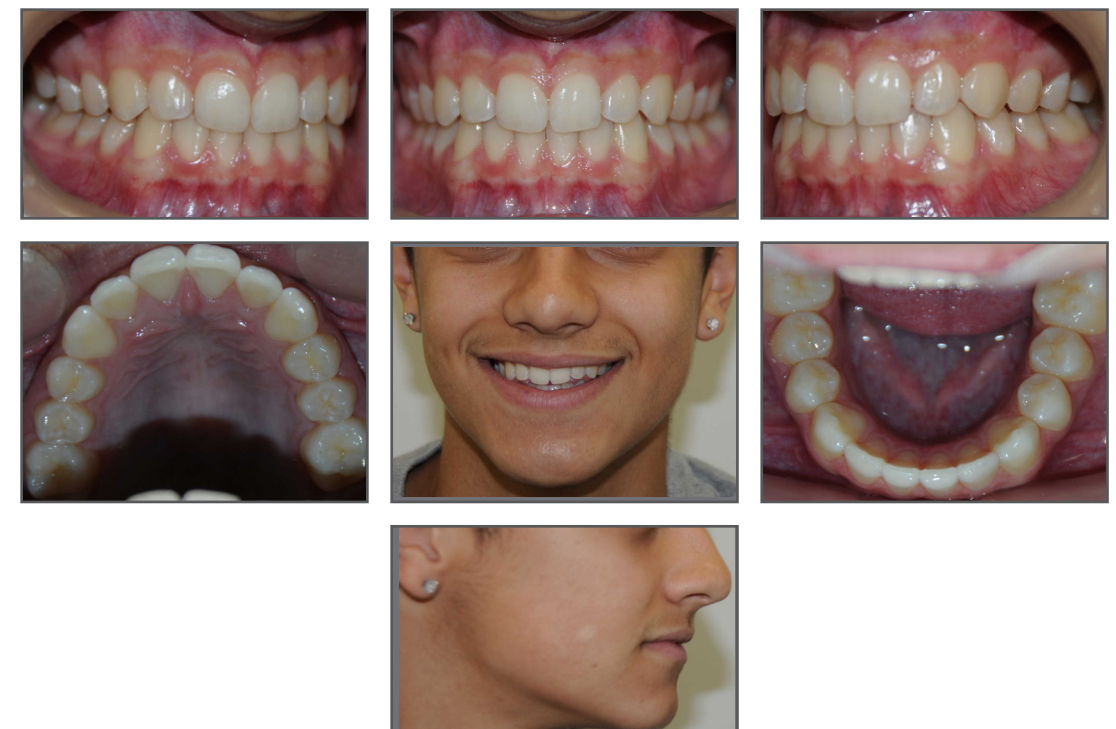OF ALIGNERS USED
Upper: 14 + 10
Lower: 14 + 10

ADDITIONAL TREATMENT Following Invisalign® treatment, incisal buildups were completed on the upper six and the lower four anterior teeth to restore worn, chipped, and/or missing tooth structure.

RETENTION
Upper: Vivera® retainer
Lower: Vivera® retainer



BEFORE



AFTER



Dr. Patricia Primero
The Smile Fairy Dental Spa
Naples, FL

www.TheSmileFairy.com

TREATMENT SUMMARY

PATIENT 72-year-old male

CHIEF CONCERN The patient had periodontal issues and difficulty with home care/oral hygiene. He was concerned about the mobility, longevity, and overall health of his teeth.

DIAGNOSIS Right: Class I
Left: Class I

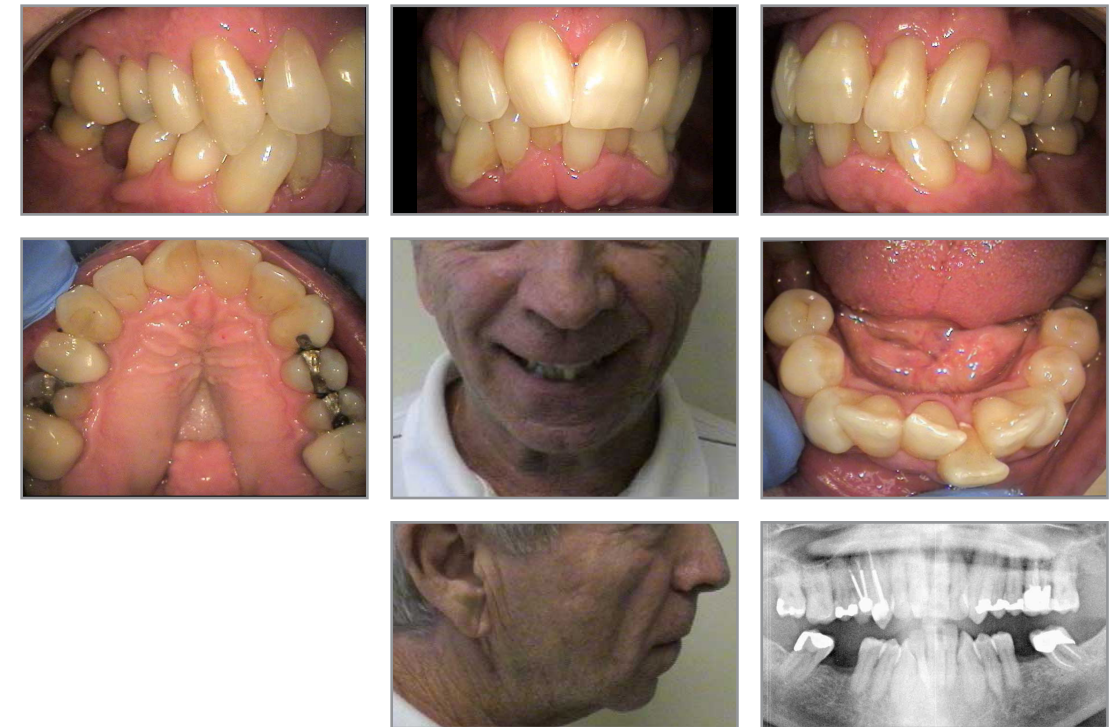Class I relationship with narrow arches, crowding, and deep bite.

LENGTH OF TREATMENT 26 months

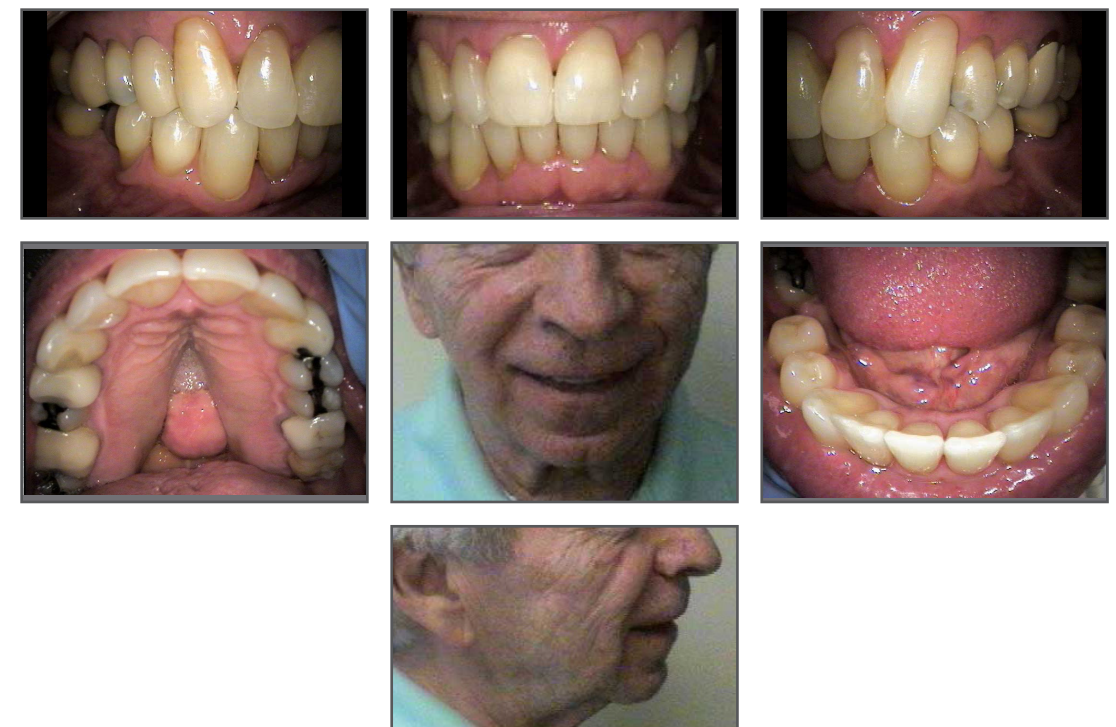
OF ALIGNERS USED Upper: 27 + 12 + 13
Lower: 27 + 12 + 17

ADDITIONAL TREATMENT Following Invisalign® treatment, the upper right first molar and the upper right first premolar were restored with CEREC® crowns.

RETENTION Upper: Vivera® retainer
Lower: Vivera® retainer



BEFORE



AFTER



Dr. Kenneth Pyle
Orlando Dental Group
Orlando, FL

www.OrlandoDentalGroup.com

TREATMENT SUMMARY

PATIENT 25-year-old male

CHIEF CONCERN The patient wanted to improve his smile without the use of crowns, veneers, or fixed orthodontics.

DIAGNOSIS
Right: Class I
Left: Class I

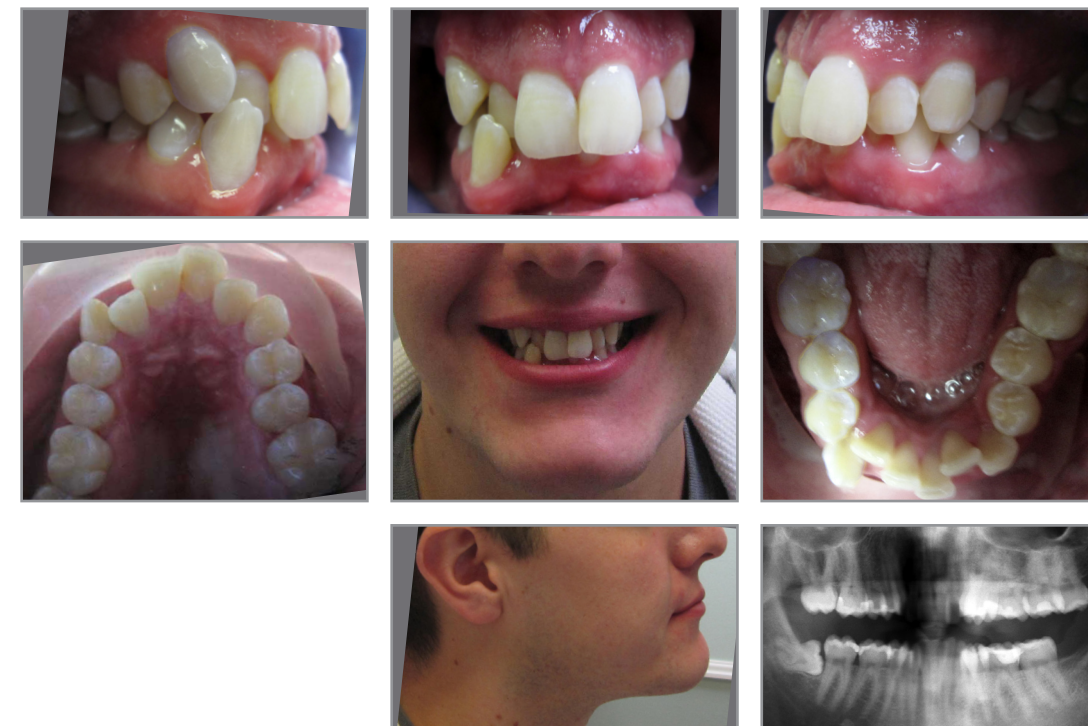Class I relationship with deep bite, excessive overjet, severe anterior crowding, and the upper right lateral incisor was in crossbite.

LENGTH OF TREATMENT 19 months

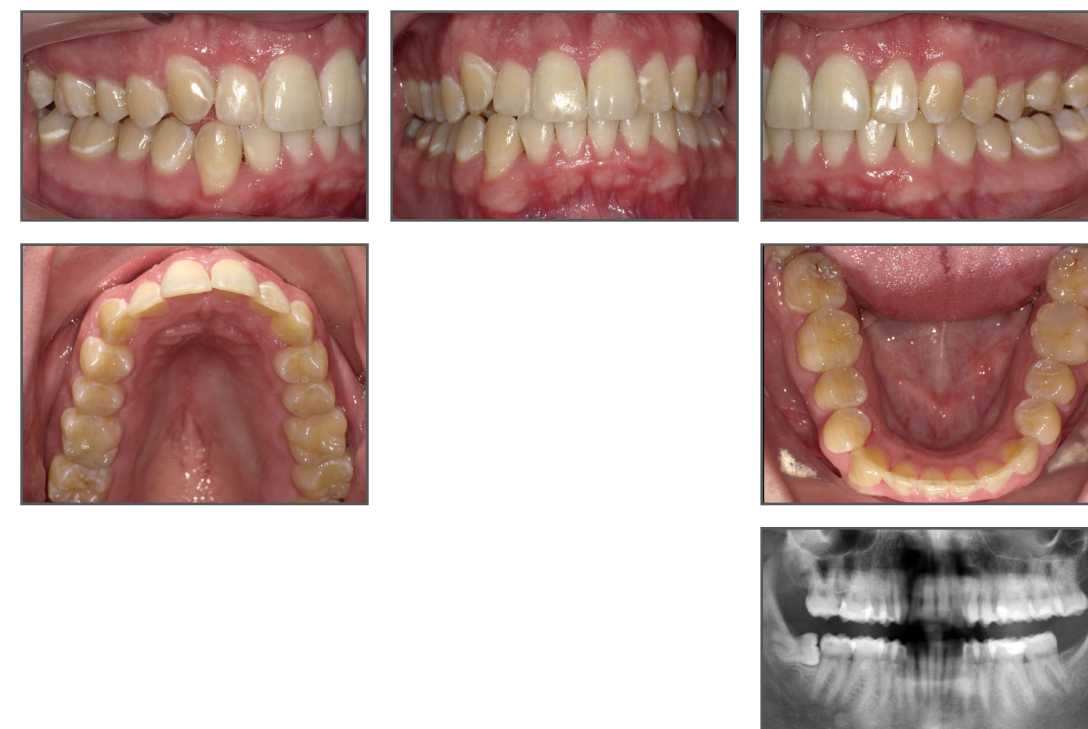OF ALIGNERS USED
Upper: 20 + 25
Lower: 20 + 25

ADDITIONAL TREATMENT Elastics were used to extrude the upper lateral incisors in lieu of refinement aligners. The PROPEL™ System was used to accelerate the rate of orthodontic treatment.

RETENTION
Upper: Vivera® retainer
Lower: Vivera® retainer



BEFORE



AFTER



Dr. Stephane Reinhardt
Clinique Dentaire Reinhardt, Thibert & Assoc.
Brossard, QC, Canada

www.CliniqueRTA.com



TREATMENT SUMMARY

PATIENT 17-year-old male

CHIEF CONCERN The patient was always hiding his smile because of his teeth, and for him braces were not an option; he saw braces as something that would make him look even worse.

DIAGNOSIS Right: Class II
Left: Class II

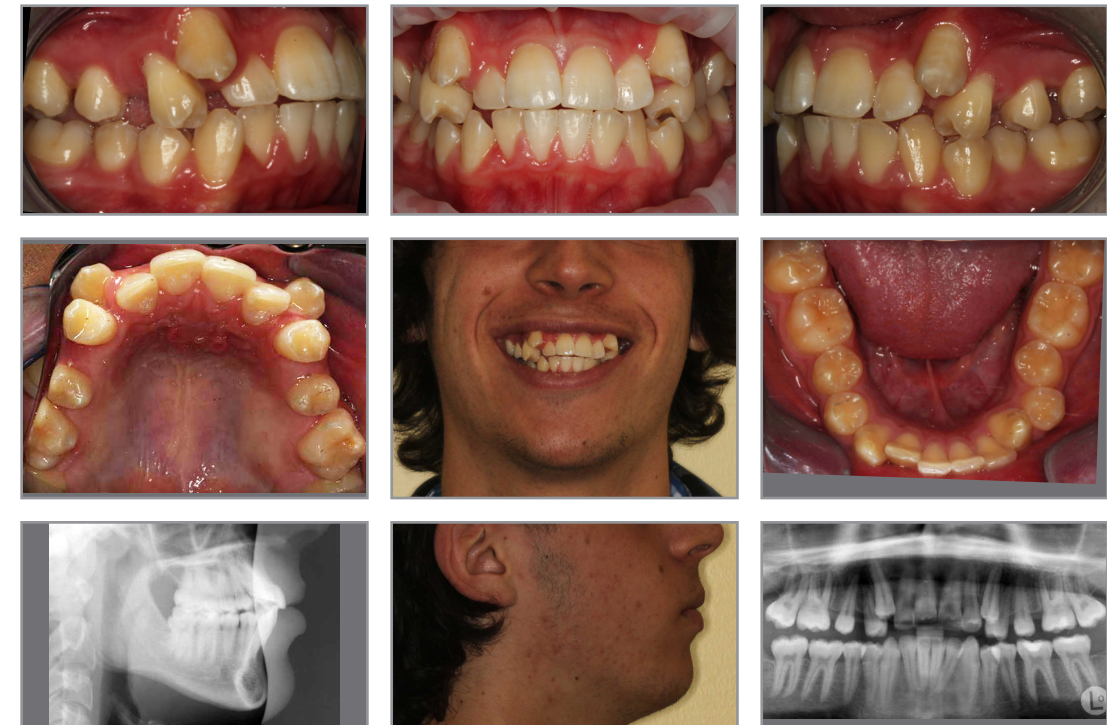Class II relationship with blocked out upper canines and upper first bicuspid in crossbite.

LENGTH OF TREATMENT 51 months

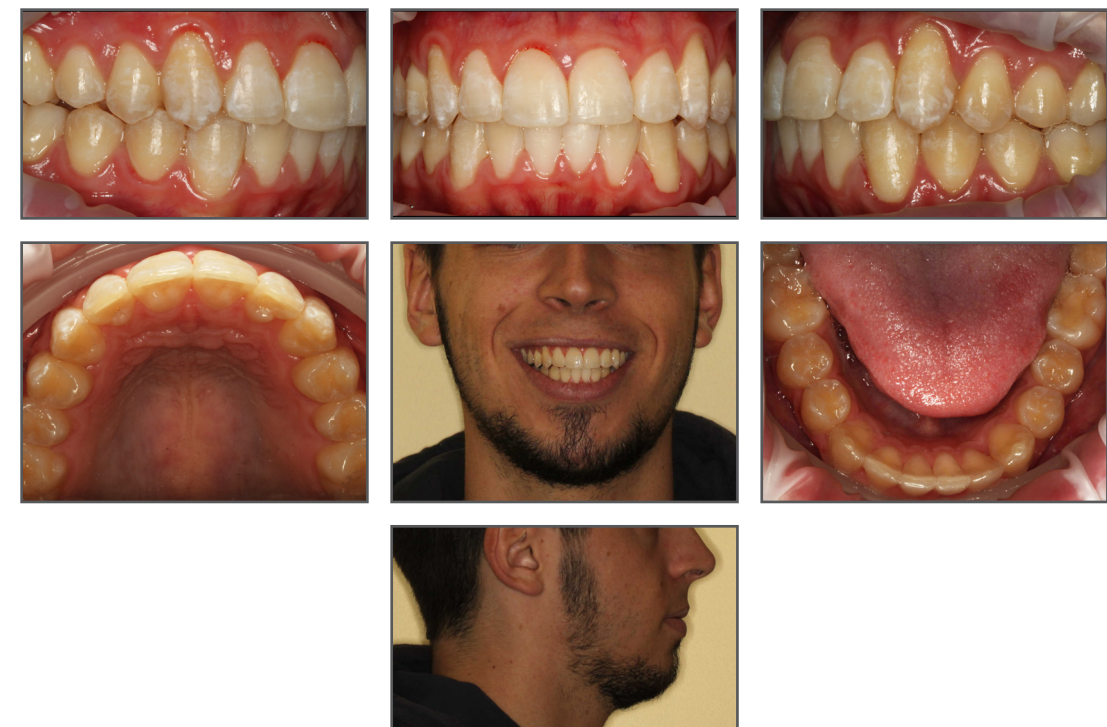OF ALIGNERS USED Upper: 47 + 18 + 15
Lower: 47 + 18 + 15

ADDITIONAL TREATMENT A distal-jet type appliance with expansion screws was used prior to starting Invisalign® treatment to move the upper molars distally and create space to align the teeth without extractions.

RETENTION Upper: Invisalign® retainer
Lower: Invisalign® retainer



BEFORE



AFTER



Dr. John Rogers
White Rock Dental Clinic
White Rock/South Surrey, BC, Canada

www.SurreyWhiteRockDentist.com

TREATMENT SUMMARY

PATIENT 30-year-old female

CHIEF CONCERN The patient was concerned about her crowded teeth and v-shaped upper arch.

DIAGNOSIS
Right: Class I
Left: Class I

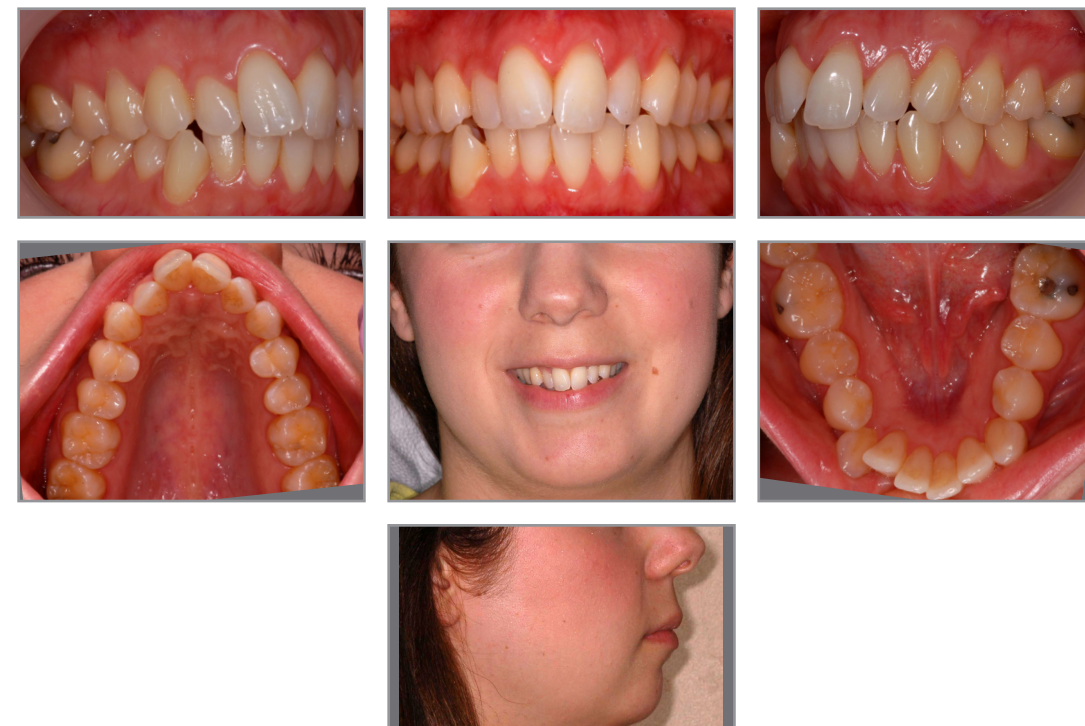Class I relationship with moderate anterior crowding and narrow v-shaped maxillary anterior segment.

LENGTH OF TREATMENT 16 months

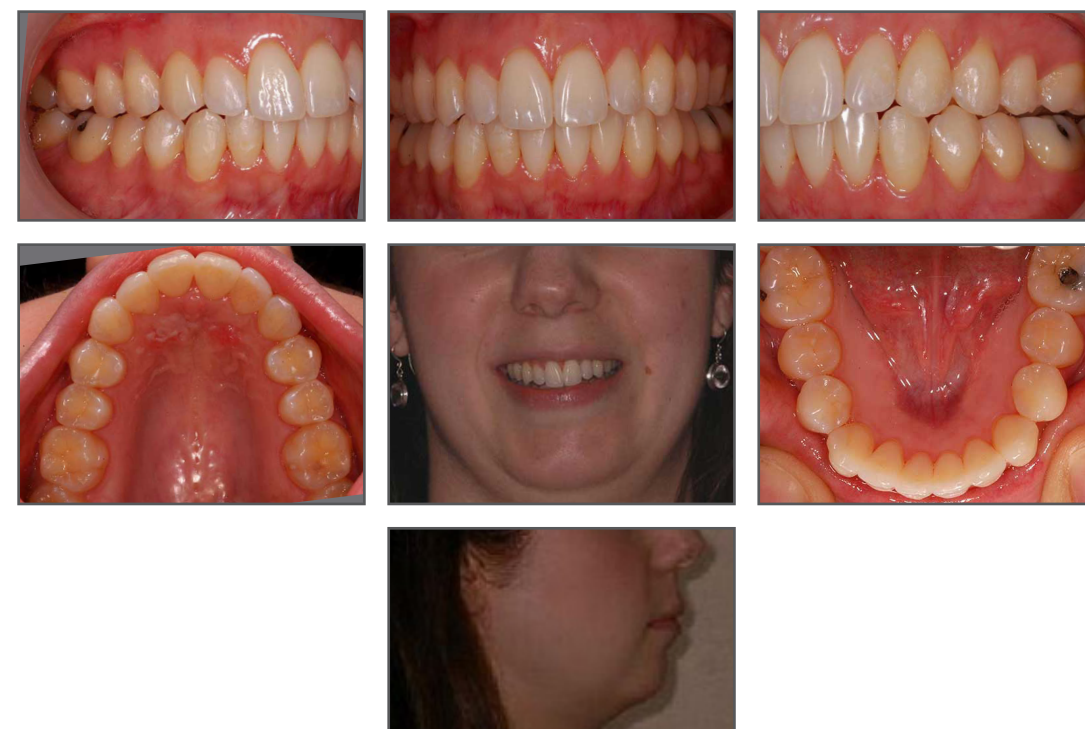OF ALIGNERS USED
Upper: 10 + 11 + 11
Lower: 10 + 11 + 11

ADDITIONAL TREATMENT None

RETENTION
Upper: Vivera® retainer
Lower: Vivera® retainer



BEFORE



AFTER

SPACING TREATMENTS





Dr. Payam Ataii
Laser Dental Center
Laguna Hills, CA

www.LaserDentalCenterOC.com

TREATMENT SUMMARY

PATIENT 30-year-old female

CHIEF CONCERN The patient was concerned about her open bite and the affect that her teeth had on her speech.

DIAGNOSIS
Right: Class II
Left: Class II

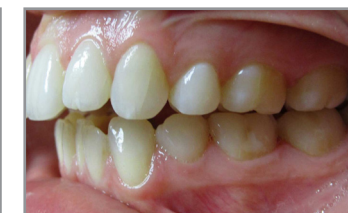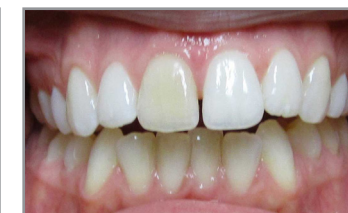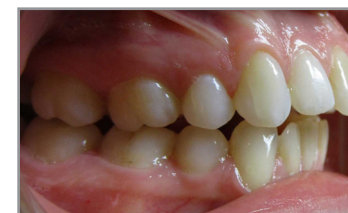Bilateral Class II relationship with minimal overbite, 12 mm of overjet, and lower crowding. The patient had had orthodontic treatment twice before.

LENGTH OF TREATMENT 10 months

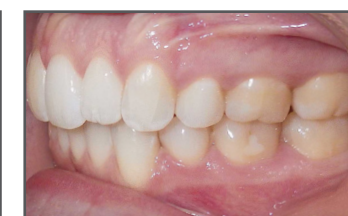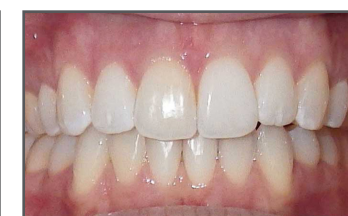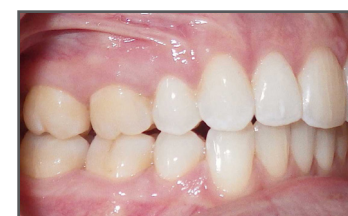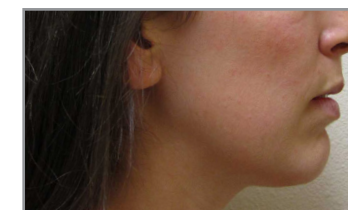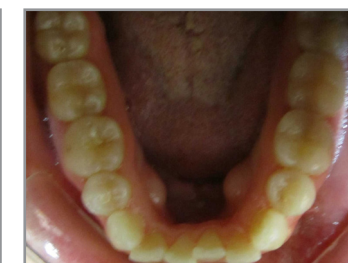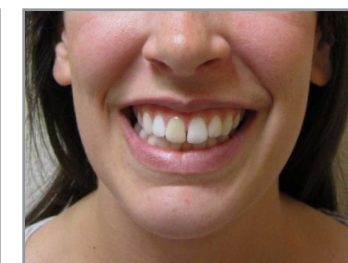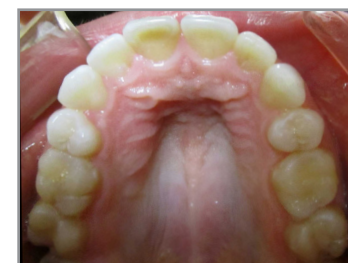OF ALIGNERS USED
Upper: 12 + 8
Lower: 12 + 8

ADDITIONAL TREATMENT None

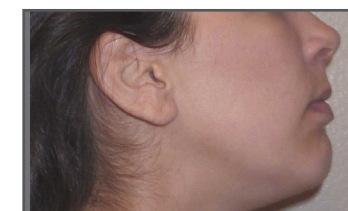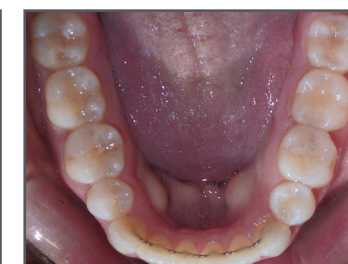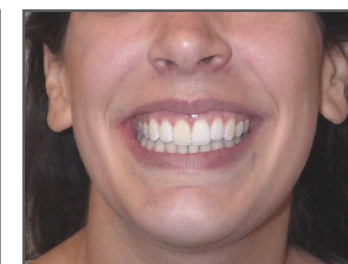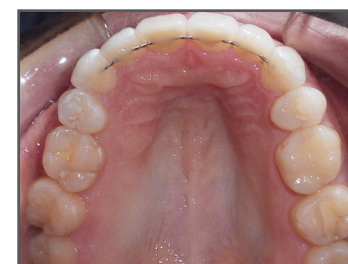RETENTION
Upper: Bonded lingual
Lower: Bonded lingual



BEFORE



AFTER





Dr. Anthony Gadbois
Cherry Hill Dental Associates, Inc.
Columbia, MO

www.CherryHillDentalOnline.com

TREATMENT SUMMARY

PATIENT 16-year-old female

CHIEF CONCERN The patient was concerned about her upper right canine in crossbite.

DIAGNOSIS
Right: Class I
Left: Class I

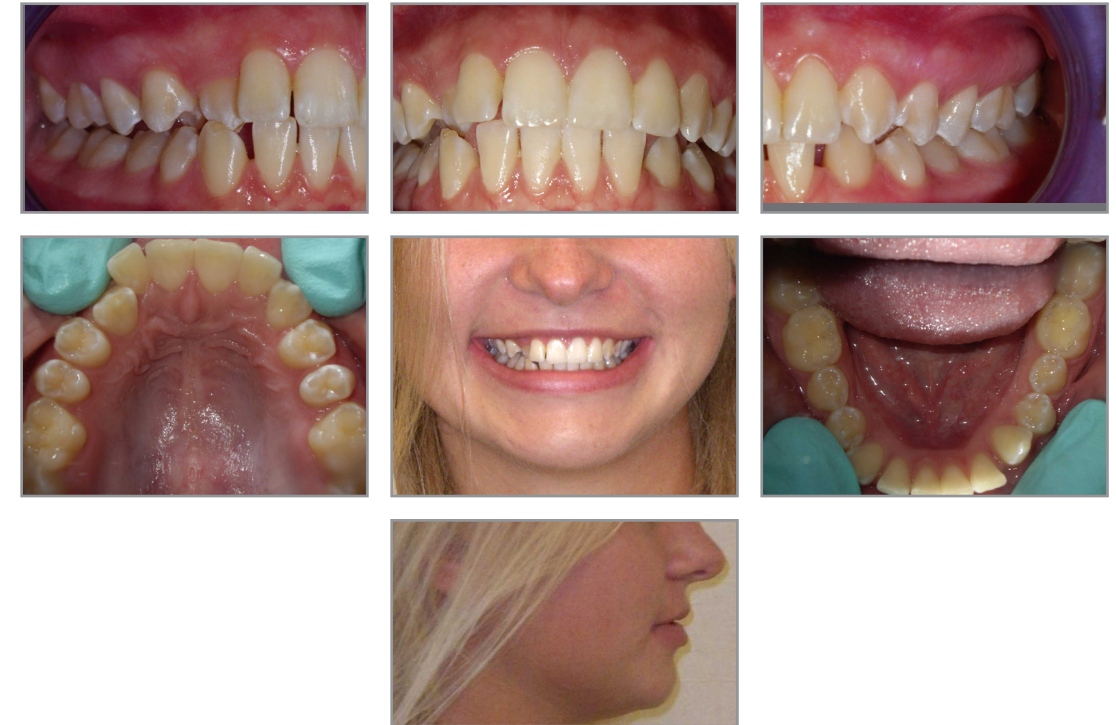Class I relationship with mandibular spacing and the upper right canine in crossbite.

LENGTH OF TREATMENT 17 months

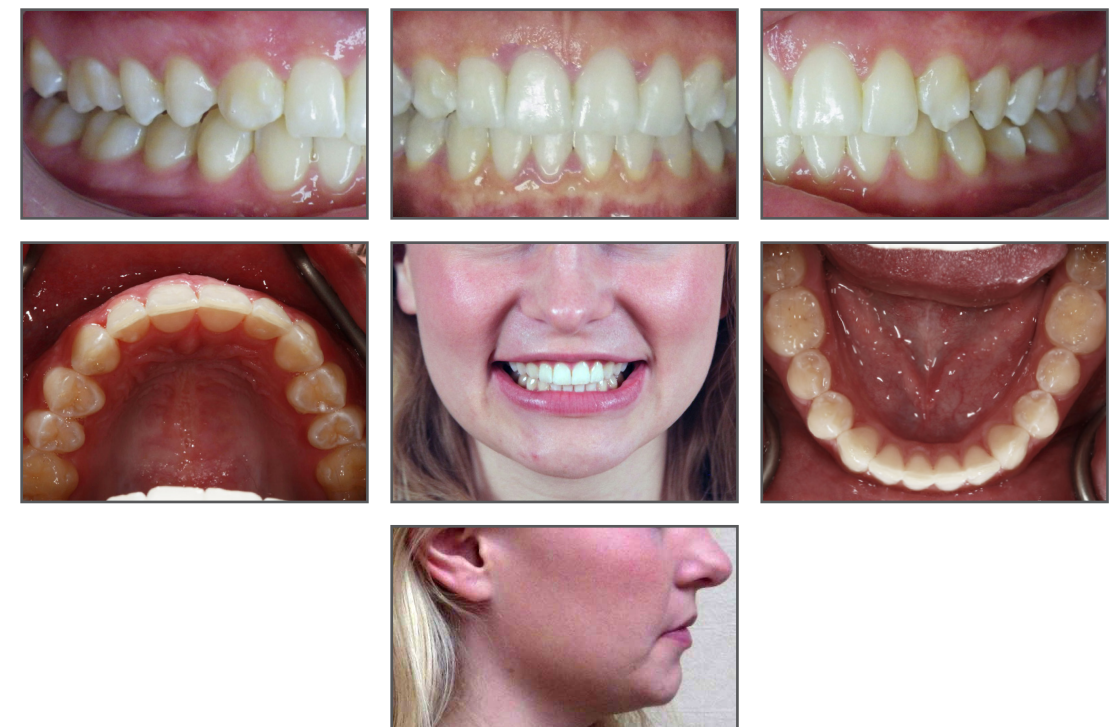
OF ALIGNERS USED
Upper: 13 + 13
Lower: 15 + 9

ADDITIONAL TREATMENT Chewies™ were used during refinement to help seat the aligners. Following Invisalign® treatment, enameloplasty and incisal bonding were completed to improve aesthetics.

RETENTION
Upper: Other clear
Lower: Other clear



BEFORE



AFTER



Dr. David Galler
Premier Dental Associates of Lower Manhattan
New York, NY

www.PremierDentalAssociates.com

TREATMENT SUMMARY

PATIENT 39-year-old female

CHIEF CONCERN The patient did not like the space between her front teeth, and her baby teeth were loose.

DIAGNOSIS Right: Class II
Left: Class I

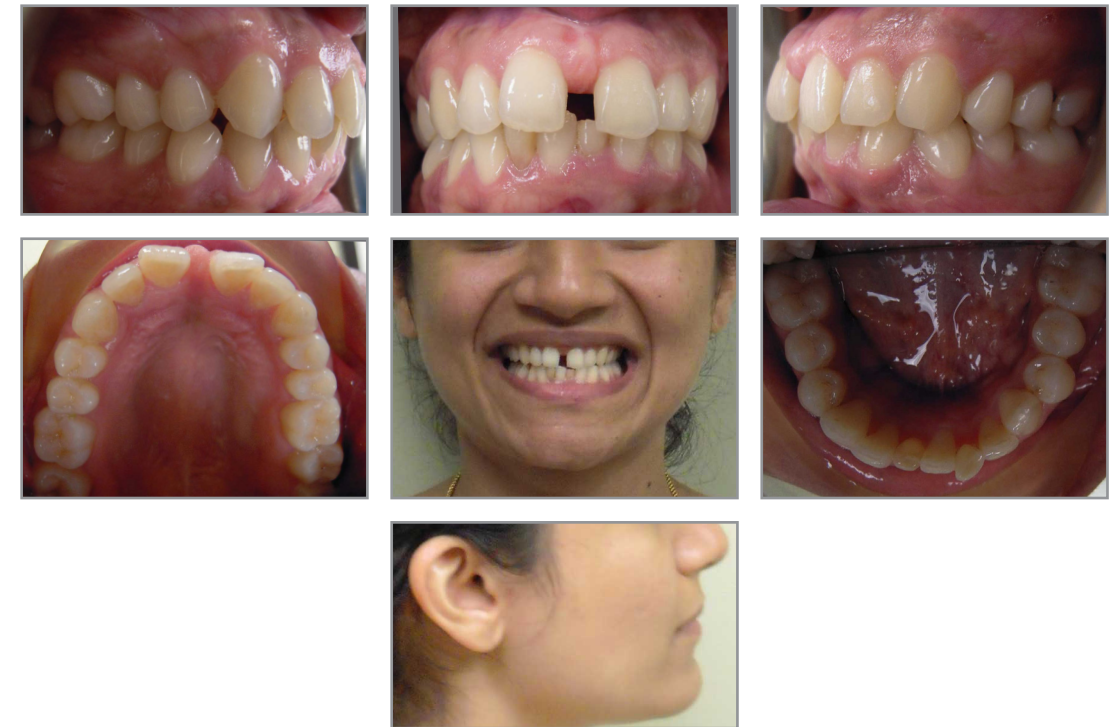Class II relationship on the right side and Class I relationship on the left side with large maxillary diastema, deep bite, and retained primary mandibular incisors.

LENGTH OF TREATMENT 11 months

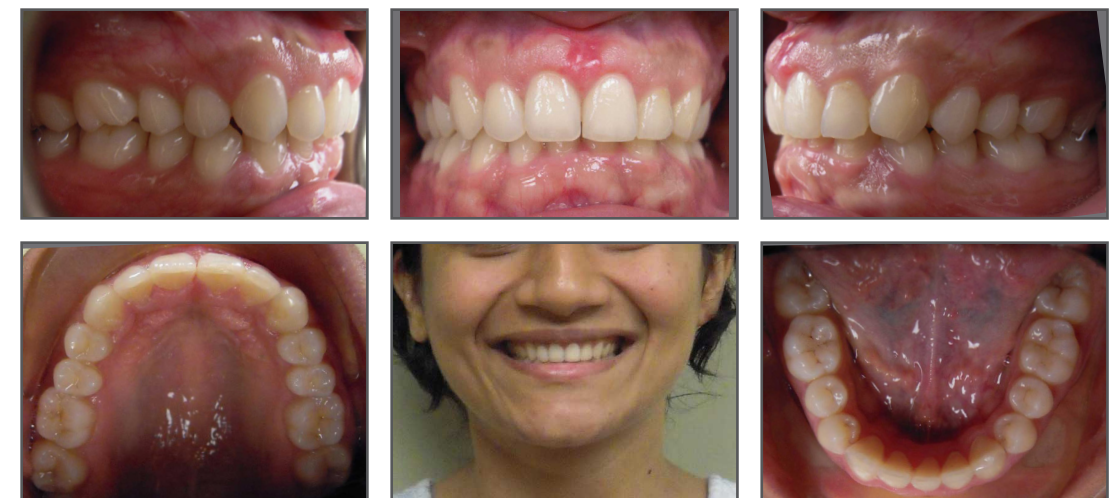OF ALIGNERS USED Upper: 23
Lower: 23

ADDITIONAL TREATMENT None

RETENTION Upper: Vivera® retainer
Lower: Vivera® retainer



BEFORE



AFTER





Dr. Mike Hinkle
Utica Dental
Tulsa, OK

www.UticaDental.com

TREATMENT SUMMARY

PATIENT 47-year-old female

CHIEF CONCERN The patient had bleeding gums around her lower teeth, food traps that made oral hygiene difficult, and she feared tooth loss if nothing was done to correct her problems.

DIAGNOSIS Right: Class II
Left: Class II

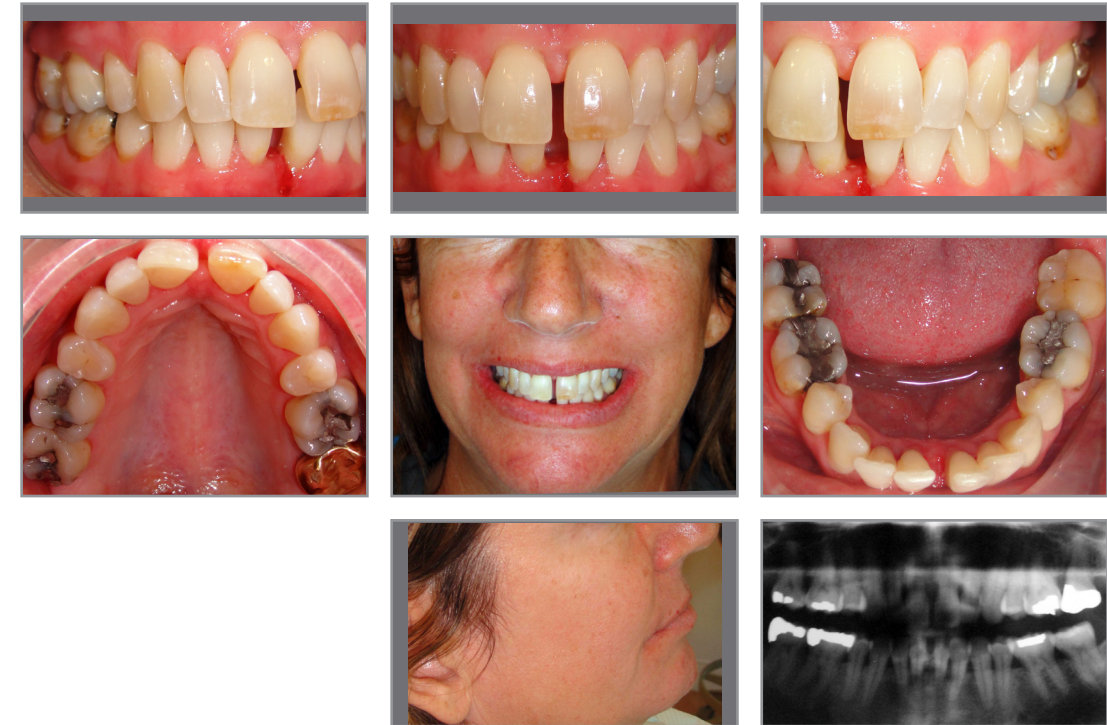Class II relationship with excessive overjet and supra-erupted incisors due to malocclusion.

LENGTH OF TREATMENT 20 months

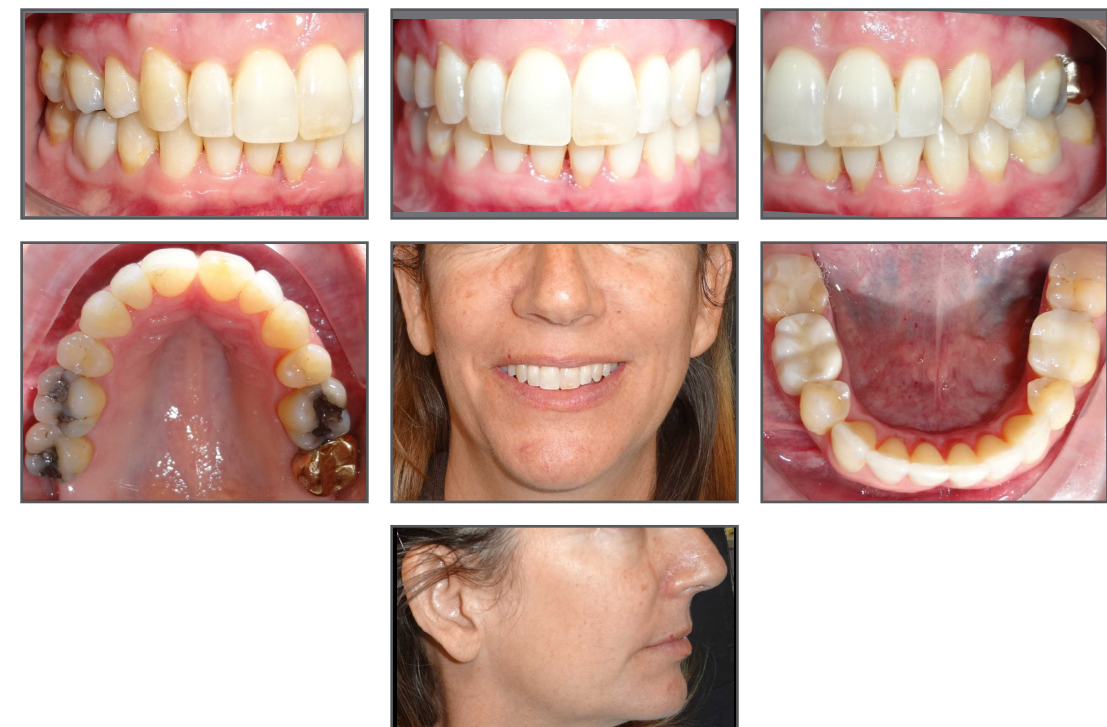OF ALIGNERS USED Upper: 22 + 18
Lower: 22 + 18

ADDITIONAL TREATMENT Root canal treatment and a crown were completed on the lower right first molar, with frequent scaling to improve tissue health.

RETENTION Upper: Vivera® retainer
Lower: Vivera® retainer



BEFORE



AFTER

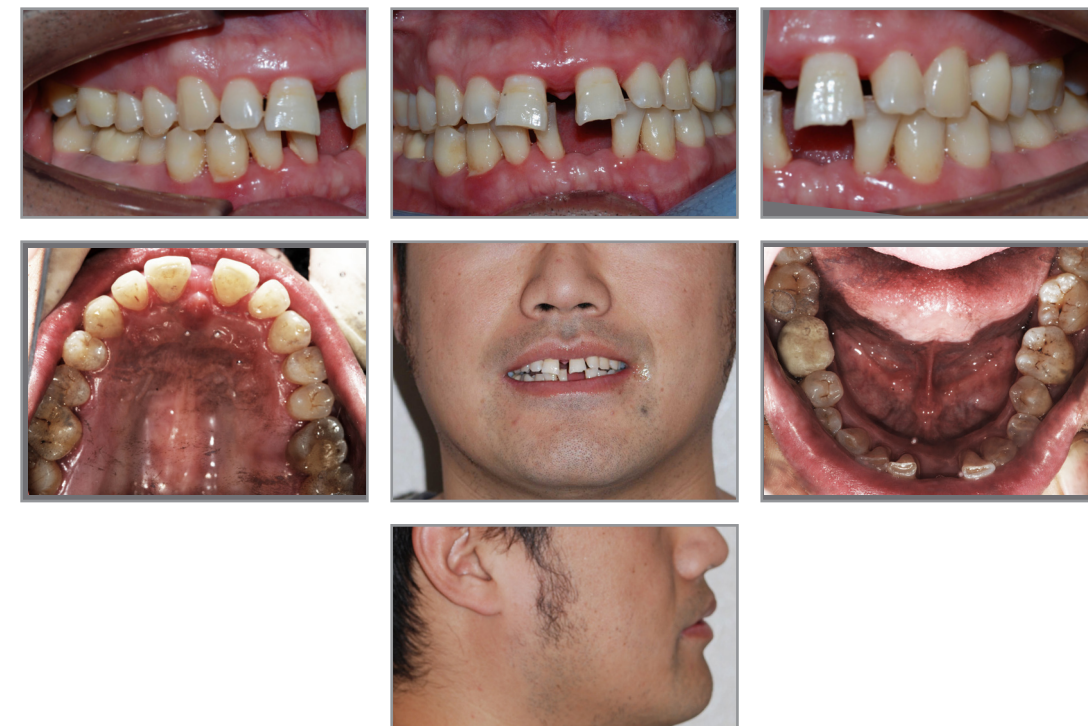

Dr. Yu Li
City Centre Dental Clinic
Surrey, BC, Canada

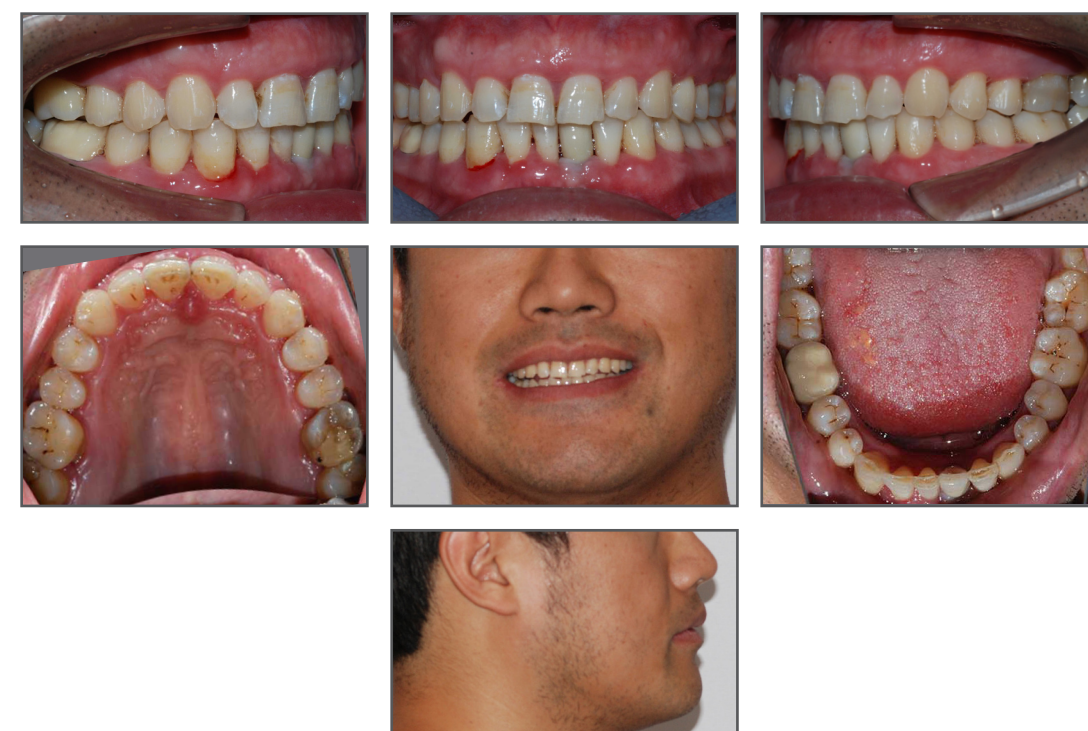www.facebook.com/dryuli

TREATMENT SUMMARY

PATIENT	34-year-old male
CHIEF CONCERN	The patient was concerned about his crooked teeth.
DIAGNOSIS	Right: Class II Left: Class II Class II relationship with spacing in both arches and missing lower left central incisor.
LENGTH OF TREATMENT	8 months
# OF ALIGNERS USED	Upper: 17 Lower: 17
ADDITIONAL TREATMENT	An implant and crown was placed in the area of the lower left central incisor following Invisalign® treatment.
RETENTION	Upper: Vivera® retainer Lower: Vivera® retainer



BEFORE



AFTER



Dr. Daniel Noor
Smile Café
New York, NY

www.SmileCafeNY.com

TREATMENT SUMMARY

PATIENT 25-year-old male

CHIEF CONCERN The patient was not comfortable around people due to his huge spaces, and was not able to bite into anything with his front teeth. He wanted to improve his smile without fixed braces.

DIAGNOSIS Right: Class I
Left: Class I

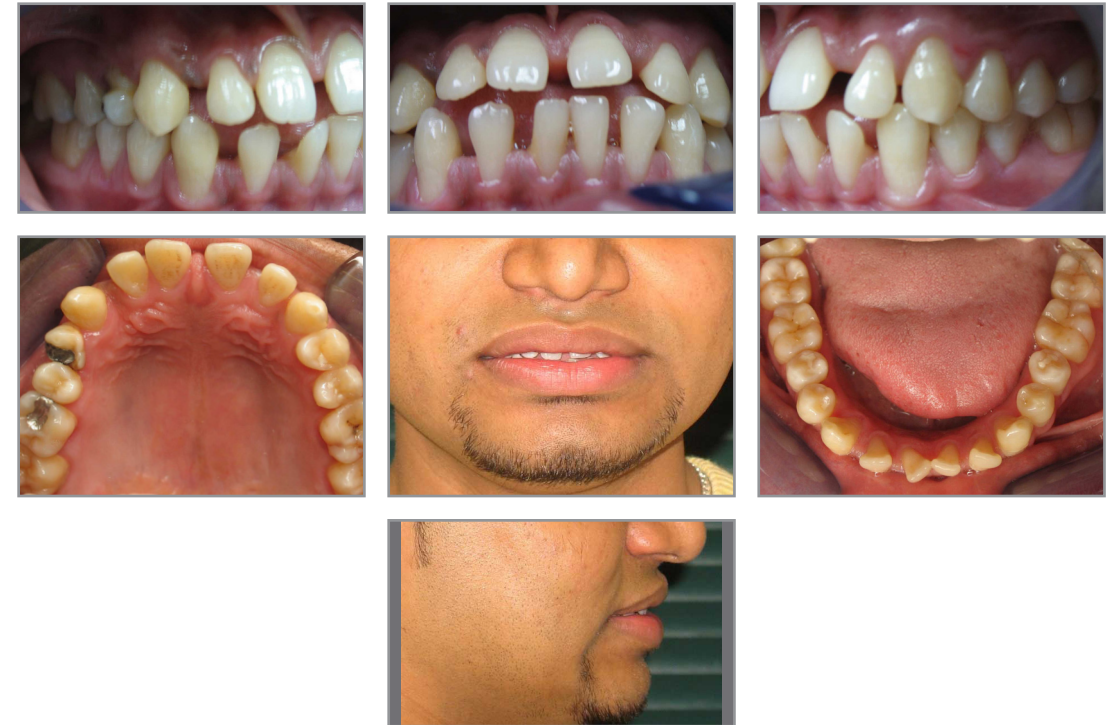Class I relationship with severe spacing, anterior open bite, and rotated and protruded upper and lower anterior teeth.

LENGTH OF TREATMENT 20 months

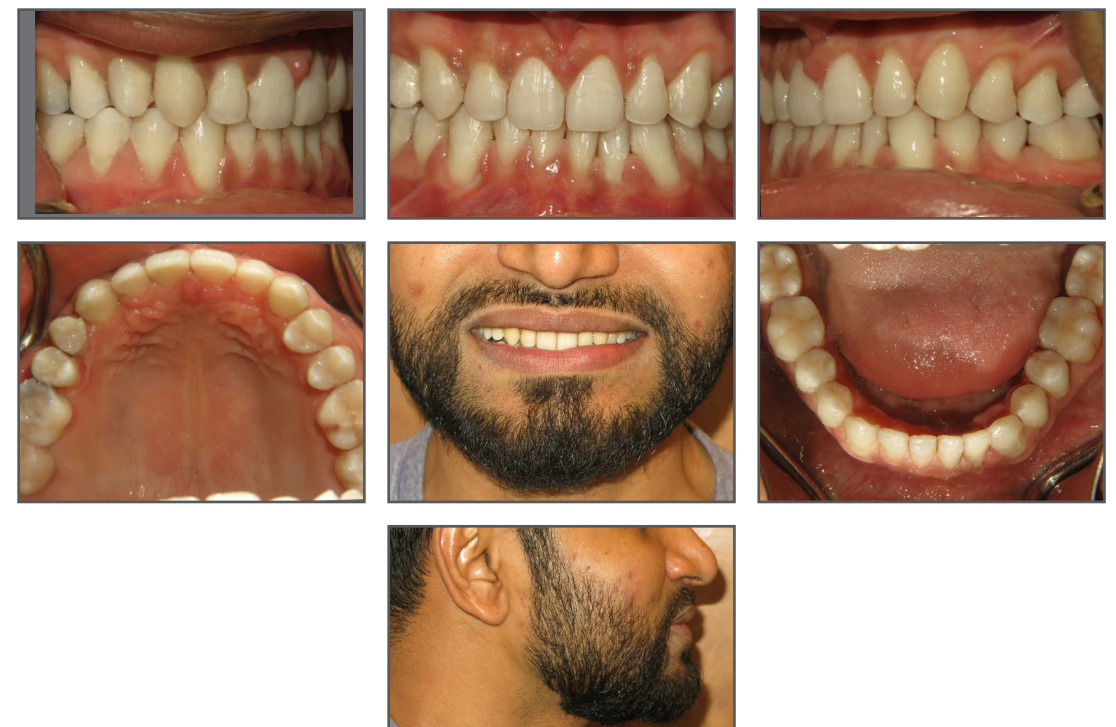OF ALIGNERS USED Upper: 30 + 25
Lower: 30 + 25

ADDITIONAL TREATMENT Wear time near the end of treatment was every 10 days. Detailing pliers were used as needed.

RETENTION Upper: Last Invisalign® aligner followed by Vivera® retainer
Lower: Last Invisalign® aligner followed by Vivera® retainer



BEFORE



AFTER



Dr. Stephane Reinhardt
Clinique Dentaire Reinhardt, Thibert & Assoc.
Brossard, QC, Canada

www.CliniqueRTA.com

TREATMENT SUMMARY

PATIENT 21-year-old female

CHIEF CONCERN The patient did not like to smile in pictures, and wanted a new smile that she could show off.

DIAGNOSIS Right: Class II
Left: Class II

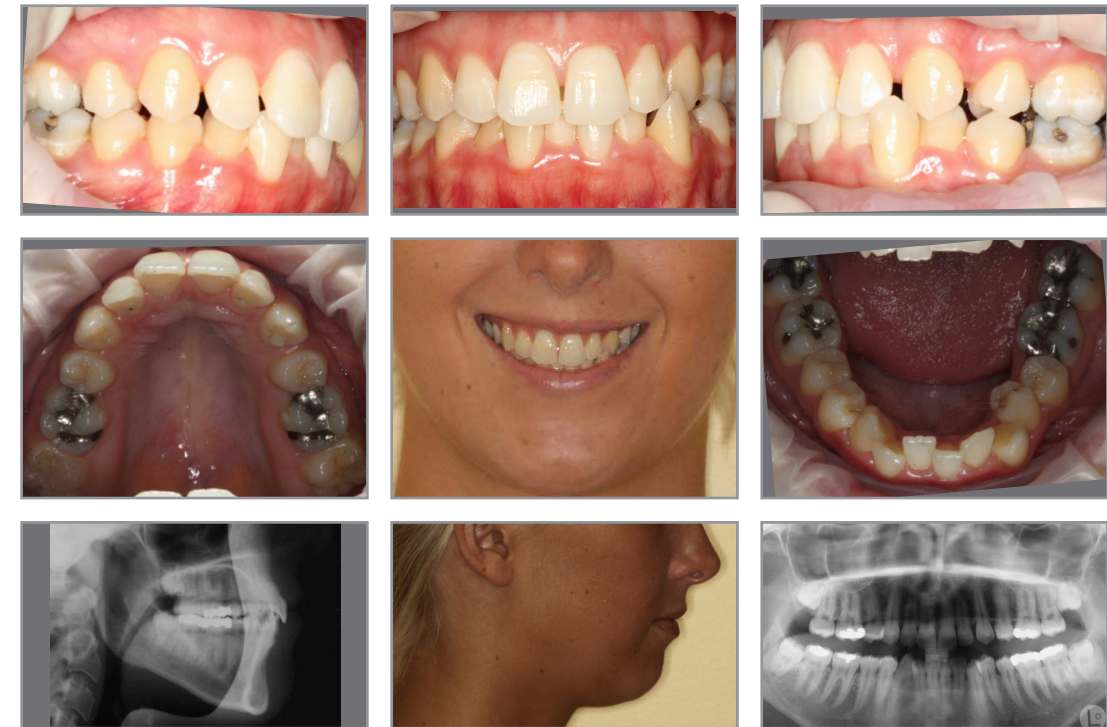Class II dental and Class I skeletal relationship with crowding in the lower arch, spacing in the upper arch due to two missing premolars, and the upper left lateral incisor and the lower left canine in crossbite.

LENGTH OF TREATMENT 10 months

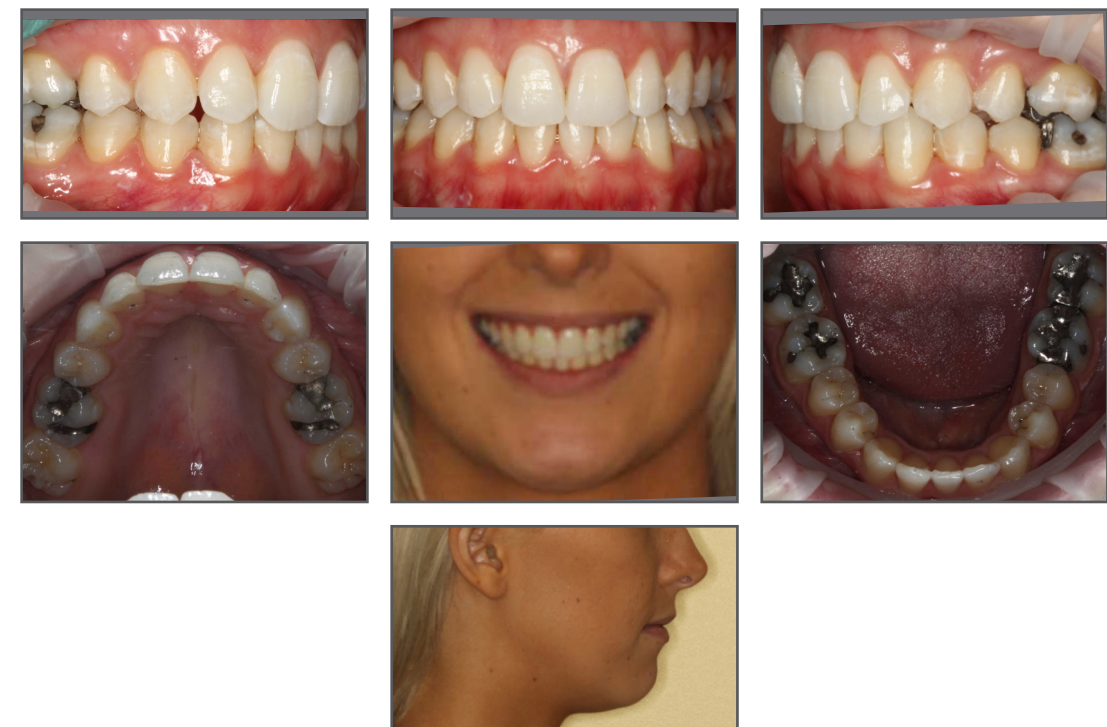OF ALIGNERS USED Upper: 19
Lower: 19

ADDITIONAL TREATMENT The lower right central incisor was extracted prior to Invisalign® treatment.

RETENTION Upper: Invisalign® retainer
Lower: Invisalign® retainer



BEFORE



AFTER



Dr. Richard Schmidt
Dentistry At 8 Nelson
Brampton, ON, Canada

www.DentistryAt8Nelson.com



TREATMENT SUMMARY

PATIENT 60-year-old female

CHIEF CONCERN The patient was not happy wearing an acrylic removable partial denture for over 35 years, and desired a more aesthetic smile.

DIAGNOSIS
Right: Class II
Left: Class II

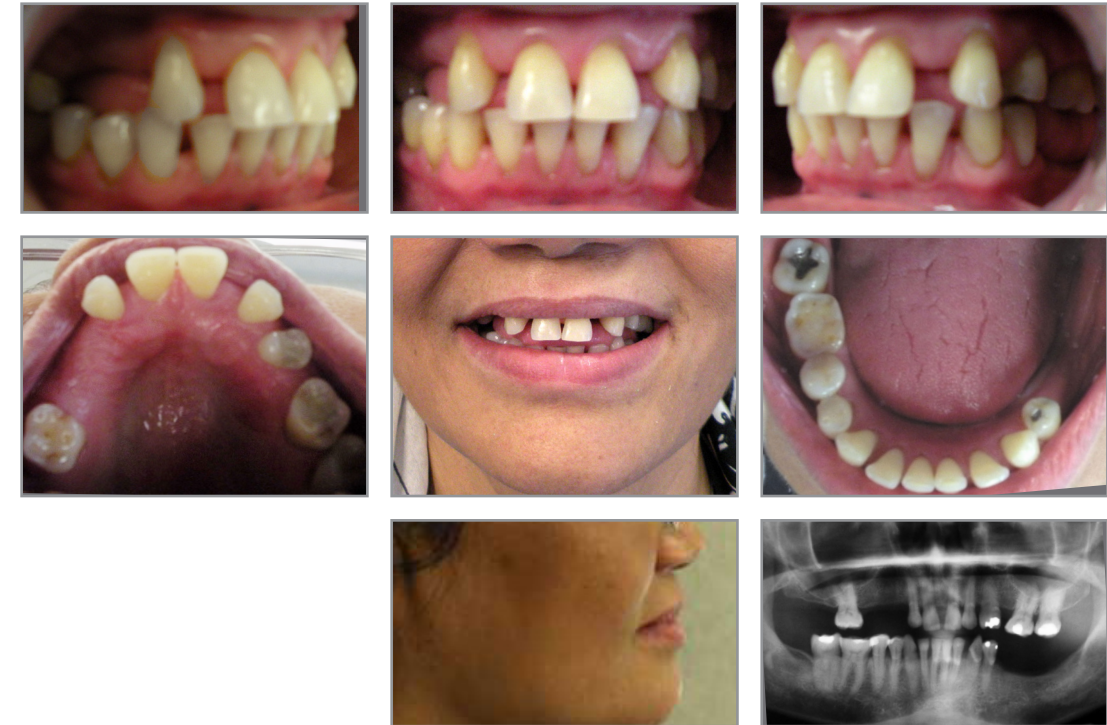Class II canine relationship with premature loss of multiple permanent teeth and tooth migration, as well as congenitally missing upper lateral incisors.

LENGTH OF TREATMENT 24 months

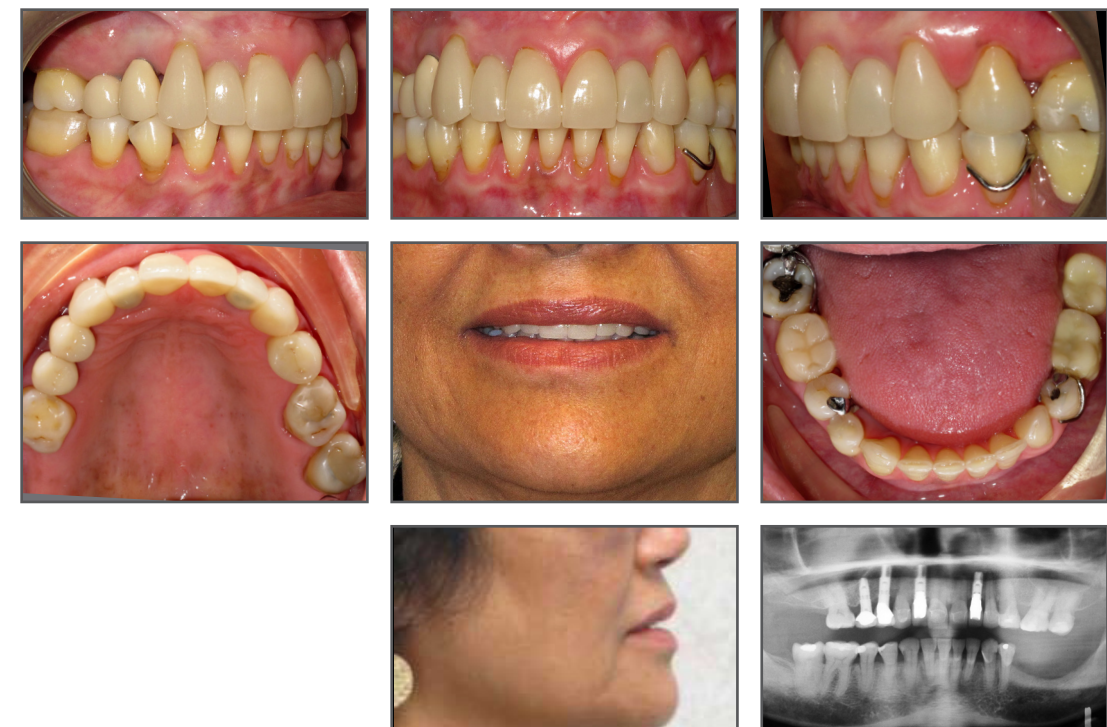OF ALIGNERS USED
Upper: 19 + 0
Lower: 13 + 7

ADDITIONAL TREATMENT Sectional braces were used to consolidate the upper central incisors, distalize the upper canines, and align the lower anterior segment. Following orthodontic treatment, four maxillary implant-supported crowns, five maxillary porcelain crowns, a mandibular resin onlay, and a new lower removable partial denture were completed to restore function to both arches.

RETENTION
Upper: Vivera® retainer
Lower: Vivera® retainer



BEFORE



AFTER



Dr. Jeffrey Tamucci
Jeffrey A. Tamucci, DDS
Norwalk, CT

www.TamucciDDS.com

TREATMENT SUMMARY

PATIENT 52-year-old male

CHIEF CONCERN The patient was concerned about the spaces between his upper front teeth.

DIAGNOSIS
Right: Class II
Left: Class II

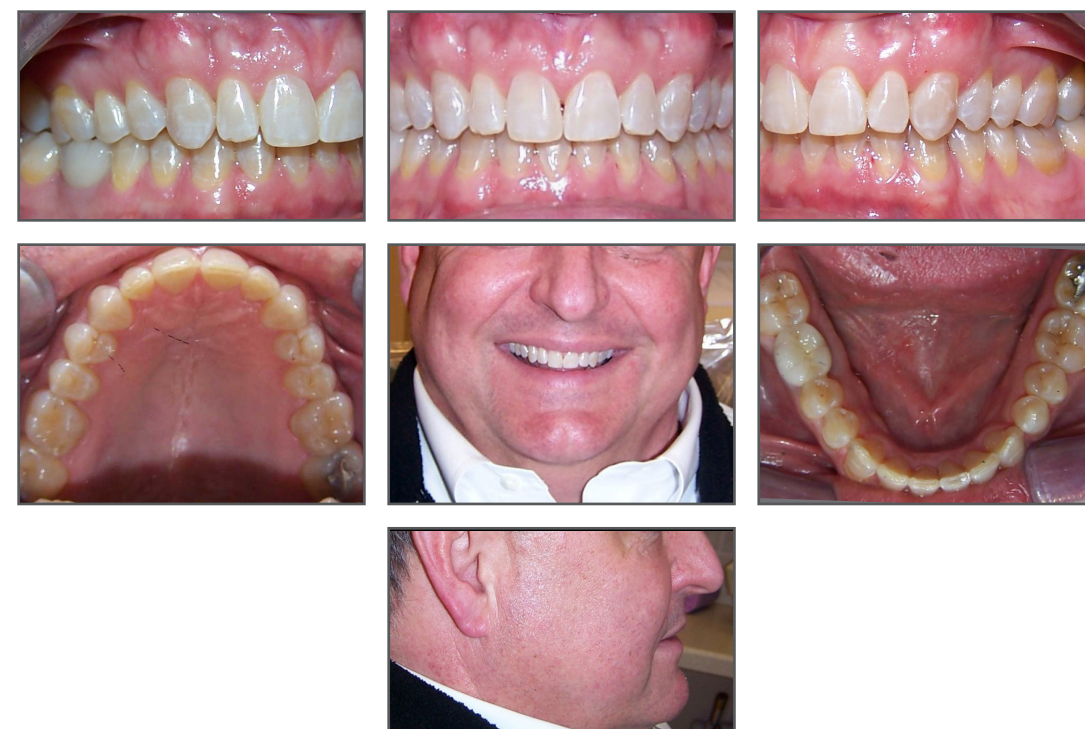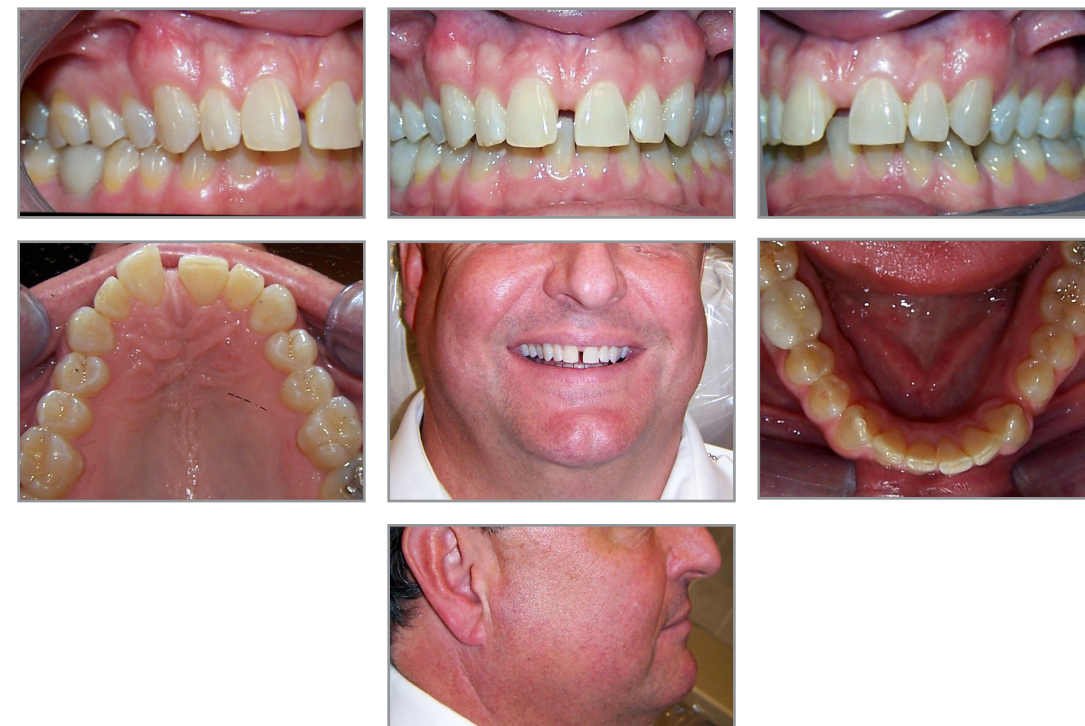Class II relationship with flared and spaced upper anterior incisors, deep bite, and excessive overjet.

LENGTH OF TREATMENT 14 months

OF ALIGNERS USED
Upper: 31
Lower: 31

ADDITIONAL TREATMENT None

RETENTION
Upper: Vivera® retainer
Lower: Vivera® retainer



RESTORATIVE TREATMENTS





Dr. Joseph Field
Peninsula Center of Cosmetic Dentistry
Los Altos, CA

www.PCCD.net

TREATMENT SUMMARY

PATIENT 41-year-old female

CHIEF CONCERN The patient was in a bike accident and subsequently lost the lower left lateral incisor. Additionally, she wanted to improve her smile by straightening her teeth.

DIAGNOSIS Right: Class I
Left: Class I

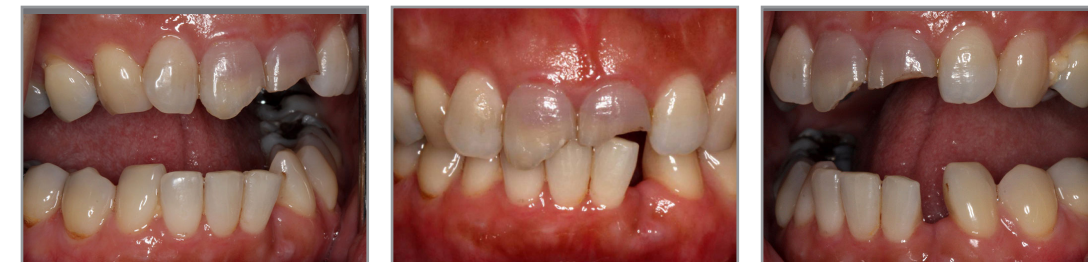Class I molar and canine relationship with rotated upper anteriors and crowding in the lower arch.

LENGTH OF TREATMENT 12 months

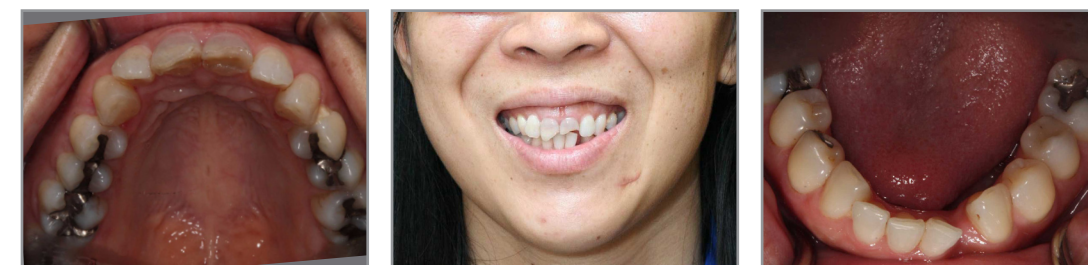OF ALIGNERS USED Upper: 14 + 6
Lower: 14 + 6

ADDITIONAL TREATMENT Prior to orthodontic treatment, root canal therapy and temporary crowns were completed on the upper central incisors. After Invisalign® treatment, the teeth were whitened, an implant and crown were placed in the area of the missing lower left lateral, and permanent crowns were placed on the upper centrals.

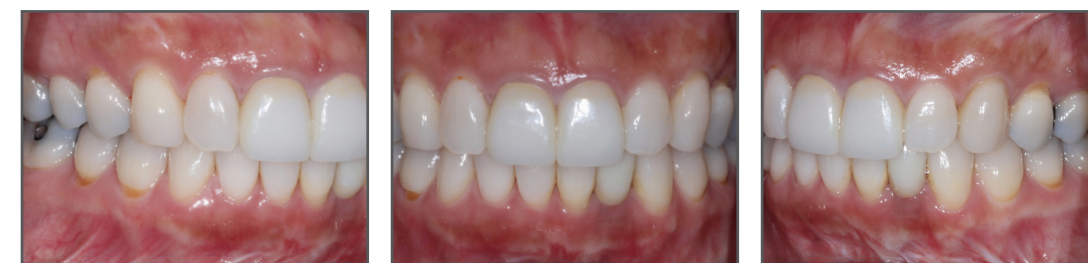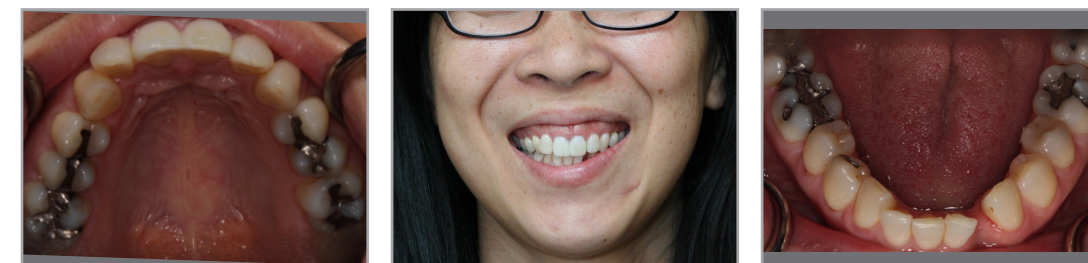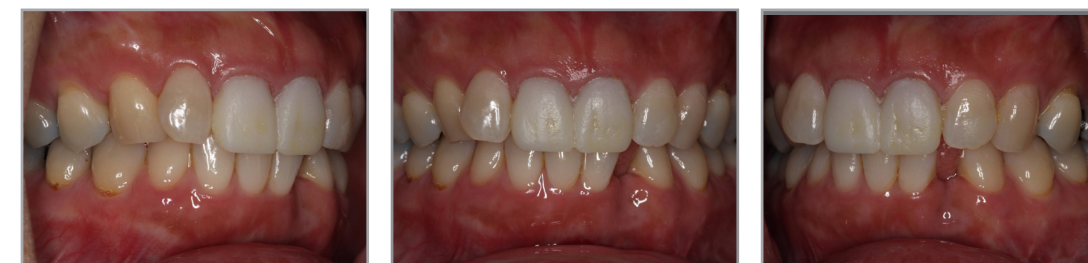RETENTION Upper: Other clear
Lower: Other clear



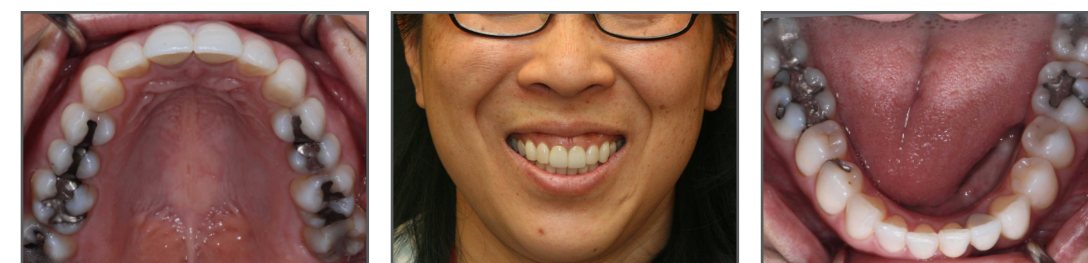BEFORE



PRE-RESTORATIVE



AFTER





Dr. David Galler
Premier Dental Associates of Lower Manhattan
New York, NY

www.PremierDentalAssociates.com

TREATMENT SUMMARY

PATIENT 31-year-old female

CHIEF CONCERN The patient felt that her smile was "not pretty."

DIAGNOSIS Right: Class I
Left: Class I

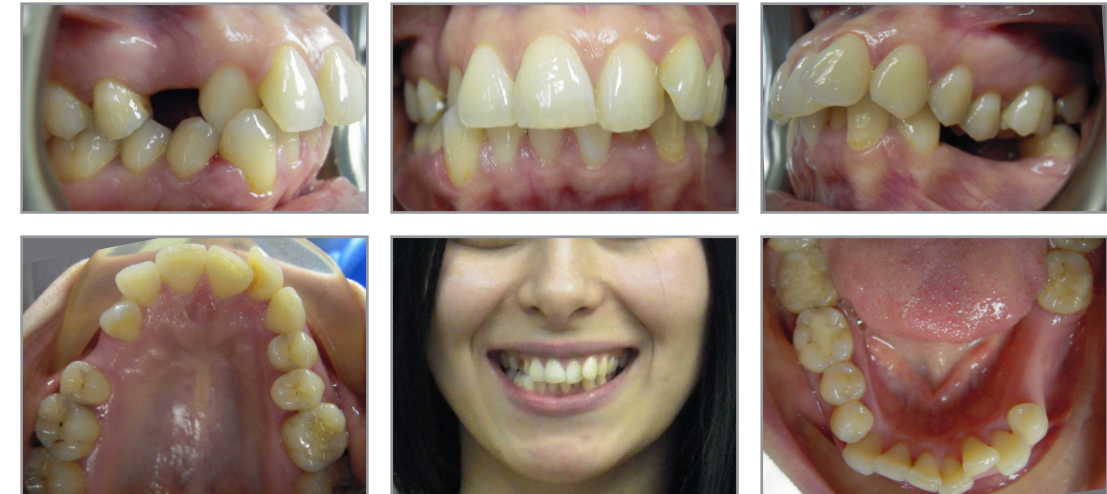Class I relationship with several missing teeth, significant flaring of the anterior teeth, excessive overjet, and crossbite on the right side.

LENGTH OF TREATMENT 15 months

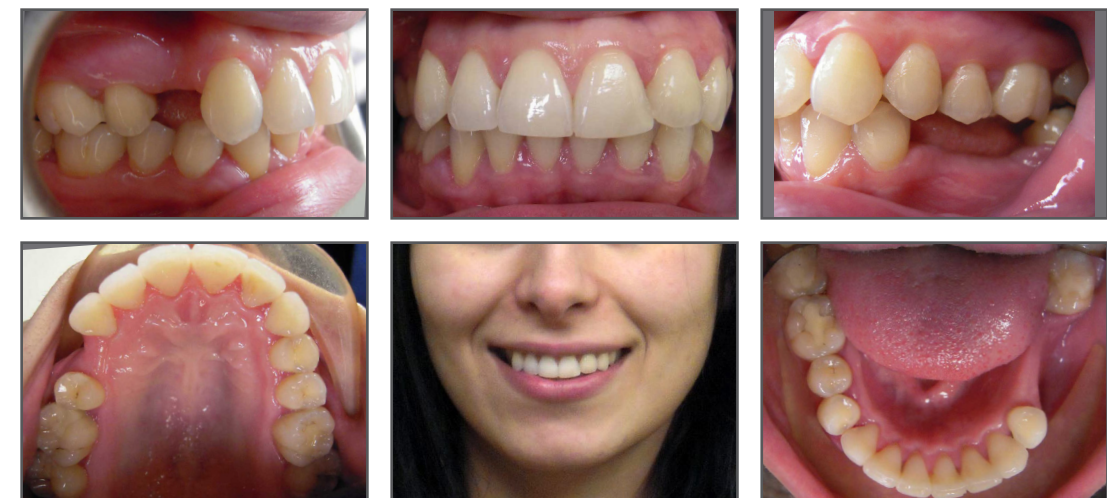OF ALIGNERS USED Upper: 15 + 5
Lower: 15 + 5

ADDITIONAL TREATMENT Following Invisalign® treatment to align the teeth and intrude the upper left posterior segment to improve vertical clearance, implants and crowns were placed in the remaining edentulous areas to restore function.

RETENTION Upper: Vivera® retainer
Lower: Vivera® retainer



BEFORE



AFTER





Dr. Xianglong Li
Xianglong Li, DDS, MA, PC
New York, NY

www.facebook.com/xianglonglidds

TREATMENT SUMMARY

PATIENT 45-year-old male

CHIEF CONCERN The patient wanted to fix all problems with his teeth.

DIAGNOSIS Right: Class I
Left: Class I

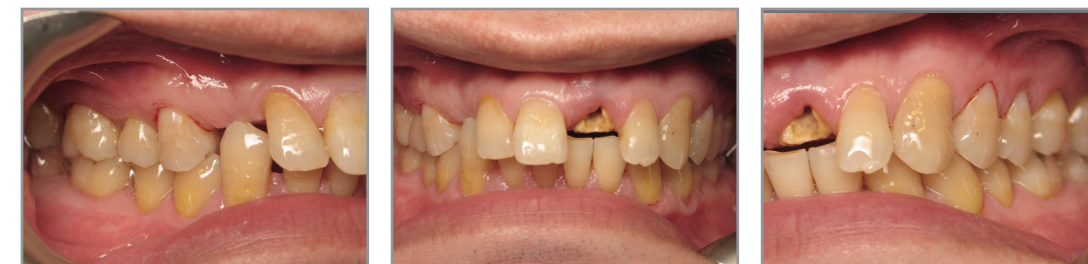Class I relationship with deep bite, missing upper right canine, and the lower right canine in contact with the palate. The upper left central incisor was fractured off at the gumline.

LENGTH OF TREATMENT 21 months

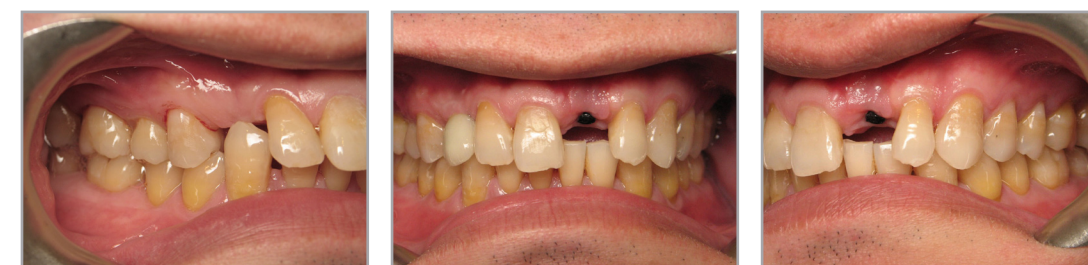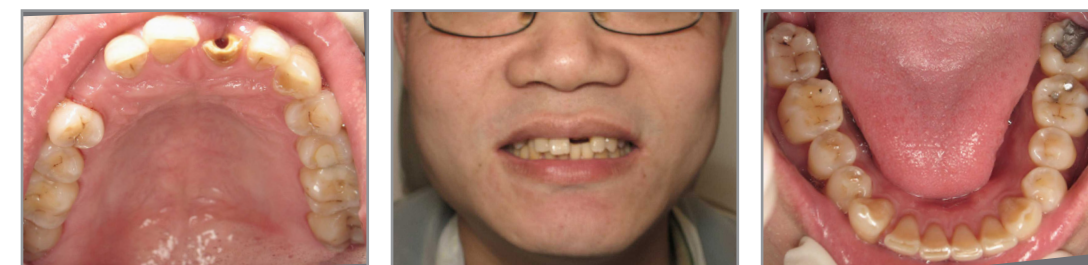OF ALIGNERS USED Upper: 17 + 10 + 10
Lower: 17 + 10 + 10

ADDITIONAL TREATMENT The lower right third molar was extracted prior to orthodontic treatment. Following Invisalign® treatment, an implant was placed in the area of the upper right canine. The upper left central was extracted, followed by placement of an immediate implant and bone graft. Final restorations were completed with implant crowns on the upper right canine and upper left central, and an onlay on the lower left second molar. Finally, enameloplasty was performed on the upper anteriors and the lower right canine.

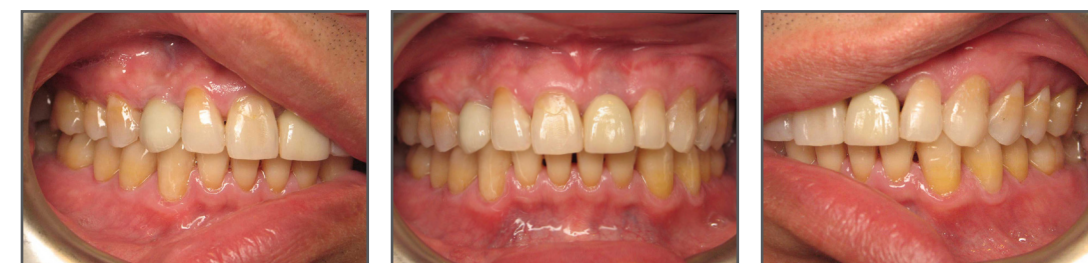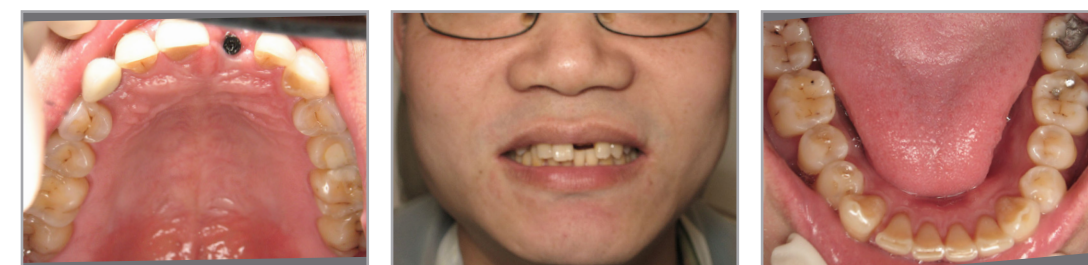RETENTION Upper: Vivera® retainer
Lower: Vivera® retainer



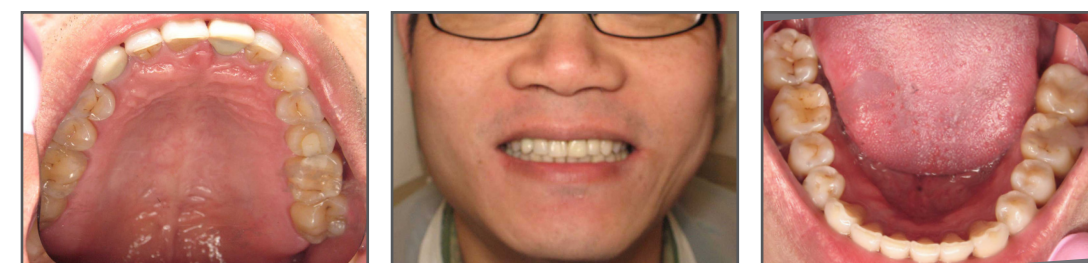BEFORE



PRE-RESTORATIVE



AFTER





Dr. Daniel Noor
Smile Café
New York, NY

www.SmileCafeNY.com

TREATMENT SUMMARY

PATIENT 27-year-old male

CHIEF CONCERN The patient was concerned about the appearance of his front teeth, his inability to bite, and also the cost of treatment.

DIAGNOSIS Right: Class I
Left: Class I

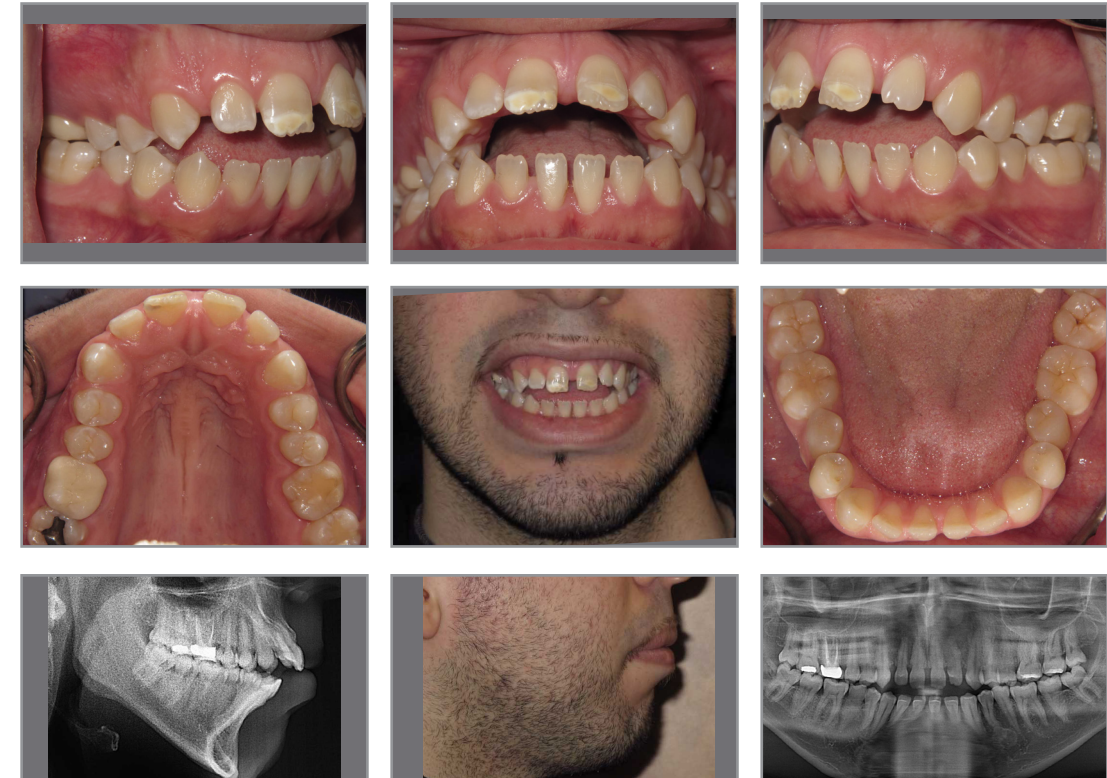Class I relationship with severe spacing (up to 8 mm), anterior open bite, 7 mm of overjet, protruded maxillary teeth, constricted upper arch, and tongue thrust habit.

LENGTH OF TREATMENT 20 months

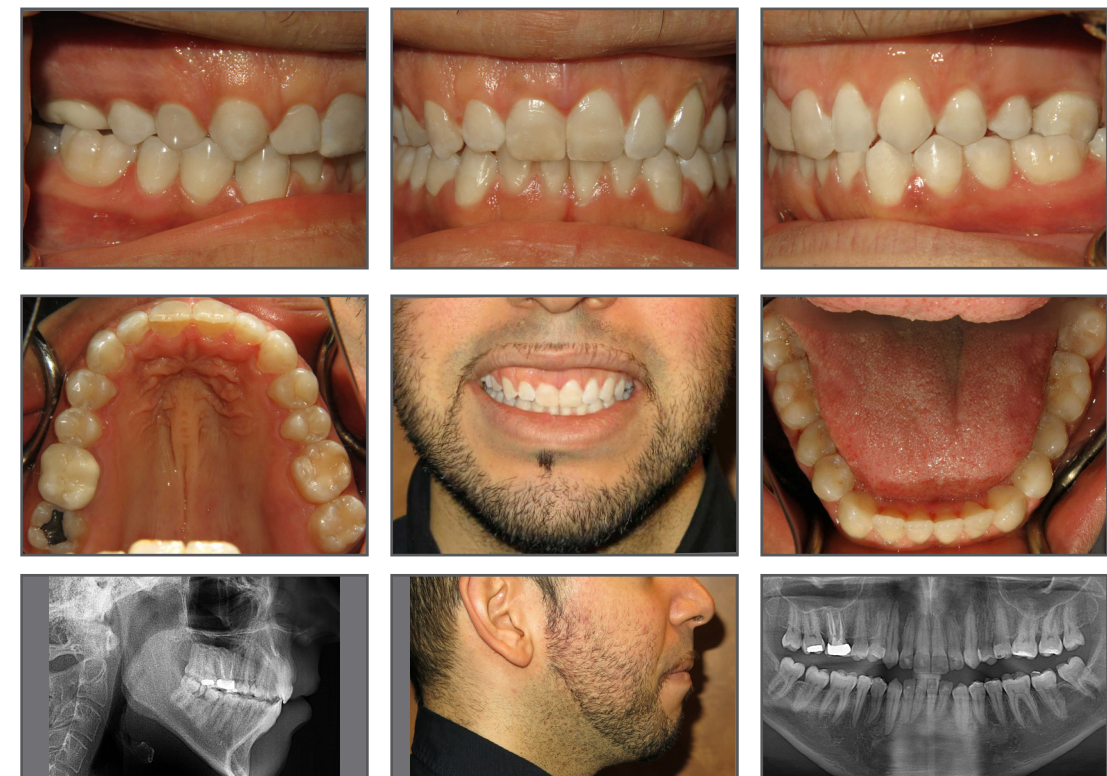
OF ALIGNERS USED Upper: 48
Lower: 48

ADDITIONAL TREATMENT All occlusal decay was restored prior to orthodontic treatment. Elastics were used to pull the canines into occlusion with buttons bonded to the teeth. Detailing pliers were used as needed. Following Invisalign® treatment, the teeth were whitened and the decalcified areas of the upper anterior teeth were restored with bonding and composite veneers.

RETENTION Upper: Other clear
Lower: Other clear



BEFORE



AFTER



Dr. Anthony Ramirez
Anthony Ramirez, DDS, MAGD
Brooklyn, NY

www.DrAnthonyRamirez.com

TREATMENT SUMMARY

PATIENT 51-year-old female

CHIEF CONCERN The patient was unhappy with her dental aesthetics, and the lower crowding made her teeth difficult to clean.

DIAGNOSIS Right: Class I
Left: Class I

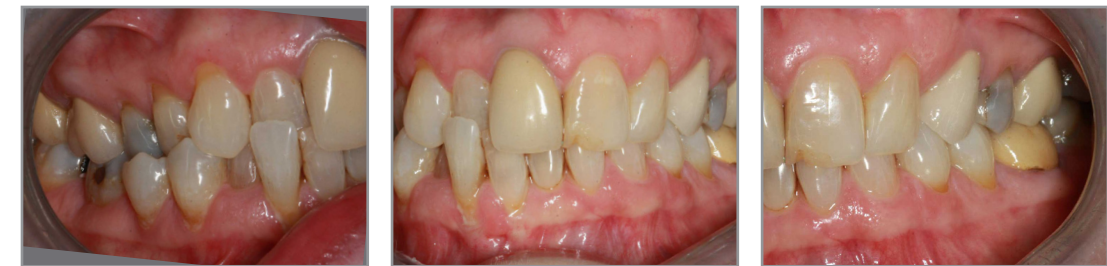Class I relationship with crowding in both arches and both anterior and posterior crossbites.

LENGTH OF TREATMENT 9 months

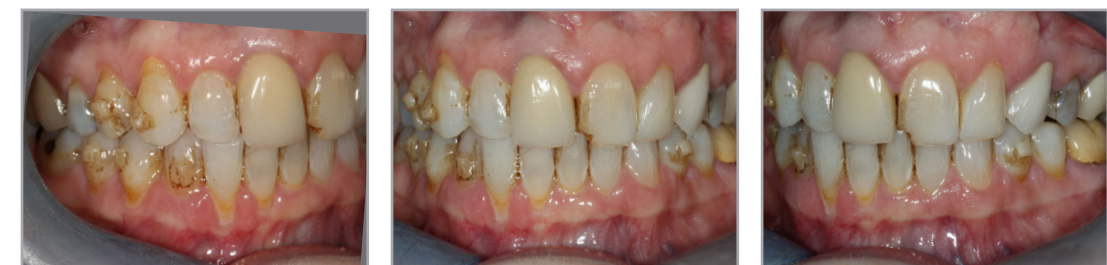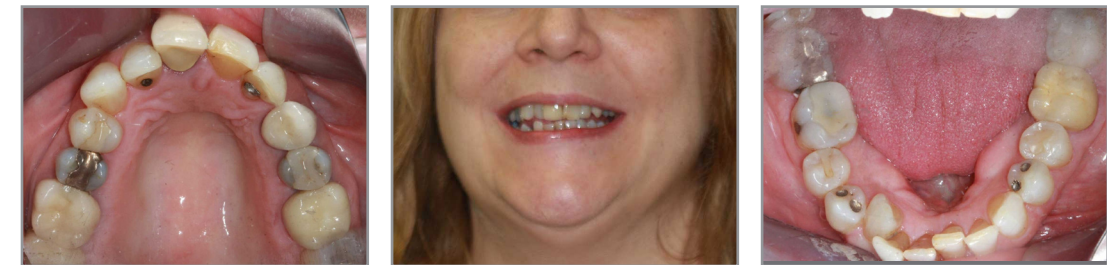OF ALIGNERS USED Upper: 22
Lower: 22

ADDITIONAL TREATMENT Following Invisalign® treatment, new crowns were completed on the upper right central incisor and the upper left second premolar, and a porcelain veneer was placed on the upper left central incisor.

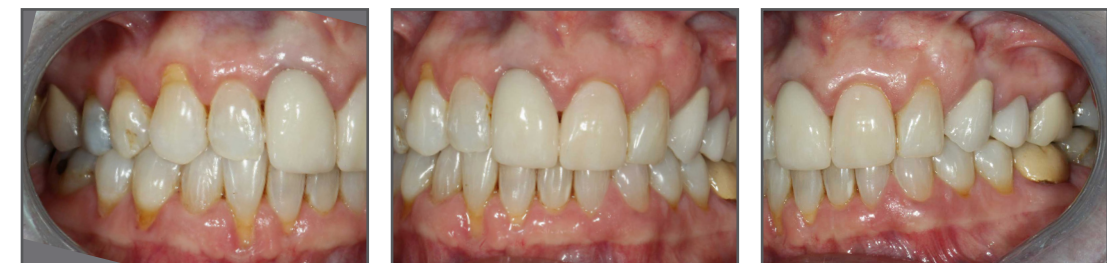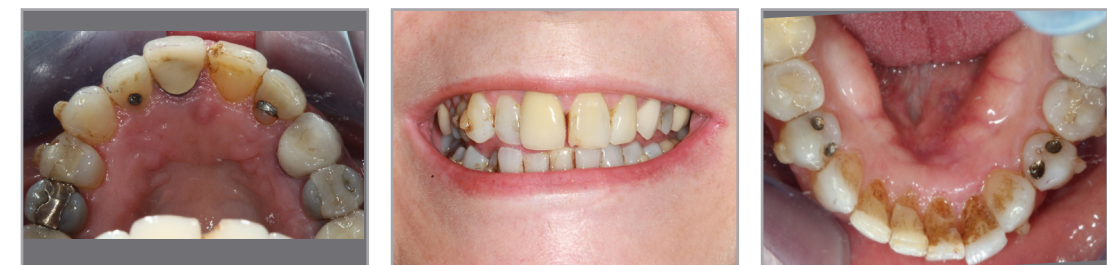RETENTION Upper: Other clear
Lower: Bonded lingual



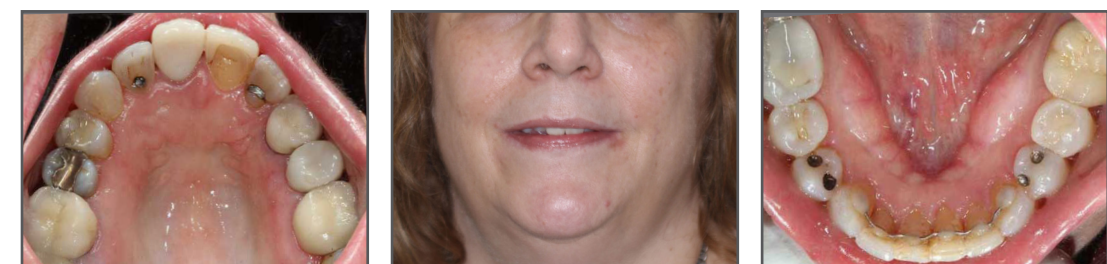BEFORE



PRE-RESTORATIVE



AFTER





Dr. Renae Roelofs
Personal Dental Care
North Chesterfield, VA

www.Dentist4yoursmile.com

TREATMENT SUMMARY

PATIENT 35-year-old male

CHIEF CONCERN The patient was in the public eye and desired a more aesthetic smile.

DIAGNOSIS Right: Class II
Left: Class I

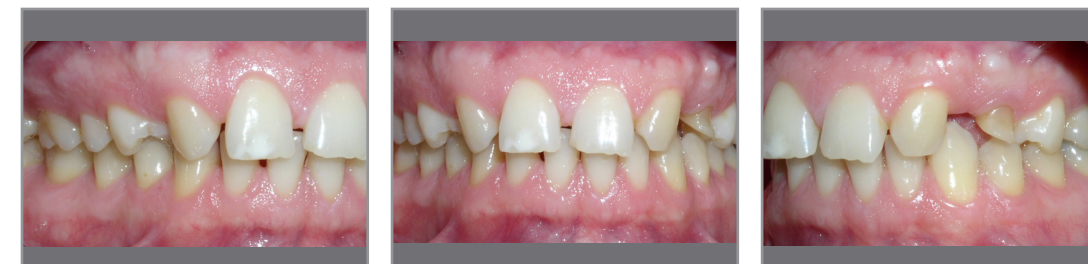Moderate maxillary spacing and deep bite, with lower incisors contacting the palate. The upper lateral incisors were missing.

LENGTH OF TREATMENT 13 months

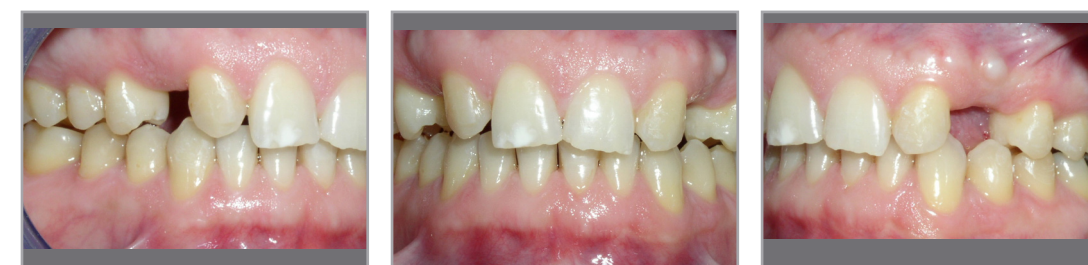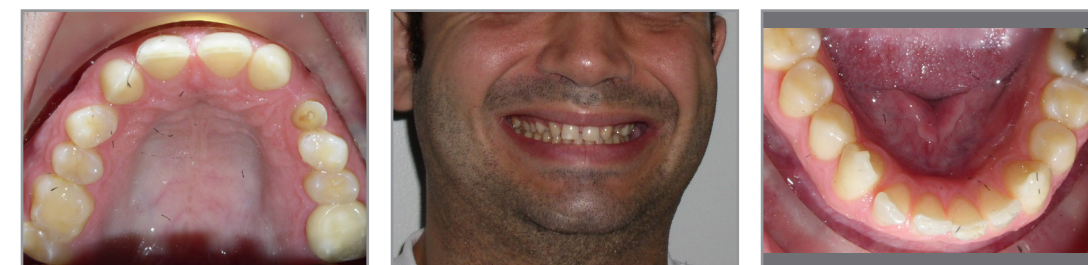OF ALIGNERS USED Upper: 21
Lower: 18

ADDITIONAL TREATMENT Two 3-unit fixed bridges were used to replace the missing upper teeth. Space was created by moving the canines mesially into the lateral incisor positions, reshaping the canines into laterals, and creating pontics to replace the canines. Porcelain veneers were placed on the upper central incisors. Prior to final placement of the restorations, gingivoplasty was performed to level the gingival height of the upper incisors and canines.

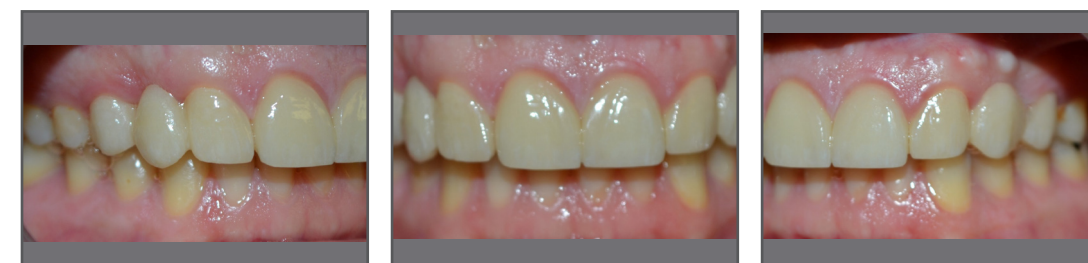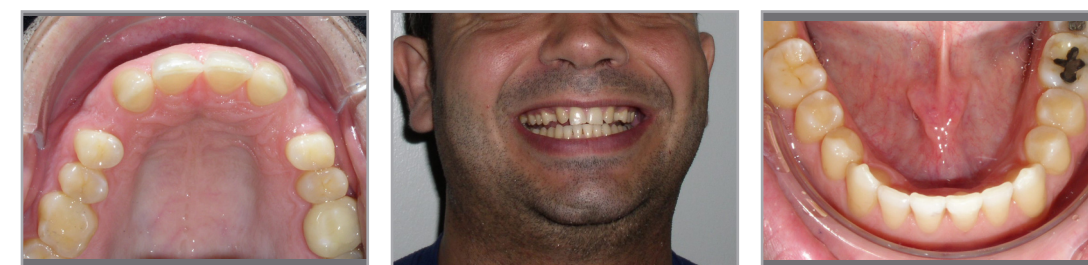
RETENTION Upper: Other clear
Lower: Bonded lingual



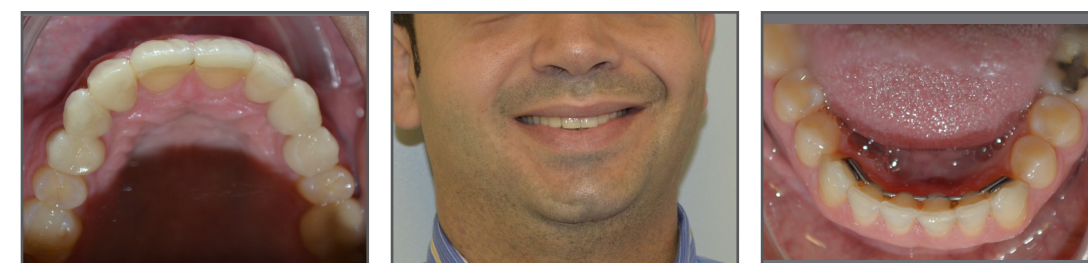
BEFORE



PRE-RESTORATIVE



AFTER





Dr. Nathalie Tungesvik
Diamond Ridge Dentistry
Jefferson City, MO

www.DrNathalie.com

TREATMENT SUMMARY

PATIENT 81-year-old female

CHIEF CONCERN The patient felt that her underbite was getting worse, and this created difficulty with function. Also, the lower partial denture no longer fit.

DIAGNOSIS Right: Class III
Left: Class III

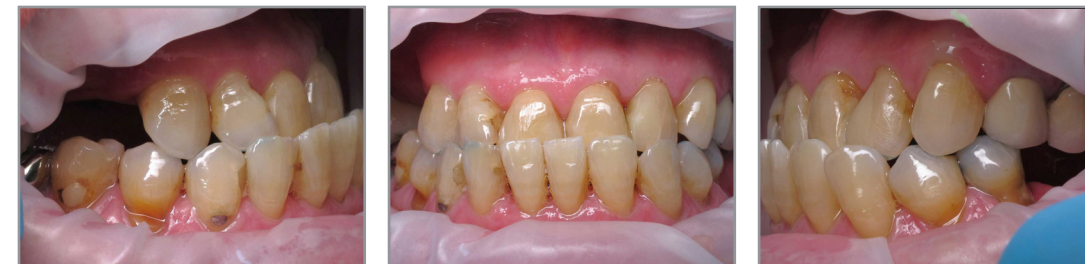Class III relationship with crowding and multiple missing teeth.

LENGTH OF TREATMENT 20 months

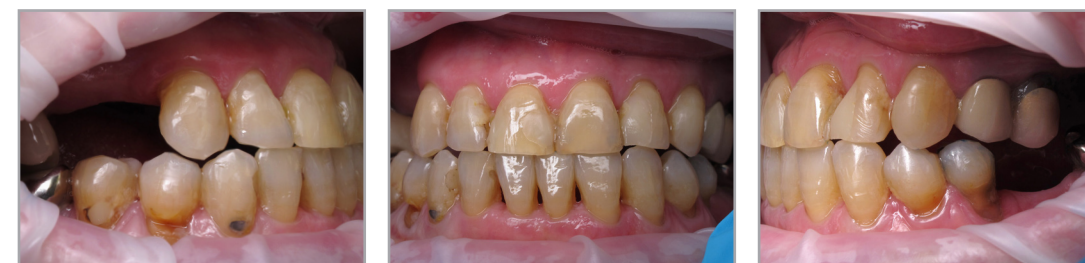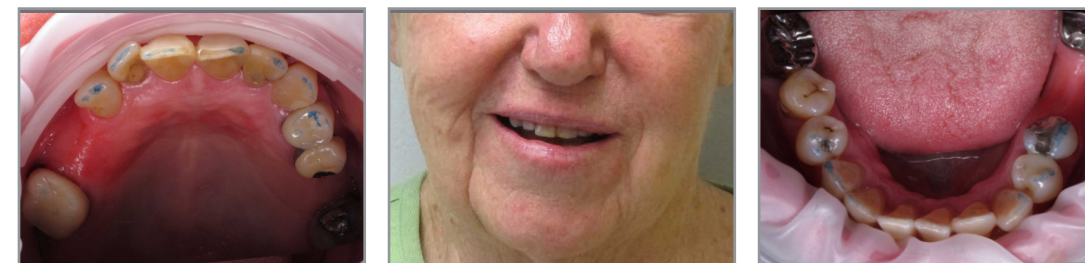OF ALIGNERS USED Upper: 11 + 11
Lower: 22 + 12

ADDITIONAL TREATMENT Following Invisalign® treatment, a crown was placed on the upper left second molar and a large composite filling was placed on the upper right lateral incisor. Also, the upper left second premolar and the lower left second premolar were extracted, and new partial dentures were fabricated.

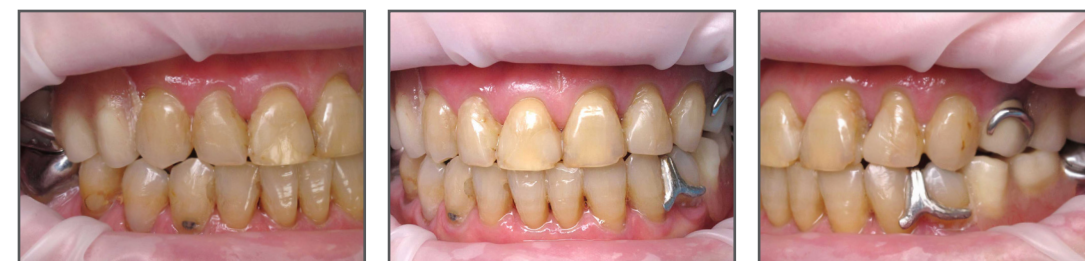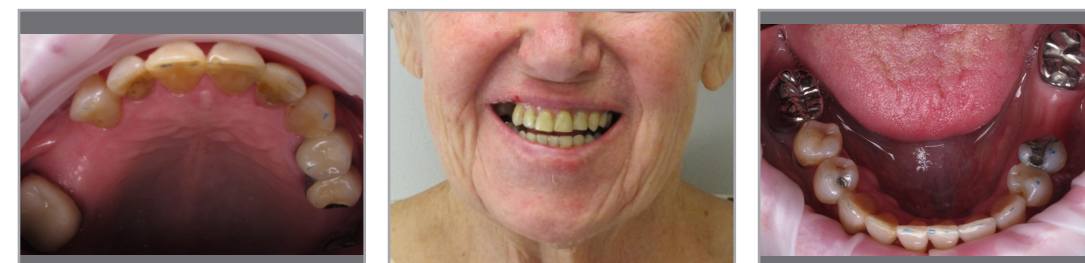RETENTION Upper: Other clear
Lower: Other clear



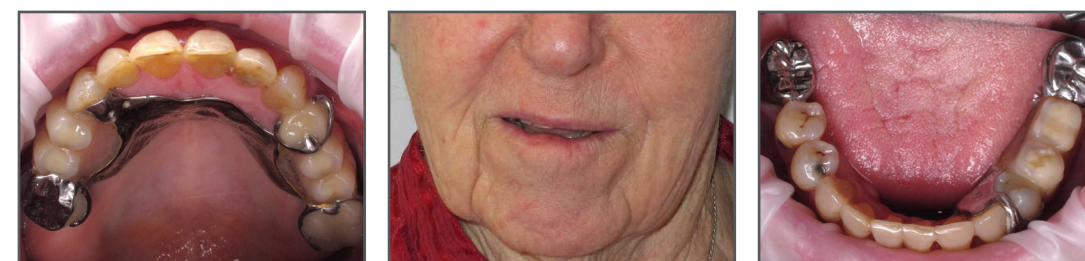BEFORE



PRE-RESTORATIVE



AFTER





Dr. Jack Von Bulow
Temple City Dental Care
Temple City, CA

www.TempleCityDental.com



TREATMENT SUMMARY

PATIENT 28-year-old female

CHIEF CONCERN The patient was concerned about the spaces created by her congenitally missing upper lateral incisors. She was also a trained vocalist, and was unable to pursue her career due to the appearance of her teeth.

DIAGNOSIS Right: Class I
Left: Class I

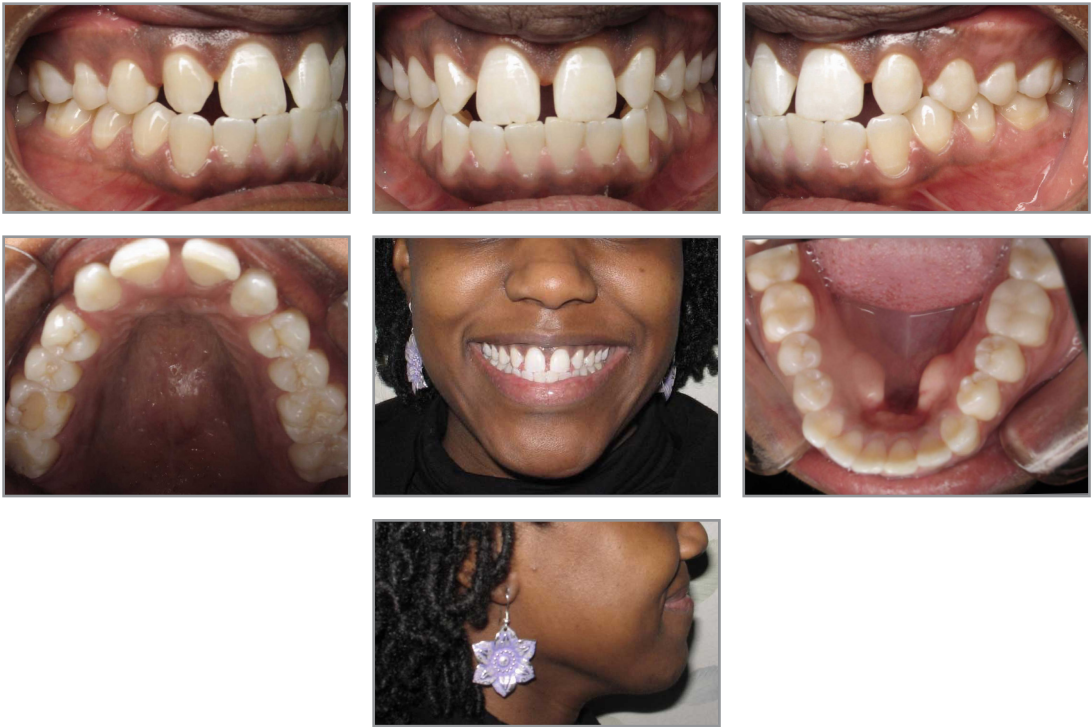Class I relationship with 9 mm of upper anterior spacing, anterior crossbite, and narrow arches.

LENGTH OF TREATMENT 27 months

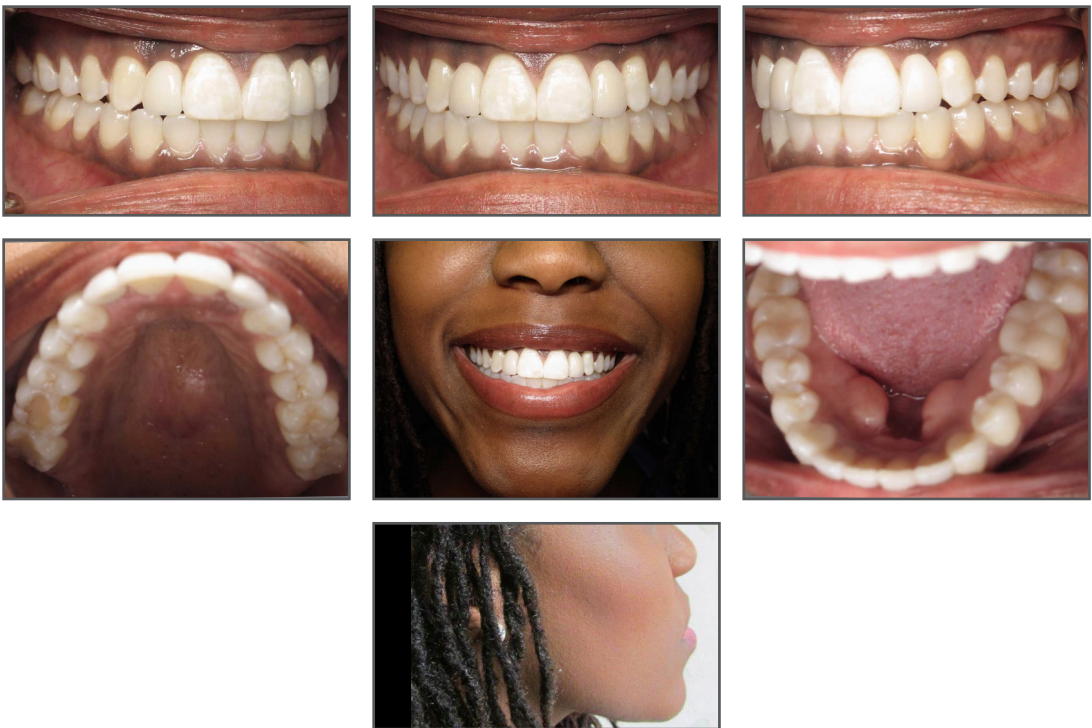OF ALIGNERS USED Upper: 15 + 10 + 10 + 8
Lower: 15 + 10 + 4 + 7

ADDITIONAL TREATMENT After closing the spaces between the upper first premolars and canines, and between the central incisors, implants and crowns were placed in the area of the missing lateral incisors.

RETENTION Upper: Viverra® retainer
Lower: Viverra® retainer



BEFORE



AFTER

ALPHABETICAL INDEX

TREATING DOCTOR

Dr. Keith Anderson 2

Dr. Rakesh Arya 4

Dr. Robert Asp..... 6, 8

Dr. Payam Ataii..... 76

Dr. San Bhatha 10

Dr. Ruby Bhullar..... 12

Dr. Edward Camacho..... 14, 16

Dr. Su-Wen Chang 18

Dr. Jasbir Cheema..... 20

Dr. Joseph Field 22, 96

Dr. Anthony Gadbois..... 24, 78

Dr. David Galler..... 26, 28, 30, 80, 98

Dr. Arne Gundersen 32

Dr. Mike Hinkle 34, 82

Dr. Eugene Kim..... 36

Dr. Jeremy Kurtz 38, 40

Dr. Xianglong Li..... 100

Dr. Yu Li..... 42, 44, 46, 84

Dr. Steven London..... 48, 50

Dr. Debbie Mulroy 52

Dr. Daniel Noor..... 54, 56, 58, 86, 102

Dr. Brian Orcutt..... 60

Dr. Bruno Paliani..... 62, 64

Dr. Patricia Primero 66

Dr. Kenneth Pyle 68

Dr. Anthony Ramirez 104

Dr. Stephane Reinhardt 70, 88

Dr. Renae Roelofs..... 106

Dr. John Rogers 72

Dr. Richard Schmidt..... 90

Dr. Jeffrey Tamucci 92

Dr. Nathalie Tungesvik 108

Dr. Jack Von Bulow 110

TEEN TREATMENT INDEX

TREATING DOCTOR

Dr. Rakesh Arya 4

Dr. Robert Asp..... 8

Dr. San Bhatha 10

Dr. Anthony Gadbois..... 78

Dr. Jeremy Kurtz 40

Dr. Bruno Paliani..... 62, 64

Dr. Stephane Reinhardt 70

TREATMENT PLAN INDEX

ACCELERATED ORTHODONTIC TREATMENT

Dr. Kenneth Pyle 68

ALIGNER TRAY SEATERS

Dr. Anthony Gadbois..... 78

COMPOSITE RESTORATIONS

Dr. Anthony Gadbois..... 78
Dr. Steven London..... 48
Dr. Bruno Paliani..... 64
Dr. Daniel Noor 102
Dr. Richard Schmidt..... 90
Dr. Nathalie Tunesvik 108

CROWNS/VENEERS

Dr. Robert Asp.....6
Dr. Joseph Field 96
Dr. David Galler..... 98
Dr. Mike Hinkle 82
Dr. Xianglong Li..... 100
Dr. Yu Li..... 84
Dr. Patricia Primero 66
Dr. Anthony Ramirez 104
Dr. Richard Schmidt..... 90
Dr. Nathalie Tunesvik 108
Dr. Jack Von Bulow 110

DENTURES

Dr. Richard Schmidt..... 90
Dr. Nathalie Tunesvik 108

DETAILING PLIERS

Dr. Daniel Noor 54, 56, 86, 102

DISTALIZING APPLIANCES

Dr. Stephane Reinhardt 70

ELASTICS

Dr. Robert Asp.....8
Dr. San Bhatha 10
Dr. Edward Camacho..... 16
Dr. Jasbir Cheema 20
Dr. Anthony Gadbois..... 24
Dr. Jeremy Kurtz 40
Dr. Daniel Noor 54, 56, 58, 102
Dr. Kenneth Pyle 68

ENAMELOPLASTY

Dr. Anthony Gadbois..... 78
Dr. Xianglong Li..... 100

EXTRACTIONS

Dr. David Galler..... 28
Dr. Xianglong Li..... 100
Dr. Stephane Reinhardt 88
Dr. Nathalie Tunesvik 108

GINGIVOPLASTY

Dr. Renae Roelofs..... 106

TREATMENT PLAN INDEX

IMPLANTS/BRIDGES

Dr. Joseph Field 96
Dr. David Galler..... 98
Dr. Xianglong Li..... 100
Dr. Yu Li..... 84
Dr. Renae Roelofs..... 106
Dr. Richard Schmidt..... 90
Dr. Jack Von Bulow 110

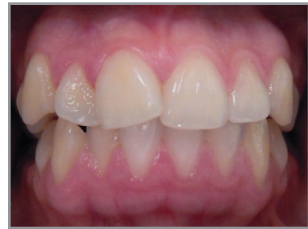ROOT CANAL THERAPY

Dr. Joseph Field 96
Dr. Mike Hinkle 82

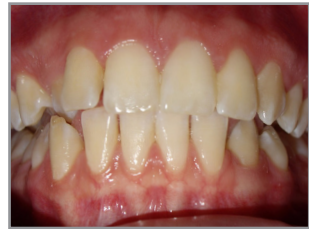SECTIONAL BRACES

Dr. Richard Schmidt..... 90

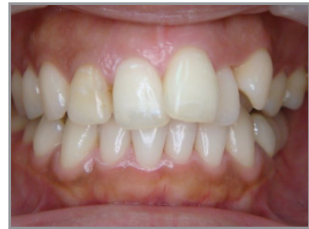VISUAL INDEX



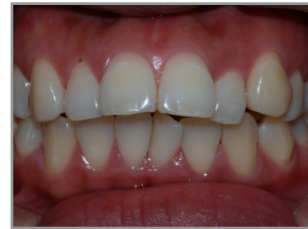Page 30



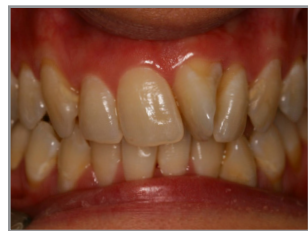Page 78



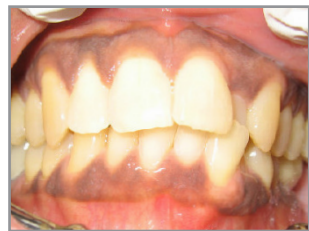Page 36



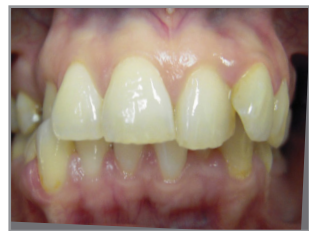Page 42



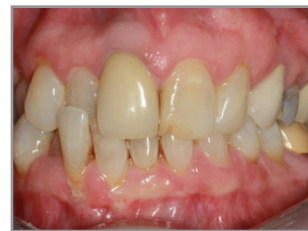Page 2



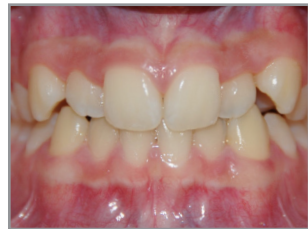Page 18



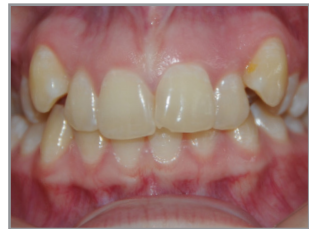Page 98



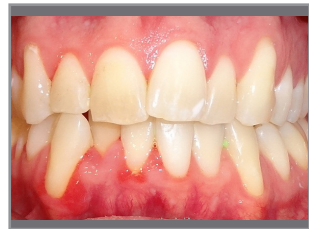Page 104



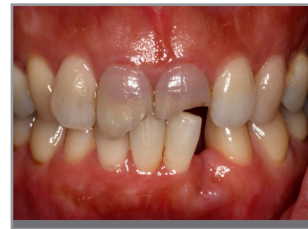Page 64



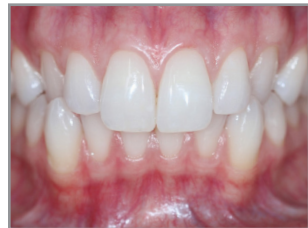Page 62



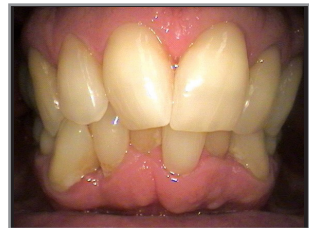Page 34



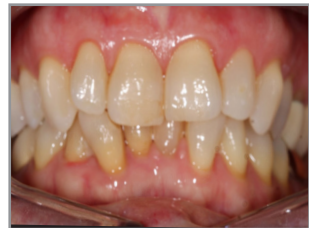Page 96



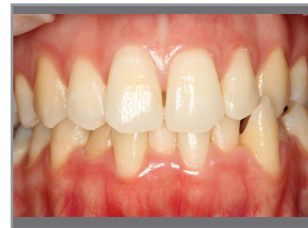Page 22



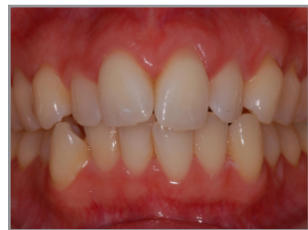Page 66



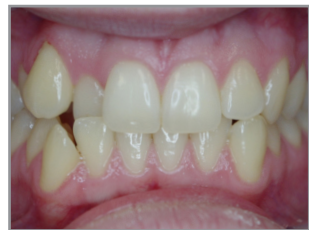Page 6



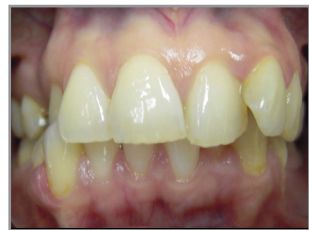Page 88



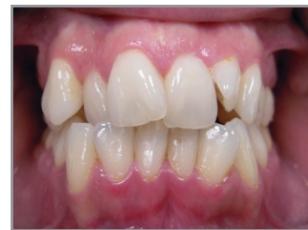Page 72



Page 4

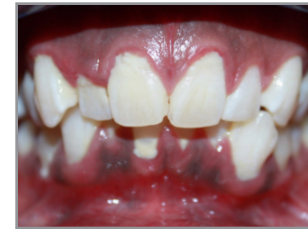

Page 98

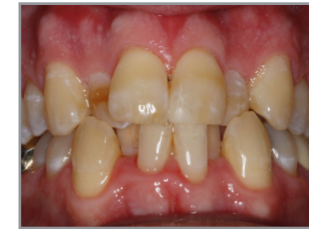

Page 26

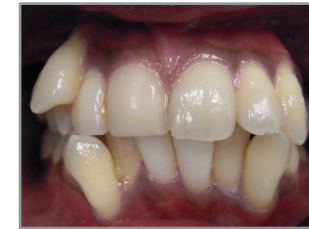VISUAL INDEX



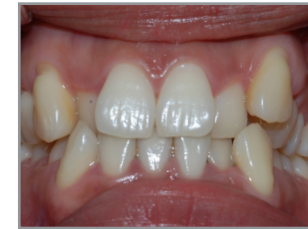Page 16



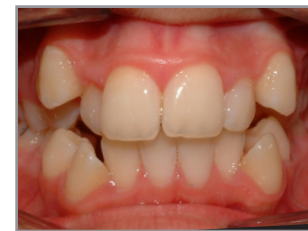Page 14



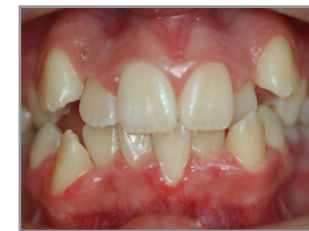Page 28



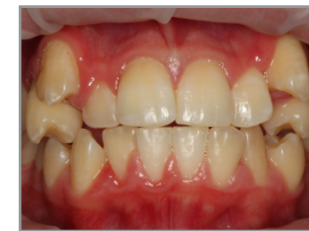Page 44



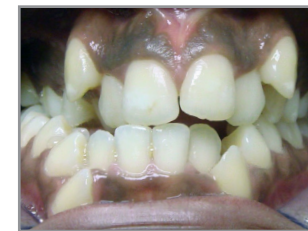Page 40



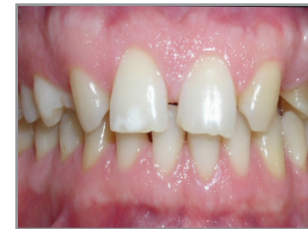Page 10



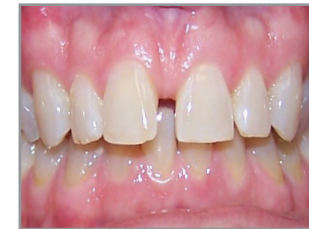Page 70



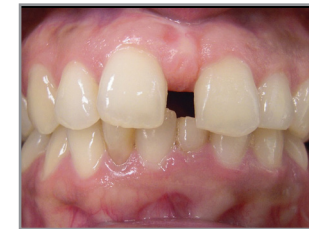Page 58



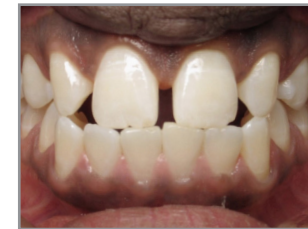Page 106



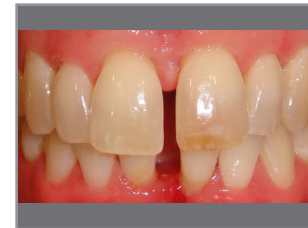Page 92



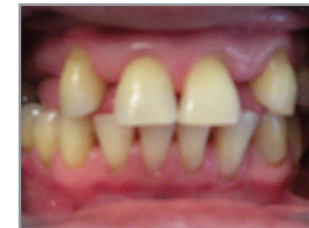Page 80



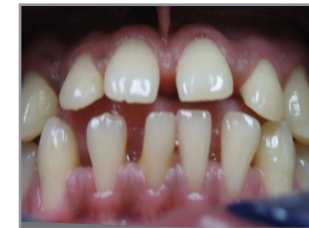Page 110



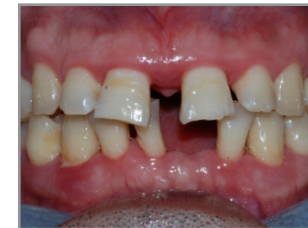Page 82



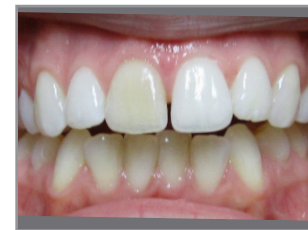Page 90



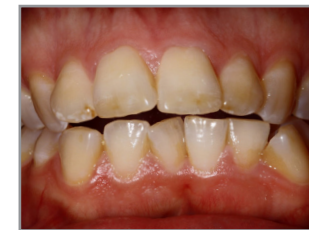Page 86



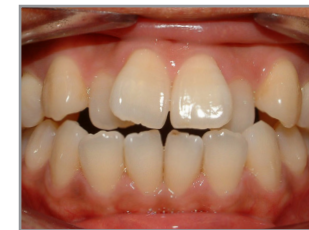Page 84



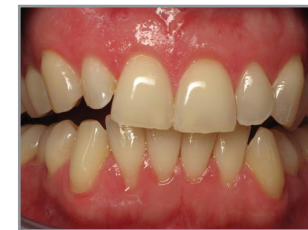Page 76



Page 60

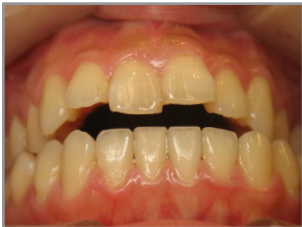

Page 38

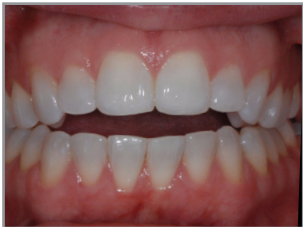

Page 12

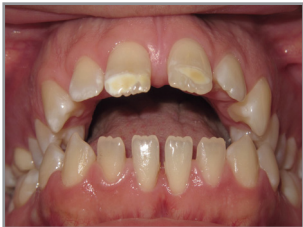VISUAL INDEX



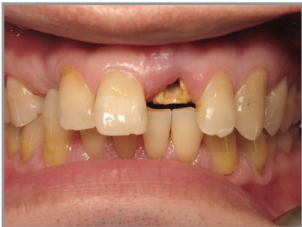Page 56



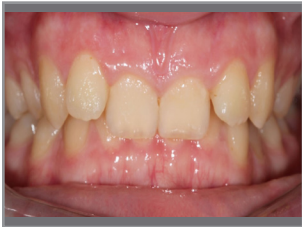Page 32



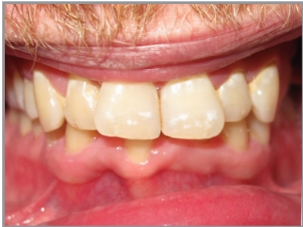Page 102



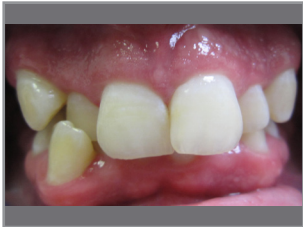Page 100



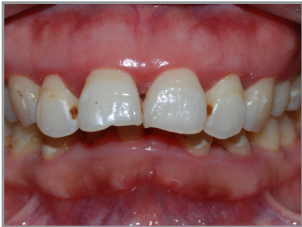Page 8



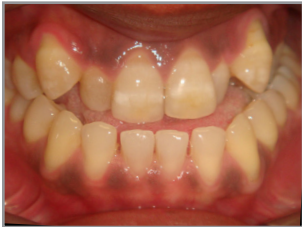Page 48



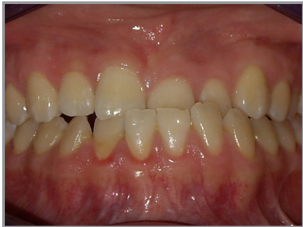Page 68



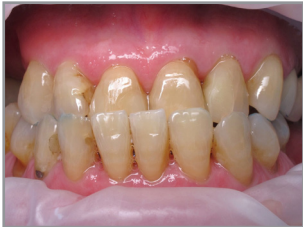Page 46



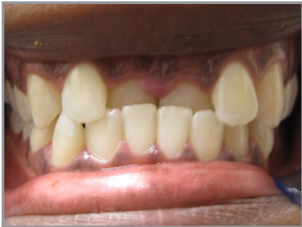Page 54



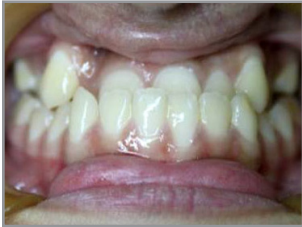Page 24



Page 50



Page 108



Page 20


2015 CLINICAL REVIEW COMMITTEE



DR. ROB ANDREW
[Private Practice, General Dentistry](#) – Edmonton, AB, Canada
[BChD](#) – University of Stellenbosch, South Africa
[Professional associations](#) – Canadian Dental Association, Alberta Dental Association, American Dental Association, International Association for Orthodontics



DR. MICHAEL BADGER
[Private Practice, General Dentistry](#) – Orlando, FL
[DDS](#) – Meharry Medical College School of Dentistry, Nashville, Tennessee
[Professional associations](#) – Fellow of Academy of General Dentistry, Diplomate of the International Congress of Oral Implantologists, Academy of General Dentistry



DR. T.J. DORSEY, II
[Private Practice, General Dentistry](#) – Ocoee, FL
[DDS](#) – Meharry Medical College School of Dentistry, Nashville, Tennessee
[Professional associations](#) – American Dental Association, Florida Dental Association, National Dental Association, American Academy of Facial Esthetics, Academy of General Dentistry



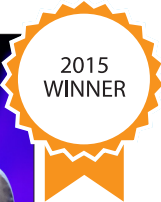DR. JOSEPH FIELD
[Private Practice, General Dentistry](#) – Los Altos, CA
[DDS](#) – University of Southern California School of Dentistry, Los Angeles, CA
[Professional associations](#) – Fellow of Academy of General Dentistry, Fellow of International Congress of Oral Implantologists, American Dental Association, California Dental Association



2015 SHOOTOUT AWARD RECIPIENTS

Invisalign® Summit
July 9-12, 2015
Aria Resort & Casino
Las Vegas, NV

[TOP BONUS TREATMENT](#)
Dr. Stephane Reinhardt
Brossard, QC, Canada
[www.CliniqueRTA.com](#)
Page 70



[TOP CROWDING TREATMENT](#)
Dr. Jasbir Cheema
Stockton, CA
[www.CheemaDental.com](#)
Page 20



[TOP SPACING TREATMENT](#)
Dr. Richard Schmidt
Brampton, ON, Canada
[www.DentistryAt8Nelson.com](#)
Page 90

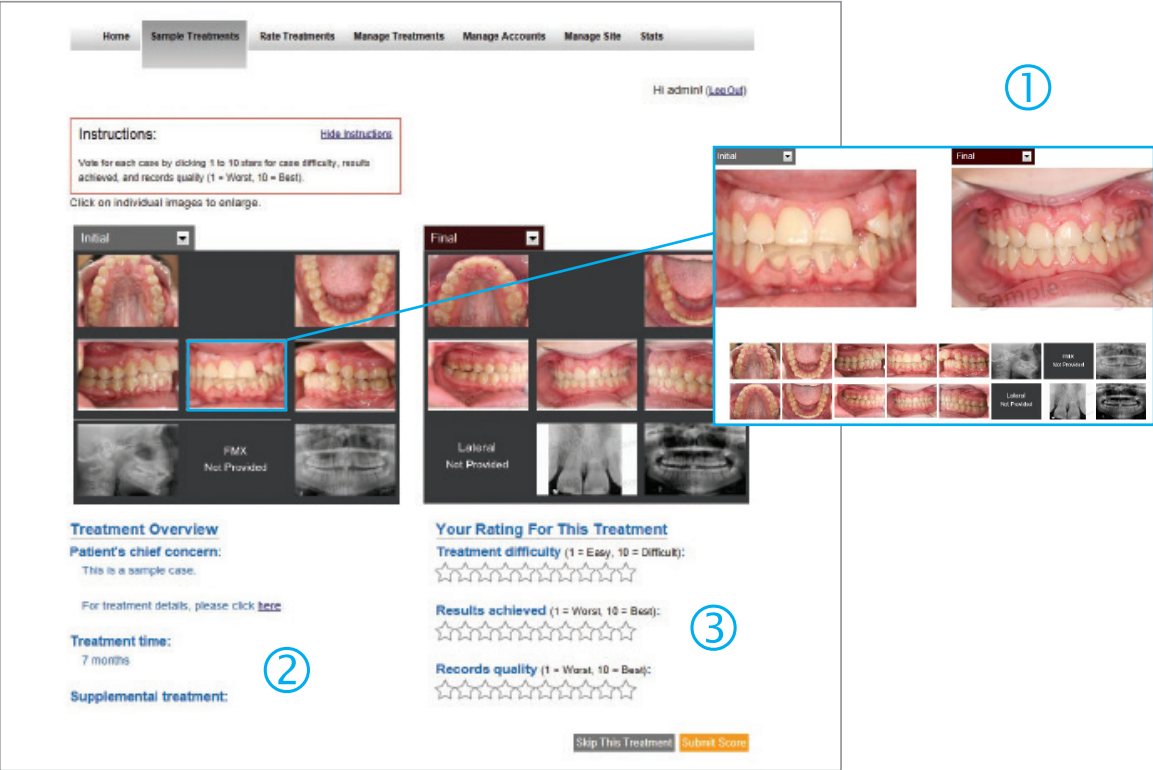


[TOP RESTORATIVE TREATMENT](#)
Dr. Jack Von Bulow
Temple City, CA
[www.TempleCityDental.com](#)
Page 110



METHODOLOGY

The top treatments of the 2015 Invisalign® Gallery were determined through double-blind online voting on a secure website developed by Align Technology, Inc. All records were displayed on the SmileScore.com website with any identifiers of the patient and treating doctor concealed. An optimization algorithm presented the treatments with the fewest votes collected first, so that the number of votes received per treatment was similar. All online voting was performed by general practitioners experienced with Invisalign® treatment. Doctors with cases entered into the competition were ineligible to vote.



1 Close-up and comparison views were displayed by clicking on the image of interest. With the exception of cropping and image orientation, all clinical images were displayed as originally submitted by the treating doctor. All images (including radiographs) were taken and provided at the sole discretion of the treating doctor.

2 The treatment overview section included the patient’s chief concern, the treatment time, and any auxiliaries used in conjunction with clear aligners (as reported by the treating doctor). Certain details about treatment such as the number of aligners used and the retention protocol were not displayed at the time of voting, but are reported in this publication.

METHODOLOGY

3 Doctors rated each case on a scale of 1 (worst) to 10 (best) based on three criteria and could only vote on each case once. To prevent selective voting, skipped cases could not be revisited. Skipped cases, however, were not counted towards the average composite score calculated.

INVISALIGN® GALLERY PROGRAM DETAILS

- Entries for publication consideration (177 total) were submitted by GPs covered by Align Technology’s North American Sales Team, and included submissions into the Invisalign® Summit Shootout, along with submissions for the Invisalign® Gallery publication only. Participants were able to enter one case per treatment category into the program (up to 4 cases total), with an additional "Other" category option.
- Each entry was screened by an independent Clinical Review Committee. Committee members were allowed to submit entries, but could not vote on their own case(s). All reviewers were blinded to the identities of both the treating doctor and the patient. The top 53 cases from the initial screening process are published here in the 2015 Invisalign® Gallery and advanced as semi-finalists to the online voting phase of the program.
- Invitations for online voting were sent via email to GPs experienced with Invisalign® treatment, who were not registered to attend the 2015 Invisalign® Summit nor were one of the participating entrants. Out of the 22,282 email invitations sent, 215 GP doctors chose to participate in the online voting process, with 3,050 votes received during a four-week voting window. All voting was voluntary, anonymous, and double-blind. Doctors who were semi-finalists were ineligible to vote.

- Treatments were presented on the voting website at random, with a distribution optimization algorithm used to ensure that a similar number of votes were received per treatment.
- The four Invisalign® Summit Shootout finalists were determined based on the highest average composite score received for the category, on a scale of 1.0 (worst) to 10.0 (best). Composite scores were calculated based on treatment difficulty (40%), results achieved (40%), and records quality (20%). The Summit Shootout winner was determined by attendees at the Invisalign® Summit continuing education event (July 9-12, 2015).
- Written patient and doctor consent (including parental consent where applicable) was received for all of the treatments presented in this book.
- Every effort was made to accurately represent the treatment details as reported by the treating doctor. The categorization of each submission was based solely on the treating doctor’s assessment of the patient’s condition. With the exception of cropping/orientation, background extensions to fit the layout, and some adjustments to color and contrast, all clinical images in this publication are presented as submitted.
- Doctors who provided optional study models in addition to their submitted photographs and radiographs were compensated in the amount of up to \$300 for the doctor and up to \$50 for the patient.
- For more information and full program details, please visit: global.invisaligngallery.com/summit.



2015 INVISALIGN® GALLERY TEAM

- PRODUCTION LAYOUT
Anna DeCicco
- RECORDS COLLECTION LEADS
Gali Froind
Sherri Wilson-Lopes
- DEVELOPMENT LEADS
Anna DeCicco
Eakta Malik
- GRAPHIC DESIGN/ARTWORK
Christopher Carter
- SOFTWARE DEVELOPMENT
Graham Westerlund
- PROJECT SUPPORT
Isaac Kang
Angelo Maniego
Sara Moghul
Preya Sheth
Veronica Vu
Eric Yau
- STATISTICAL VERIFICATION
Larry Lai, PhD
- SUMMIT EVENT COORDINATORS
Shannon Henderson
Kimberly Holmes
- REGULATORY/LEGAL COMPLIANCE
Karrie Anger
K Royal
- PHOTO EDITORS
Dr. Shirin Behdad
Dr. Eric Kuo
- EDITOR
Dr. Mitra Derakhshan

