Treating Anterior Malalignment with the Invisalign System and Enhancing Smile Aesthetics with Vital Bleaching, Edge Bonding and Facial Injectables

Dr Bharat Agrawal
BOralH (DentSci), GDipDentistry, MSc (Aesthetic Dentistry)

The male patient was 35 years of age at the time of first presentation. During a general dental check-up the patient expressed concern regarding the appearance of his teeth, in particular the lower incisor crowding, the prominence of his upper central incisors and the dyschromia present throughout his anterior dentition. The patient had not sought treatment previously due to concerns over the impact of conventional orthodontic devices, such as braces, on his social and professional engagements. He was also concerned that 'cosmetic' dental treatment, such as porcelain veneers, could result in an artificial appearance to his smile.

I. Intra- and extra-oral images before treatment

II. Panoramic radiograph before treatment

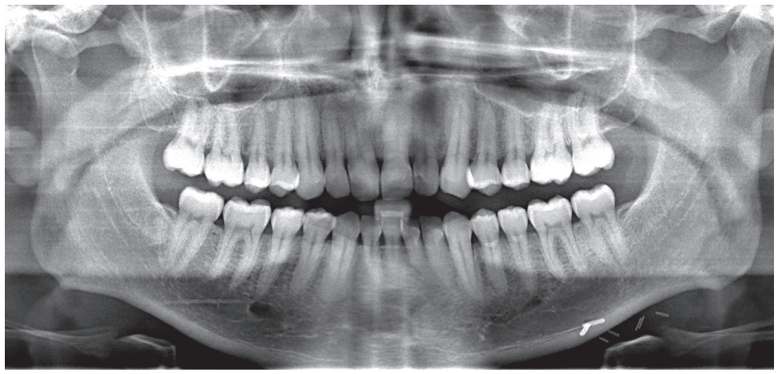

Clinical findings

Through clinical examination and evaluation of the patient's photographs, radiographs, digital models, digital smile analysis and smile design, several aesthetic failures were noted.

- Anterior dyschromia.
- Anterior malocclusion/malaligned teeth and crowding.
- Atypical incisal edge form due to asymmetric tooth wear.
- Central dominance due to barrel-shaped tooth form and atypical anteroposterior proportions.
- Excessive lower incisor display on the right-hand side of his face due to asymmetry of the lower lip.
- Exposure of cervical and root dentine due to gingival recession (Miller Class I).

III. Dental aesthetic assessment

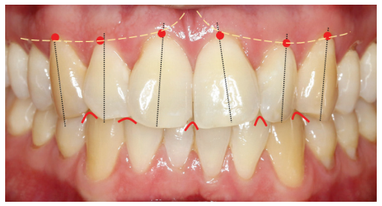

IV. Initial ClinCheck treatment plan

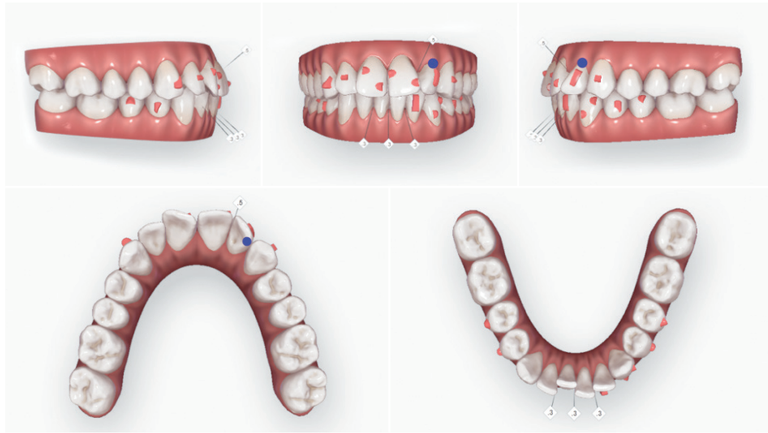

Treatment goals

- Decrease the anterior dyschromia.
- Correct the anterior malalignment and crowding.
- Improve the incisal embrasures.
- Improve the shape and proportions of the anterior teeth.
- Correct lip asymmetry.
- Increase gingival coverage.

Treatment approach

The patient first attended a basic maintenance and hygiene appointment to attain general dental health, after which treatment options for the identified aesthetic issues were evaluated. As all teeth tested vital and no active periodontal disease, carious lesions or identifiable radiographic issues were detected, the patient was deemed a suitable candidate for elective aesthetic dental treatment.

A comprehensive treatment plan that aimed to address the anterior malalignment and aesthetic shortcomings, through minimally invasive approaches, was decided upon. Treatment included several stages and techniques that comprised alignment of the teeth with Invisalign aligners, vital bleaching, additive composite bonding and correction of the lip asymmetry with botulinum toxin type A.

Stage 1: Alignment

Different methods for alignment of the anterior teeth were presented to the patient, including the use of conventional fixed orthodontic devices as well as treatment with clear aligners. Given his profession and social commitments, treatment with fixed braces was declined by the patient.

Since the patient's occlusion was largely functional and he presented with an ideal facial profile, correction of the molar relationship was considered unnecessary. The primary focus was therefore correction of the patient's anterior malalignment and treatment with the Invisalign System was recommended. Minimal interproximal reduction (IPR) was proposed to create space for resolution of the crowding and to minimise black triangle formation due to the irregular shape and position of the contact points. IPR was critical as it ensured that the required expansion of the dentitions was kept to a minimum, thereby preventing a worsening of the patient's existing gingival recession.

Importantly, prior to commencing treatment, the patient was advised of the necessity for post-alignment restorative treatment in order to correct discrepancies relating to incisal edge embrasures and tooth shape, which could be accentuated during alignment. The required level of post-alignment correction was determined prior to commencing treatment through evaluation of the ClinCheck treatment plan. The patient was also closely monitored and assessed during active alignment in order to accurately determine the anterior aesthetic discrepancies that would need correction (discussed in the following sections).

Initial treatment phase: Polyvinyl siloxane (PVS) impressions were taken for development of the ClinCheck treatment plan. Overcorrection of 10 degrees for the position of the upper central incisors was incorporated into the treatment plan to ensure correction of the malalignment. In terms of aligners, 20 upper and 21 lower aligners were determined to be required to correct the anterior malalignment. The patient was informed that refinement may be required following treatment with the initial set of aligners.

Attachments were bonded to the teeth and the active alignment subsequently commenced. The patient was advised to change aligners every 10 days and a printed schedule outlining this was provided to him. The patient was also provided with Chewies and instructed to utilise them for 5 minutes, three times per day. He was reviewed at 2 weeks and then every 30 days subsequently. During each visit, progress was assessed and correlated with the ClinCheck treatment plan to ensure that all teeth were tracking as anticipated.

Minimal IPR was conducted between the maxillary and mandibular incisors. IPR was conducted during the treatment phase and in accordance with the ClinCheck treatment plan.

Refinement phase: At aligner set 20, slight variation in the position of tooth 41 was observed. The teeth were scanned using the iTero Element scanner for development of the refinement ClinCheck treatment plan. An additional 10 sets of aligners were ordered to refine the occlusion. The refinement aligners were changed every 7 days.

This case report is intended for dental and healthcare professionals, and is subject to applicable local laws, regulations and guidelines.
INVISALIGN, CLINCHECK, and ITERO ELEMENT, among others, are trademarks and/or service marks of Align Technology, Inc. or one of its subsidiaries or affiliated companies and may be registered in the U.S. and/or other countries.

V. Extra-oral images prior to and following simultaneous vital bleaching

Stage 2: Simultaneous vital bleaching and alignment

Vital bleaching was commenced for the patient towards the end of the alignment period. As residual oxygen remains within the tooth for at least 2 weeks following the cessation of bleaching, the patient was warned that a degree of shade relapse can be expected within this timeframe. A decrease in bond strength between the composite and enamel immediately after bleaching was also kept in mind,[1] which in turn influenced the bonding protocol (discussed in the next section). Possible side effects of bleaching, such as increased tooth sensitivity and gingival irritation, were clearly explained to the patient prior to initiation.

The patient was issued with 6% hydrogen peroxide gel (PolaDay). He was instructed to place a small amount on the facial surface of each anterior tooth once daily, to be left in contact with the teeth for 45 minutes. Bleaching lasted for 14 days and a 14-day break was implemented prior to any restorative intervention.

Stage 3: Bonding and the completion of alignment

Completion of active alignment: Upon finishing refinement aligner set 10, the patient expressed satisfaction with the outcome and consented to the completion of active alignment. Alginate impressions were taken as final records and for the fabrication of fixed lingual retainer wires. During the fabrication process, the patient continued to wear the final refinement aligner as a form of retention.

An appointment was scheduled for composite bonding and for bonding of the lingual retainer wires. An advantage of the simultaneous bleaching protocol used in this case was the ability to progress to restorative treatment immediately following the completion of active alignment, while still providing enough time to prevent any impact on the resultant bond strength from bleaching.

Bonding: As mentioned, the importance of post-alignment restorative treatment to obtain harmonious incisal embrasures and tooth shape symmetry was relayed to the patient prior to commencing alignment. Predictions regarding the degree of post-alignment intervention were based on the ClinCheck treatment plan and also revaluated progressively during active alignment.

Options for correction of the anterior aesthetic discrepancies include selective odontoplasty, additive bonding and indirect restorations. The shortcomings associated with conventional prosthodontic options, such as indirectly fabricated ceramic restorations, were discussed with the patient at length, as well as the need for aggressive tooth preparation, particularly of the central incisor teeth. The advantages of additive composite resin bonding in terms of the lower biologic consequences and higher cost-effectiveness in comparison to indirect restorations, as well as easier reparability, were relayed to the patient. It was stressed, however, that composite resin additions require more maintenance, with periodic polishing of the surfaces.

Following review of the treatment options, additive bonding to teeth 11, 12 and 31 using composite resin was decided upon. Composite resin (Estelite Asteria, Tokuyama Dental) of shade A1 Body and white enamel were stratified in exacting increments and manipulated using a modelling brush prior to photopolymerisation. The final restorations were contoured and polished to achieve a result harmonious with the surrounding natural dentition.

VI. Isolation of the operative field for bonding (left image) and composite resin additions prior to final polishing (right image)

VII. Extra-oral image following final polishing of the composite resin additions

VIII. Extra-oral images prior to (left image) and following (right image) correction of the lip asymmetry

> An advantage of the simultaneous bleaching protocol used in this case was the ability to progress to restorative treatment immediately following the completion of active alignment, while still providing enough time to prevent any impact on the resultant bond strength from bleaching.

Retention: The upper and lower lingual retention wires were bonded using heated Estelite Sigma A1 composite (Tokuyama Dental) with the assistance of a PVS positioning jig. The composite attachments were removed and tooth surfaces polished. Upper and lower alginate impressions were again taken for fabrication of vacuum-formed removable retainers for night-time wear. Retention with the removable retainers is currently ongoing for the patient.

Stage 4: Correction of lip asymmetry

The depressor anguli oris (DAO) muscle is involved primarily in lowering the commissure of the mouth and is associated with frowning. Although difficult to objectively confirm that an overactive DAO muscle on the right-hand side was responsible for the patient's lower lip asymmetry, the use of botulinum toxin type A was recommended utilising a single injection site. Given that the antagonist muscles of the DAO are primarily the levator anguli oris and the zygomaticus major and minor muscles, it was postulated that by relaxing the DAO muscle on the right-hand side, the overall effect would promote elevation of the lip. The technique was deemed safe and although results were not guaranteed, the patient understood that eventual degradation of the molecule from the area of injection would result in a reversal of the effect, should it be ineffective. Dysport (abobotulinumtoxinA) was reconstituted with 0.9% sterile saline prior to use and 2.5 units subsequently injected at a single site into the DAO muscle on the right-hand side of the face, with the needle penetrating deep into the muscle. Post-operative instructions were provided to the patient, who was reviewed 2 weeks following the procedure to assess treatment outcomes.

The patient's gingival recession was primarily due to a traumatic tooth brushing technique; thus, in-depth oral hygiene instruction in relation to proper brushing technique was provided. Options for correction of the patient's gingival recession using either a pedicle soft tissue graft or free soft tissue graft were considered. Given that the recession is classified as Miller Class I, a good prognosis with full coverage of recession defects is anticipated.

Treatment details

Active treatment time

- 11 months.

Aligners used

- 20 + 10 upper aligners.
- 20 + 10 lower aligners.

Attachments

Initial treatment phase

- Optimised Rotation Attachments on teeth 13, 34 and 44.
- Optimised Root Control Attachments on teeth 11, 21, 33 and 35.
- Optimised Extrusion Attachments on teeth 12 and 33.
- Optimised Deep Bite Attachment on tooth 45.
- Conventional long vertical attachments (5 mm) on teeth 22 and 32.

Refinement phase

- Optimised Rotation Attachment on tooth 13.
- Optimised Root Control Attachments on teeth 23 and 24.
- Conventional long vertical attachment (5 mm) on tooth 21.

Retention

- Upper V-Loop fixed wire and lower straight fixed wire.
- Upper and lower vacuum-formed retainers for night-time wear.

Treatment outcome

The patient adapted well to aligner wear, was highly motivated and did not complain of any major adverse effects during treatment, only mentioning minor discomfort when changing to new aligners. At the completion of treatment

This case report is intended for dental and healthcare professionals, and is subject to applicable local laws, regulations and guidelines.
INVISALIGN, CLINCHECK, and ITERO ELEMENT, among others, are trademarks and/or service marks of Align Technology, Inc. or one of its subsidiaries or affiliated companies and may be registered in the U.S. and/or other countries.

IX. Intra- and extra-oral images after treatment

X. Panoramic radiograph after treatment

there was significant improvement in the overall smile aesthetics, with the patient expressing satisfaction with the treatment results.

The whitening effect of vital bleaching was significant, with a drastic improvement in shade (the final shade was approximately B1; VITA Classical shade guide), and there was a noticeable reduction in the chromacity of the canines to match the rest of the dentition. It is important to note that shade relapse over time is to be anticipated and this may result in a mismatch between the teeth and composite resin additions. To address this, bleaching trays have been fabricated for the patient to be utilised as 'top-up' treatment in the future should a mismatch in colour occur. The intramuscular injection with Dysport achieved the desired outcome of improving lip symmetry.

It is important to note that shade relapse over time is to be anticipated and this may result in a mismatch between the teeth and composite resin additions. To address this, bleaching trays have been fabricated for the patient to be utilised as 'top-up' treatment in the future should a mismatch in colour occur.

The patient has now been referred to a specialist periodontist to complete gingival grafting procedures to address the gingival recession.

Clinical tips

- Assessment: Assessment of the patient's tooth form and shape is critical, regardless of whether this is through visual assessment or objective digital evaluation. Several methods can be used.
  - Utilising digital smile design alongside simulations from the ClinCheck software can help assess morphological discrepancies prior to starting the alignment phase of treatment. This aids in patient comprehension of any possible biologic consequences of certain procedures, limiting any surprises or dissatisfaction should teeth alignment alone not meet their aesthetic expectations due to pre-existing morphological shortcomings.
  - Direct chairside mock-ups using composite resin can also be utilised to assist the patient in visualising morphological discrepancies and are particularly useful towards the end of the alignment phase of treatment.
  - Photographs should be taken of any diagnostic additions and clinicians should endeavour to utilise them as a template for their final restorations, or to relay information to their lab technician if a wax-up is being fabricated.
  - Where significant restorative corrections are required, either stone or digital models can be utilised to create a wax-up, which can be used to create silicone keys to assist clinicians with composite stratification.
- Dentofacial aesthetic assessment is critical given the influence facial aesthetics may have on smile aesthetics. As demonstrated in this case, botulinum toxin type A injections can be used to enhance the treatment results achieved from alignment alone.
- Simultaneous bleaching that is sequenced appropriately can enable restorative treatment to be performed immediately upon completion of alignment. It is important to ensure that there is at least 10–14 days between the completion of active bleaching and any bonding procedures to ensure bond strengths are not adversely affected.
- In this case, there was an adequate colour match between the composite resin additions and the patient's natural teeth. This was from meticulous stratification, which in addition to advances in modern composites, often negate the need for a bevel or tooth removal.

XI. Extra-oral lateral images prior to (left image) and following (right image) treatment

Impact on clinical practice

The patient was able to undergo treatment at a significantly lower biologic and financial cost compared with conventional prosthodontic treatment options, while significant improvements in dental and dentofacial aesthetics were achieved. Additionally, treatment was completed in a minimally invasive manner, with only minimal dental hard tissue being compromised. IPR was the only source of hard tissue loss.

The patient felt that the treatment choice addressed his chief complaints, whilst being discreet enough to not affect his lifestyle or interfere with his busy work schedule. Interestingly, treatment with the Invisalign System has recently been shown to cause less discomfort in adults than fixed orthodontics due to the use of intermittent forces.[2]

Conclusion

This case demonstrates that patients who seek improvement in the aesthetics of their smile due to dental malocclusion can benefit significantly from treatment with the Invisalign System in combination with other minimally invasive aesthetic modalities, such as bleaching, additive bonding and the use of facial injectables.

Author disclosure

Dr Bharat Agrawal was provided an honorarium from Align Technology, Inc., for his contribution towards the creation of this case report.

Dr Bharat Agrawal

Bharat Agrawal completed a Bachelor of Oral Health in Dental Science and Graduate Diploma of Dentistry at Griffith University, Australia. He also obtained a Masters in Aesthetic Dentistry with Distinction from King's College London. Dr Agrawal currently works in private practice and is a partner at the Oasis Dental Studio in Queensland, Australia, which specialises in providing general and aesthetic dentistry.

Dr Agrawal presented at the 2017 AesthetiCon meeting of the Australasian Academy of Dento-Facial Aesthetics in Sydney on the topic of tooth whitening. He also presented on orthodontic-restorative considerations at the 2017 Aesthetic & Restorative Masterclass at King's College London. Dr Agrawal is a key opinion leader with Invisalign Australia and in 2017 he was awarded the Platinum Invisalign Provider status.

References

1. Della Bona A, Baghi N, Berry TG, *et al.* In-vitro bond strength testing of bleached dentine. *Journal of Dental Research* 1992;71:659. Abstract 1154;
2. White DW, Julien KC, Jacob H, *et al.* Discomfort associated with Invisalign and traditional brackets: A randomized, prospective trial. *The Angle Orthodontist* 2017;87:801–8.

This case report is intended for dental and healthcare professionals, and is subject to applicable local laws, regulations and guidelines.
INVISALIGN, CLINCHECK, and ITERO ELEMENT, among others, are trademarks and/or service marks of Align Technology, Inc. or one of its subsidiaries or affiliated companies and may be registered in the U.S. and/or other countries.

This case demonstrates that patients who seek improvement in the aesthetics of their smile due to dental malocclusion can benefit significantly from treatment with the Invisalign System in combination with other minimally invasive aesthetic modalities, such as bleaching, additive bonding and the use of facial injectables.